الجمهورية التونسية
République Tunisienne
وزارة الصحة
Ministère de la Santé

الجمعية التونسية لجراحة الجهاز العصبي
ASSOCIATION TUNISIENNE DE NEUROCHIRURGIE

Pan Arab Neurosurgical Society
الجمعية العربية لجراحة الأعصاب

15th PANARAB NEUROSURGICAL SOCIETY CONFERENCE

39th Congress of the Tunisian Association of Neurosurgery

November 6th – 8th 2026

Russelior Hotel - Yasmine Hammamet - TUNISIA



CONGRESS WELCOME

Welcome Message



Prof. Mehdi Darmoul
Congress President
President-Elect, Pan Arab Neurosurgical Society

Dear Colleagues and Friends,

On behalf of the Tunisian Association of Neurosurgery, it gives me immense pleasure to welcome you all to the 15th Pan Arab Neurosurgical Society Meeting, which will be held from November 6 to 8, 2026, at the Russelior Hotel in Hammamet, Tunisia.

There will be a three-day scientific programme that promises to provide a platform for insightful discussions and research presentations. It will also be a valuable opportunity to reconnect, exchange ideas, and foster collaborations within our community.

We are delighted to welcome our guests from all Arab countries and from around the world, and we open our hands and hearts to everyone joining us for this exceptional event.

The Organizing Committee is working hard to ensure a memorable and successful scientific event.

We look forward to welcoming you all in Hammamet.

Sincerely,

OFFICIAL INVITATION

Invitation to the 15th Pan Arab Neurosurgical Society Meeting



Prof. Ahmed Alkhani
President
Pan Arab Neurosurgical Society

Dear Colleagues and Friends,

On behalf of the Pan Arab Neurosurgical Society, it is my great honor and pleasure to invite you to the 15th Pan Arab Neurosurgical Society Meeting, which will be organized by the Tunisian Association of Neurosurgery under the leadership of Prof. Mehdi Darmoul. The meeting will be held in Hammamet, Tunisia, from November 6–8, 2026.

We are delighted to be returning to our regular Pan Arab Neurosurgical Society meeting, and we look forward to welcoming you all to what promises to be a fantastic event.

Our Scientific and Organizing Committees are preparing a superb scientific program designed to foster the exchange of knowledge, experience, and innovation.

This gathering is a unique opportunity for us to come together, share information, and build lasting bridges that will advance neurosurgical care for our patients across the Pan Arab region.

We sincerely hope you will join us for this important milestone in the life of our Society. Your presence and contribution will be invaluable to the success of the meeting.

With warm regards and in anticipation of welcoming you to Hammamet.

MESSAGE FROM THE PRESIDENT
OF THE TUNISIAN ASSOCIATION OF NEUROSURGERY

Welcome to Tunisia, Welcome Home



Prof. Imed Ben Said
President
Tunisian Association of Neurosurgery

My Dear Colleagues and Friends,

From the bottom of my heart, welcome to Tunisia. Welcoming you all to the Pan Arab Neurosurgery Congress 2026 is a profound honor, not just for me, but for our entire community.

This year feels entirely different. For us in Tunisia, this gathering isn't just another conference—it marks the dawn of a brand-new era in our field. We are standing on the shoulders of the pioneers who built our past, but today, we are stepping into a future bursting with fresh energy, incredible innovation, and a brilliant new generation of young surgeons ready to lead.

> *As we prepare to explore cutting-edge science and technology, let us remember the core of what we do : it is our shared humanity that truly heals.*

Beyond the lecture halls, I want you to feel the genuine warmth of Tunisian hospitality. Our time together will be about connection. Share your ideas, challenge one another, and catch up with old friends.

Thank you for being part of this historic milestone with us. Welcome to Tunisia, and welcome home.

Warmly,

PAN ARAB NEUROSURGICAL SOCIETY BOARD

PRESIDENT
Prof. Ahmed Alkhani Saudi Arabia

PRESIDENT-ELECT
Prof. Mehdi Darmoul Tunisia

PAST PRESIDENT
Prof. Ali Almashani

HISTORIAN
Prof. Bin Eissa Abdennebi

GENERAL SECRETARY
Prof. Abdulrahman Alshudifat Jordan

HEAD, TRAINING COMMITTEE
Prof. Abdulghafar Kiwan Syria

TREASURER
Prof. Lakhdar Guenane Algeria

HEAD OF CENTRAL OFFICE
Prof. Hossam El Huseiny Egypt

MEMBER
Prof. Bachir Bellebna Algeria

PANS JOURNAL, EDITOR-IN-CHIEF
Prof. Nasser El-Ghandour Egypt

PAST PRESIDENTS

Prof. Sherif Ezzat	Prof. Antoine Nachanakian	Prof. Abdeslam El Khamlichi
Prof. Ibrahim Sbieh	Prof. Moh. Hasan Qatramiz	Prof. Mohamad Joharji
Prof. Bin Eissa Abdennebi	Prof. Yousef Al Awadi	Prof. Amro Alshawarbi
Prof. Hussam Al-Hussaini	Prof. Najia El Abbadi	Prof. Ali Almashani

LEADERSHIP



Pr Mehdi Darmoul
Congress President



Dr Mohamed Ladib
Congress Coordinator



Dr Abdelhafidh Slimane
Organizing Committee Chair



Dr Fatma Kolsi
Scientific Committee Chair



Dr Mohamed Maher Hadhri
Panarab Congress Website manager

ORGANIZING COMMITTEE MEMBERS

- *Dr Abdelhafidh Slimane (Coordinator)*
- Dr Nejib Hattab
- Dr Mohamed Badri
- Dr Mohamed Maher Hadhri
- Dr Ines Cherif
- Dr Rihab Ben Fredj
- Dr Aziz Bedioui
- Dr Khalil Ayadi
- Dr Nesrine Nessib
- Dr Zohra Souei
- Dr Firas Sliti
- Dr Myriam Naceur

SCIENTIFIC COMMITTEE MEMBERS

- *Dr Fatma Kolsi (Coordinator)*
- Dr Lassad Bsili
- Dr Mohamed Dahmeni Yedeas
- Dr Ghassen Gader
- Dr Khansa Abderrahmen
- Dr Hichem Ammar
- Dr Brahim Kammoun
- Dr Mouna Rkhami
- Dr Karim Ben Hammouda
- Dr Khaled Radhouane
- Dr Kaïs Maamri
- Dr Khalil Ghedira
- Dr Ghassen Belkahla
- Dr Sameh Achoura

ATNCH OFFICE MEMBERS

TUNISIAN ASSOCIATION OF NEUROSURGERY
الجمعية التونسية لجراحة الجهاز العصبي

PRESIDENT
Prof. Imed Ben SAID

TREASURER
Dr Abdelhafidh Slimane

VICE PRESIDENT
Dr Mohamed Ladib

VICE TREASURER
Dr Ghassen Gader

SECRETARY GENERAL
Dr Mohamed Dahmani Yedeas

WEBSITE & COM MANAGER
Dr Ines Cherif

VICE SECRETARY GENERAL
Dr Fatma Kolsi

MEDICAL EDUCATION OFFICER
Dr Rihab Ben Fredj

Official Partners

التجهيز للطب و المستشفيات
M. M. H. S.A.
le matériel médical et hospitalier

MIETHKE

B|BRAUN
SHARING EXPERTISE



WE UNDERSTAND.

NEUROSURGERY

proGAV® 2.0

IN TOUCH WITH YOU

proGAV® 2.0

VALVE AND SOFT TOUCH TOOLS

MIETHKE

USER-FRIENDLY ADJUSTMENT & VERIFICATION

With the help of the unique "Soft Touch" instruments, the *proGAV® 2.0* offers a high level of patient comfort with its tactile feedback.

Pressing the valve surface lightly with your finger releases the "Active-Lock" mechanism and simultaneously sends a tactile feedback.



MRI 3 TESLA CONDITIONAL

The "Active-Lock" mechanism of the *proGAV® 2.0* prevents unintended valve adjustments by external magnetic fields up to 3 Tesla (3-5). Strainful follow-up examinations can thus be reduced for the patient.





M.blue® & M.blue plus®

M.blue® is the essence of 26 years of experience with hydrocephalus and valve technology and the feedback of numerous physicians and patients worldwide.

M.blue® is a valve for all forms of hydrocephalus with a particularly high flexibility in therapy.

Spiegelberg:
Technology for brains

Cutting-edge development and manufacturing excellence made in Germany

ICP- and CSF-Products

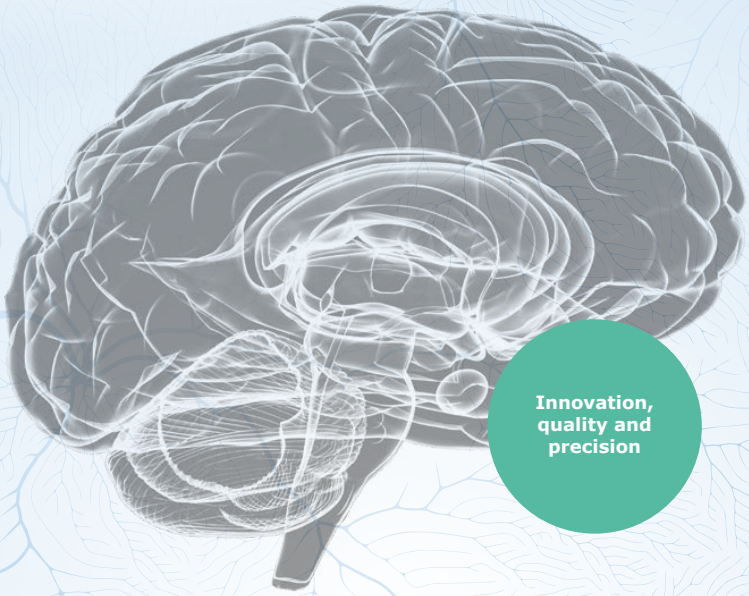

Innovation, quality and precision



B|BRAUN
SHARING EXPERTISE

AESCULAP® NEUROSURGERY

HAUPTKATALOG
MAIN CATALOG

WORKSHOP I
Spine Deformity

SOCIÉTÉ TUNISIENNE DE
NEUROCHIRURGIE

5/11/2026
The Russelior Hotel
Hammamet

In the framework of the panarab congress of Neurosurgery

The tunisian association of Neurosurgery organises the Workshop

SPINE DEFORMITY

- Theoretical Presentations
- Hands on training on 3D models under expert supervision



CONTACT

Dr Ghassen Gader
Mail: ghassgader@gmail.com
Whatsapp: 0021698604749

PRECONGRESS WORKSHOPS

WORKSHOP II
Full-Endoscopic Lumbar Spine Surgery

PRECONGRESS WORKSHOP

FULL-ENDOSCOPIC LUMBAR SPINE SURGERY

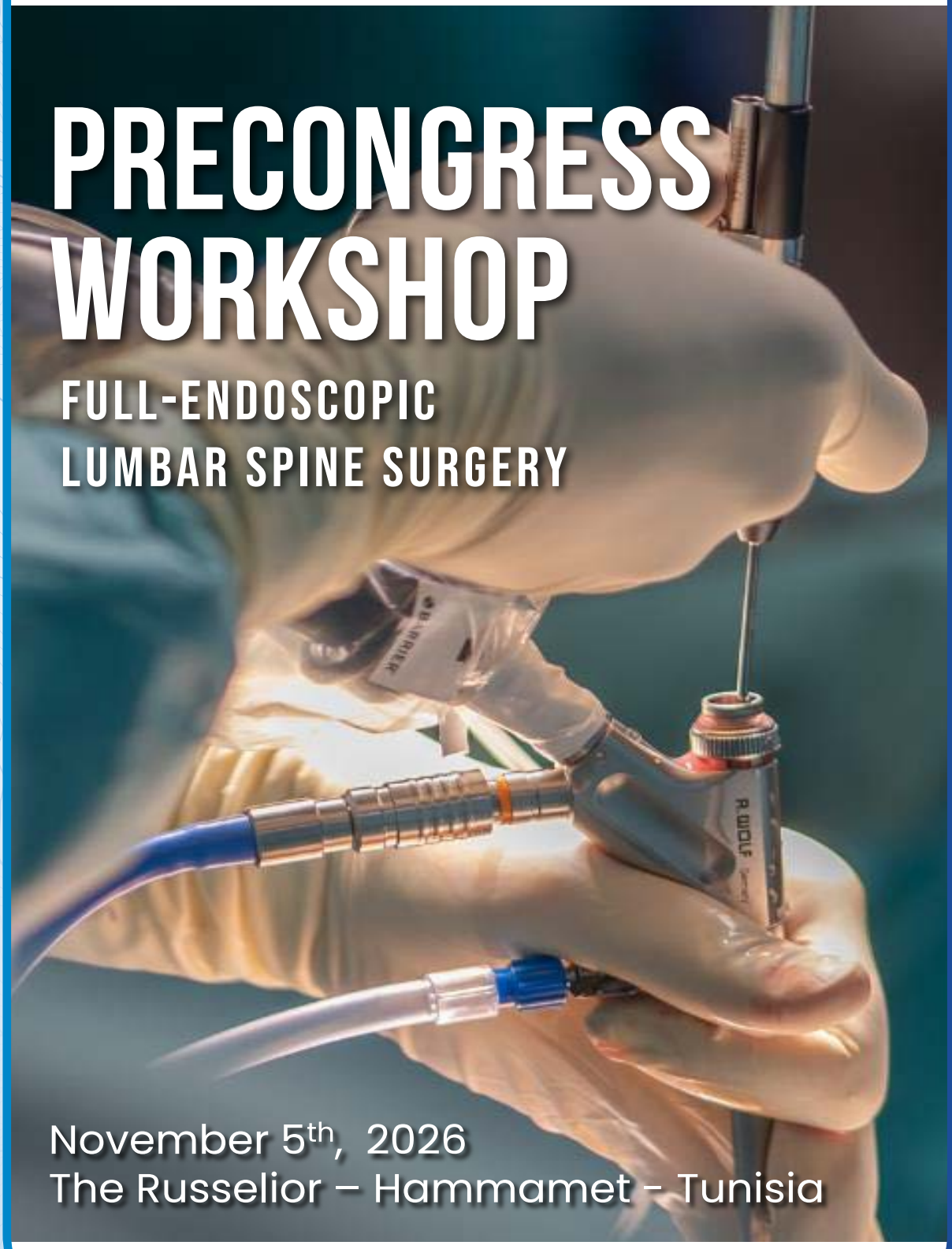

November 5th, 2026
The Russelior – Hammamet - Tunisia

15TH PANARAB & 39TH TUNISIAN NEUOSURGERY CONGRESSES

Official Partners

Ortho & Santé



Official Partners



PYTHEAS Your Guided Trajectory

Smart guidance for pedicular screw placement

For open and mini invasive surgeries

Posterior approach

Thoracic, lumbar and sacral levels

Simple and efficient

Minimal X-ray exposure

Cost effective

Compact, intuitive and portable



FDA - CE marked

PYTHEAS
DYNAMIX
MADE IN FRANCE



November 6, 2026

FRIDAY

08:00

WELCOME

Registration

08:15 – 09:45

TWO PARALLEL SESSIONS

Oral presentations

Free-paper communications presented in two rooms.

ORAL COMMUNICATIONS I

Hortensia Conference Room

Moderators : Fatma Kolsi, Khalil Ghedira, Mohamed Maher Hadhri Bassam Addas

ORAL COMMUNICATIONS II

Lilas Conference Room

Moderators : Sadok Ben Amor, Kamel Bouaita, Brahim Kammoun Mohamed Dehmani Yedeas

ORAL COMMUNICATIONS I

01 Comparative Clinical Outcomes and Safety of Endoscopic TLIF versus Minimally Invasive TLIF in Degenerative Lumbar Spine Disease : A Systematic Review and Meta-Analysis

Abdelrahman Alitre
Global Neurosurgical Students Council

02 Management of Degenerative Cervical Myelopathy : Our Experience

Mechiche Zohir, Messai Saddem, Mahdaoui Rima, Hallaci Azzedine
Neurosurgery Department - CHU SETIF - ALGERIA

03 Outcome and accuracy of posterior craniovertebral junction fixation techniques : a cohort prospective study of 44 cases.

SELMANE TOUFIK, Z.Abdellaoui, Z.Fellag, D.Dergham, A.Meliani, A.Mati, K.Bouaita
Neurosurgical specialized hospital, Cherchell, wilaya of TIPAZA 42002, ALGERIA

04 Osteoporotic Thoracolumbar Vertebral Fractures: A 10-Year Retrospective Case Series from a Neurosurgical Center

Hamid Khay, Amine Kada, Mohamed Dahamou, Mohammed Al amine El farissi, Mohammed Khoulali
University hospital Center Mohammed VI Oujda, Morocco

05 Tubular Endoscopy-Assisted Lumbar Microdiscectomy Using the EasyGO® System : A Single-Center Case Series of 31 Patients

Aziz Bedioui, A. Bedioui (1), S. Ben Zekri (2), G. Gader (1), S. Ben Yaacoub (1), M. Bounemra (2), MA. Hermassi (1) M. Rkhami (1), M. Badri (1), K.Bahri (1), I. Zammel (1)
(1) Neurosurgery department, Center of traumatology and severe burns of Ben Arous, Tunisia (2) Regional Hospital of Zaghouan, Tunisia

06 Minimally Invasive Surgery for Lumbar Disc Herniation: Endoscopic Discectomy versus Tubular Microdiscectomy

Ines CHERIF, Zohra SOUEI, Imen DAMMAK, Fares FERJANI, Hichem AMMAR
Department of Neurosurgery, Sfax Military University Hospital, Tunisia

ORAL COMMUNICATIONS I

07 Why Do Pedicle Screws Fail ? Identifying Predictors of Instrumentation Loosening After Spine Surgery

Majdouline Barkache, R. Ben Fredj, A. Affes, A. Hmida, I.Ksira
Neurosurgery Department of Sahloul, Sousse - Tunisia

08 Posterior-Only Occipito-cervical Fixation With Foramen Magnum Decompression for Basilar Invagination and Craniovertebral Junction Malformations : A 20-Patient Series from Algeria

Dergham Djamel eddine, D.Dergham, T. Selmane, A.Chabat, Z.fellag, S.Benallag, K.Bouaita
Department of neurosurgery, neurosurgery hospital Cherchall, Algeria

09 Neuronavigation-Guided C1–C2 Fixation

Nader Yahyaoui, Belkahla Ghassen, Mohamed Amine Hadj taieb, Mohamed Maher Hadhri, Kais Maamri Mehdi Darmoul.
Neurosurgery Department, Fattouma Bourguiba University hospital, Monastir, Tunisia.

10 Strategies and philosophy in the management of sciatic nerve injury

Bassam Addas
King Fahd hospital, Second health cluster, Jeddah; KSA

11 Uniportal Transforaminal Endoscopic Surgery for Foraminal and Extraforaminal Lumbar Disc Herniations : Clinical Outcomes and Technical Advantages

Houssem Hdhili, M.D. Yedeas, T. Kamoun, H. Kammoun, S. Achoura, A. Harbaoui, R. Chkili, K. Radhouane
Department of Neurosurgery, Military Hospital of Tunis, Tunisia.

ORAL COMMUNICATIONS II

12 Pretemporal transcavernous anterior petrosal approach for large petroclival meningiomas

Lassaad Bsili, Ahmed Maatoug
OLIVIER CLINIC, SOUSSE, TUNISIA

13 Challenges in the Surgical Management of Intrasellar and Suprasellar Neuroendocrine Tumors

Belgacem Ibrahim, Chahed Mbarek, Si Tayeb Fatima Zohra, Djouadi Yasmine, Aboudjabel Mohamed Maameri Lila, Ait Bachir Mustapha
Department of Neurosurgery, CHU Nedir Mohamed, Tizi Ouzou, Algeria

14 Visual Outcomes Following Surgical Resection of Tuberculum Sellae Meningiomas : A Retrospective Analysis

Kamel Bouaita, S. Benallag, T. Selmane, A.Mati, N.Baz
Neurosurgery departement EHS Cherchell, Blida Faculty of medecine, Algeria

15 Hearing Preservation Microsurgery for Vestibular Schwannomas using the Subperineurial Plane: A Contemporary Surgical Case Series

Ala BELHAJ, Joe SALIBA, Moujahed LABIDI
1Division of Neurosurgery, Department of Surgery, Centre Hospitalier de l'Université de Montréal (CHUM), Montréal, Quebec, Canada 2Division of Oto-rhino-laryngology, Department of Surgery, Centre Hospitalier de l'Université de Montréal (CHUM), Montréal, Quebec Canada 3Centre de Recherche du CHUM, Montréal, Quebec, Canada

16 Endoscopic Transorbital Approach for a Diverse Spectrum of Skull Base Lesions : The CHUM Montreal Experience

Ala Belhaj, Erika MASICOTTE, Moujahed LABIDI
1Division of Neurosurgery, Department of Surgery, Centre Hospitalier de l'Université de Montréal (CHUM), Montréal, Quebec, Canada 2Division of Ophthalmology, Centre Hospitalier de l'Université de Montréal (CHUM), Montréal, Quebec, Canada 3Centre de Recherche du CHUM, Montréal, Quebec, Canada

17 Resection of the Cavernous Sinus Medial Wall for Corticotroph and Somatotroph Adenomas

Ala BELHAJ, Axel Eluid RENTERIA , Philippe LAVIGNE , Moujahed LABIDI
1Division of Neurosurgery, Department of Surgery, Centre Hospitalier de l'Université de Montréal (CHUM), Montréal, Quebec, Canada 2Division of Oto-rhino-laryngology, Department of Surgery, Centre Hospitalier de l'Université de Montréal (CHUM), Montréal, Quebec Canada 3Centre de Recherche du CHUM, Montréal, Quebec, Canada

ORAL COMMUNICATIONS II

18 Cystic craniopharyngiomas in the elderly : Neurosurgical aspects, diagnostic criteria and management specificities

Talel Kamoun, Khaled Radhouane, Talel Kamoun, Amine Rachdi, Houssem hedhili, Mohamed Dahmeni Yedeas Ridha Chkili
Neurosurgery Department, Military Hospital of Tunis, Tunis, Tunisia

19 Facial Nerve Preservation in Cerebellopontine Angle Surgery : Outcomes, Determinants and the Role of Intraoperative Monitoring

Kamel Bouaita, S. Benallag, T. Selmane, A. Mati, A. Meliani
Neurosurgery departement EHS Cherchell, Blida Faculty of medecine, Algeria

20 VESTIBULAR SCHWANNOMA : A MULTICENTER STUDY OF 129 CASES

Emna Elouni, Haifa Mechergui, Salim Bachraoui, Roua Latrach, Khalil Ghedira, Sofiene Bouali, Jalel Kallel
Neurosurgery Departement, National Institute of Neurology, Tunis, Tunisia

21 MULTIDISCIPLINARY MANAGEMENT OF CRANIOPHARYNGIOMA : A SINGLE-CENTER EXPERIENCE

Sara Dellaldja, S.Dellaldja1;A.Terrak2;CH.Zair3;W.Moudjer4;R.Chetaibi4;L.Atroune5
ESH ALI AIT AIDIR, ALGIERS, ALGERIA

22 Neurosurgical Management of Intraorbital Tumors : A Six-Case Series and Review of Surgical Approaches

Emna Mzoughi, Emna Mzoughi, Nesrine Nessib , Amina Oueslati , Abdelhafid slimane,Amel Chebbi Khalil Ghedira, Sofiene Bouali
Department of neurosurgery , National Institute of Neurology, Tunisia.

09:00 – 10:00 *Coffee Break*

10:00 – 10:30

OFFICIAL CEREMONY

Opening Ceremony

Presided over by the Tunisian Minister of Public Health.

10:30 – 12:45

PLENARY SESSION I

Les Jasmins Hall

Spine : Spine Tumors & MISDS

Moderators : Ahmed Alkhani, Mehdi Darmoul, Hafedh Jemel, Mohamed Nabil Nessib, Hani Meniawi, Mohamed Zuhair

10:30 Microsurgical Outcome of Spine Tumors: Personal and Institutional Experience
Mahmoud M. Taha (Egypt)

10:45 Spinal Cord Ependymoma
Ahmed Alkhani (Saudi Arabia)

11:00 Transitioning to Hemilaminectomy for Excision of Intradural-Extramedullary Spinal Lesions : Overcoming Initial Technical and Logistical Challenges in a Beginner's Series
Riadh Rebai (Saudi Arabia)

11:15 Decision Making in the Surgical Treatment of Cervical Spine Metastasis: A Systematic Review of Literature
Faical Taleb (Libya)

11:30 Surgical Modifications of Chiari Malformations
Ali Almaashani (Oman)

PLENARY SESSION I

Les Jasmins Hall

11:45 MIS in Lumbar Disc Surgery : Tubular Microdiscectomy
Mohamed Zuhair (Iraq)

12:00 MIS in Degenerative Lumbar Spine : Monastir Experience
Mehdi Darmoul (Monastir, Tunisia)

12:15 Learning Curve and Complication Management in Full Endoscopic Spine Surgery : What Our First 200 Cases Taught Us
Mohamed Dehmani Yedeas / Khaled Radhouane

12:30 Junctional kyphosis after lumbar fixation and fusion in elderly
Hani El Meniawi (Syria)

12:45 – 14:00 *Lunch Break* | *Symposium* Elekta — Le Gamma Knife au-delà du traitement de recours

14:00 – 16:45

PLENARY SESSION II

Skull Base

Les Jasmins Hall

Moderators : Ali Almaashani, Abdeslam Elkhamlichi, Mahmoud Taha, Hedi Krifa, Jalel Kallel, Bachir Bellebna

14:00 Parasagittal, Falcine Meningiomas
Abdulghafar Kiwan (Syria)

14:15 Surgical Management of Planum Sphenoidale Meningiomas
Mohamed Benzagmout (Morocco)

14:30 Management of Atypical Meningioma
Hossam El Husseiny (Egypt)

14:45 The Value of Anterior Clinoidectomy for Sellar and Suprasellar Lesions Surgery
Jalal Najjar (Syria)

15:00 Supraorbital Approach for Pediatric Intracranial Lesions
Ali Almaashani (Oman)

15:15 Management of Brainstem Cavernomas
Najia Al Abadi (Morocco)

15:30 Surgical Management of Koos 4 Vestibular Schwannomas: Our Experience
Said Ait Ben Ali (Morocco)

15:45 Craniopharyngioma Surgery: A Delicate Balance of Oncological and Functional Results
Moujahid Labidi (Montreal)

16:00 Multimodal Planning and Resection of Skull Base Tumors
Walid Ibn Essaied (USA)

16:15 Pretemporal Transcavernous Anterior Petrosal Approach for Large Petroclival Meningiomas
Lassaad Bsili (Sousse, Tunisia)

16:30 Anterior Clinoid Meningioma Surgery: Technical Challenges and Lessons Learned
Kamel Bahri | Ghassen Gader (CTGB, Tunisia)

16:45 – 17:00 *Coffee Break*

17:00 – 18:30

PLENARY SESSION III

Pediatrics & Pituitary

Les Jasmins Hall

Moderators : Nasser El Ghandour, Ahmed Ammar, Mondher Yedeas, Mohamed Zaher Boudawara, Iadh Ksira, Hazem Mostafa

17:00 Integral Role of Neurosurgery in Managing Craniofacial Anomalies : 30 Years Experience in Managing Craniosynostosis
Hazem Mostafa (Egypt)

17:15 Endoscopic Treatment of Complex Hydrocephalus in Children
Nasser El Ghandour (Egypt)

17:30 Moya Moya in Children
Ahmed Ammar (Egypt)

17:45 Current Management of Large and Giant Pituitary Adenomas
Abdeslam Elkhamlichi (Morocco)

18:00 Endoscopic Pituitary Surgery : Mauritanian Experience
Sidi Salem Memou (Mauritania)

18:15 Complications After Titanium-Mesh Cranioplasty Following Penetrating Brain Injury in a Conflict Setting : A Prospective Cohort Study From Yemen, 2021-2024
Ahmed Al Jradi (Yemen)

17:00 – 17:45

TWO PARALLEL SESSIONS

Oral presentations

Free-paper communications presented in two rooms.

ORAL COMMUNICATIONS III

Hortensia Conference Room

Moderators : Khansa Abderrahman, Khaled Radhouane, Kais Maamri Ghassen Gader, Kacem El Asbahi

ORAL COMMUNICATIONS IV

Lilas Conference Room

Moderators : Sameh Achoura, Atef Ben Nsir, Abdelhafidh Slimane Hussein Hamdi

ORAL COMMUNICATIONS III

23 Blood, Clots, and Clarity : Does T1 Hyperintensity Predict Visual Outcome in Pituitary Apoplexy?
Radhouane Khaled, Farhat S, Affes A, Kammoun T, Kammoun H, Bouzouita K, Chkili Ridha, Yedeas MD, Ghedira K
Neurosurgery Department, Military Hospital of Tunis, Tunis, Tunisia.

24 Necrosis, Hemorrhage, or Both ? Histopathological Spectrum of Pituitary Apoplexy and Its Clinical Correlates
Radhouane Khaled, Farhat S, Affes A, Hdhili H, Kammoun H, Bouzouita K, Chkili Ridha, Yedeas MD, Ghedira K
Neurosurgery Department, Military Hospital of Tunis, Tunis, Tunisia.

25 Out of the Blind Spot : Recovery After Complete Visual Loss in Pituitary Apoplexy
Radhouane Khaled, Farhat S, Affes A, Kammoun T, Kammoun H, Bouzouita K, Chkili Ridha, Yedeas MD, Ghedira K
Neurosurgery Department, Military Hospital of Tunis, Tunis, Tunisia.

26 Prognostic Factors for Visual Recovery After Surgery for Pituitary Apoplexy
Radhouane Khaled, Farhat S, Affes A, Kammoun T, Kammoun H, Bouzouita K, Chkili Ridha, Yedeas MD, Ghedira K
Neurosurgery Department, Military Hospital of Tunis, Tunis, Tunisia.

ORAL COMMUNICATIONS III

27 The Pituitary Apoplexy Score (PAS) and Surgical Timing: Implications for Visual Outcome

Radhouane Khaled, Farhat S, Affes A, Kammoun T, Kammoun H, Bouzouita K, Chkili Ridha, Yedeas MD, Ghedira K
Neurosurgery Department, Military Hospital of Tunis, Tunis, Tunisia.

28 Thin Blood, Thick Trouble: Anticoagulant Use and Visual Field Recovery After Surgery for Pituitary Apoplexy

Radhouane Khaled, Farhat S, Affes A, Hdhili H, Kammoun H, Bouzouita K, Chkili Ridha, Yedeas MD, Ghedira K
Neurosurgery Department, Military Hospital of Tunis, Tunis, Tunisia.

29 Descriptive Study of 32 Cases of Pituitary Apoplexy Managed by Transsphenoidal Surgery

Radhouane Khaled, Farhat S, Affes A, Hdhili H, Kammoun H, Bouzouita K, Chkili Ridha, Yedeas MD, Ghedira K
Neurosurgery Department, Military Hospital of Tunis, Tunis, Tunisia.

ORAL COMMUNICATIONS IV

30 Beyond the Shunt : Quality of Life and Functional Outcomes in Children with Treated Hydrocephalus

Firas Gahbiche, F. Kolsi, I. Cherif, K. Ayadi, B. Essid, S. Abdelmoula, S. Chaari, M. Taallah, M. Borni, B. Kammoun W. Elleuch, MZ. Boudawara
Neurosurgery Department, Habib Bourguiba Hospital, Sfax, Tunisia; 2. Neurosurgery Department, HMUS, Sfax, Tunisia; 3. Physical Medicine and Rehabilitation, HMUS, Sfax, Tunisia.

31 Congenital Myelomeningocele and Hydrocephalus : A Clinical Audit

Seraj Ajaj, Faisal Taleb, Seraj Ajaj, Samira Abudia, Lali Ali Albakoush
Departments of Neurosurgery and Obstetrics and Gynecology, Tripoli University Hospital, Tripoli, Libya.

32 Endoscopic Management of Hydrocephalus Experience of the Neurosurgery Department of Mohammed VI University Hospital of Oujda

Dahamou Mohamed, Dahamou Mohamed, Elfarissi Mohammed Alamine, Khoulali Mohamed, Khay Hamid
Neurosurgery Department, Mohammed VI University Hospital, Oujda, Morocco

33 Surgical Management of Chiari I Malformation Associated with Syringomyelia : Analysis of 132 Cases, Effect of Surgery on Chiari I and Syrinx, and Our Intraoperative Findings

Belgacem Ibrahim, Si Tayeb Fatima Zohra, Chahed Mbarek, Djouadi Yasmine, Aboudjabel Mohamed Maameri Lila, Ait Bachir Mustapha
Department of Neurosurgery, CHU Nedir Mohamed, Tizi Ouzou, Algeria.

34 The M.scio Implantation for Intracranial Pressure Monitoring: A Promising Device for Personalized Management of Complex Hydrocephalus

Haifa Mechergui, Salim Bachraoui, Khalil Ghedira
Surgery Department, Bougatfa Hospital, Bizerte, Tunisia; Department of Neurosurgery, National Institute of Neurology of Tunis, Tunisia.

35 Ultrasound-Guided Percutaneous Ventriculoatrial Shunting: A Safe, Minimally Invasive Alternative for Adult Cerebrospinal Fluid Diversion

Houssem Hdhili, F. Akrout, S. Farhat, H. Kammoun, S. Achoua, A. Harbaoui, R. Chkili, M.D. Yedeas, K. Radhouane
Department of Neurosurgery, Military Hospital of Tunis, Tunisia.

36 Understanding Ventriculoperitoneal Shunt Failure: Predictors of Revision in Pediatric Hydrocephalus

Majdouline Barkache, M. Ben Messsaoud, H. Kammoun, A. Affes, I. Ksira
Department of Neurosurgery, Sahloul Hospital, Sousse, Tunisia.

SOCIAL EVENT

Gala Dinner

Out of Neurosurgery.

Les Jasmins Hall

20:30

E-POSTERS

Poster Sessions

MORNING

POST 1
P1-P25

Moderators :
Ines Cherif
Aziz Bedioui

POST 2
P26-P50

Moderators :
Amine Trifa
Rihab Ben Fredj

POST 3
P51-P75

Moderators :
Mechergui Haifa
Firas Akrout

AFTERNOON

POST 1
P76-P100

Moderators :
Khalil Ayadi
Nesrine Nessib

POST 2
P101-P125

Moderators :
Mahmoud Ben Messaoud
Aziz Hermassi

POST 3
P126-P151

Moderators :
Amine Rachdi
Anis Hachicha

PLANET MEDICAL +
SPINAL SOLUTIONS & MEDICAL EQUIPMENT
ORTH SPINE TUNISIE MÉDICAL
TOUCOMEX
Tout le confort du Malade
الطـبّ والجـراحـة
MEDICO - CHIRURGICAL
MEDICOM
VENTE MATÉRIEL ORTHOPÉDIQUE
SOGEMM
TERIAK
MédiS
Au service de la santé
unimed
Laboratoires

Official Partners

Quality Medical Business

La Qualité c'est notre Devise

ZEISS
Seeing beyond

BRAINLAB

NSK
MADE IN JAPAN

joimax®
Endoscopic Spine Experts

inomed

Söring
INNOVATIVE SURGERY

Surgical Electrical Drill Set

NSK



Key Differentiators:

- Low Noise
- High Torque Motor
- Most powerful high speed electric drill in the market: 100,000rpm and 6N/cm
- High Speed Hand Piece
- Pre-Load burs directly into the Handpieces
- Virtually generates NO heat

BRAINLAB

SIMPLICITY IN NEURONAVIGATION

Brainlab Cranial Navigation. Efficiently combining decisive aspects of neurosurgery.

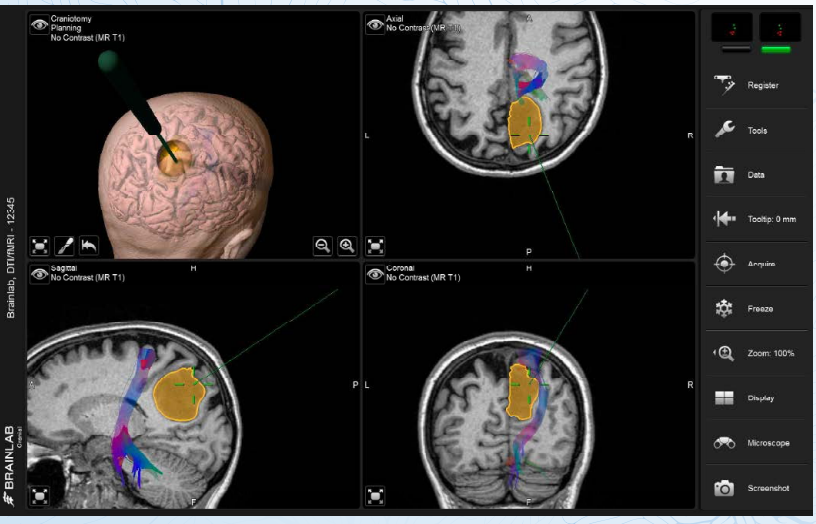

Brainlab® Cranial 3.0 provides a new user experience on Kick® and Curve™ navigation platforms. Fully DICOM-based, cranial navigation and Brainlab Elements* can run parallel with instant synchronization to update navigated image sets with new fusion results, SmartBrush® objects or trajectories.

NEW AND IMPROVED FEATURES IN CRANIAL 3.0

- Further reduced user interface and automated workflows
- Improved tracking robustness
- Virtual bone flap removal with 3D Craniotomy Planning view
- Motorized microscope alignment to trajectories
- Improved visualization of objects in microscope Head Up Display
- Digital BK Medical ultrasound integration* with full-resolution transmission of images
- VarioGuide assembly video for easy setup

inomed

Stimulation corticale directe



C2 Xplore

Une longueur d'avance dans le neuromonitoring peropératoire

Turning complex into clarity.



ZEISS KINEVO 900 S

ZEISS

Seeing beyond

zeiss.com/kinevo

joimax®
Endoscopic Spine Experts

OUR PATH TO
ENDOSCOPIC FUSION



EndoLIF® LEX®
Endoscopic Lumbar Interbody Fusion



Percusys® Plus
Percutaneous Screw Rod System



iLESSYS® Biportal
Interlaminar Biportal Endoscopic Surgical System

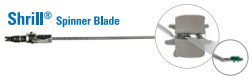

Shrill® Spinner Blade



Vaporace® Bipo
Bipolar Instruments for Soft Tissue Resection



DoubleDrill



J-Needle Navigated



iLESSYS® Delta
Interlaminar Endoscopic Surgical System

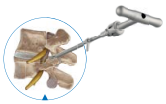

TESSYS® Trans SAP
Transforaminal Endoscopic Surgical System

APPROACH | DECOMPRESSION | IMPLANTATION



NAV ENTO®
Navigation Endoscopic Tower

HIGH QUALITY ENGINEERED IN GERMANY SYSTEMS

Disclaimers
Certain products may not be approved for sale in all countries.

www.joimax.com

New ultrasonic unit for LEVICS in neurosurgery

Söring

- Modern operating concept and easy handling









- LEVICS instruments for neurosurgery



- Resection effect optimized for each tissue consistency

reddot winner 2025



- High safety and maximum control on critical structures

- Wireless foot switch with Safety Level button

November 7, 2026

SATURDAY

08:00 – 10:00

TWO PARALLEL SESSIONS

Oral & Video Presentations

Free-paper communications presented in two rooms.

ORAL COMMUNICATIONS V

Hortensia Conference Room

Moderators : Hammouda Guesmi, Said Ait Ben Ali, Khalil Ghedira Tamer Hassan, Khaled Fares Al Ali

VIDEO PRESENTATIONS

Lilas Conference Room

Moderators : Lassaad Bsili, Riadh Rebai, Walid Ibn Essaied Ahmed Alazri, Mohamed Maher Hadhri

ORAL COMMUNICATIONS V

37 From a Welding Gun Injury to Evidence Synthesis : Endovascular Therapy for Traumatic Vertebral Artery Injury—A Systematic Review and Meta-Analysis Inspired by a Clinical Case

Ibrahim Alnaami
King Khalid university,Abha, Saudi Arabia

38 Microsurgical clipping versus Woven EndoBridge for intracranial aneurysms : a systematic review and meta-analysis

Ibrahim Alnaami
King Khalid university,Abha, Saudi Arabia

39 INTRACRANIAL ANEURYSMS WITH MASS EFFECT: WHY SURGERY REMAINS THE ONLY COMPLETE ANSWER — 55 CASES

Yacine Felissi, Felissi Y., Meziani S., Handis C., Hadjali H., Ghozlane H., Morsli A.
Department of Neurosurgery, Bab El Oued University Hospital, Algiers, Algeria

40 SURGICAL MANAGEMENT OF MIDDLE CEREBRAL ARTERY ANEURYSMS THROUGH THE DISTAL TRANSSYLVIAN APPROACH : TECHNICAL RATIONALE AND OUTCOMES

Yacine Felissi, Felissi Y., Meziani S., Handis C., Zireg H., Ghozlane H., Morsli A.
Department of Neurosurgery, Bab El Oued University Hospital, Algiers, Algeria

41 Determinants of Long-Term Outcome in Cushing's Disease : A Multicenter Retrospective Study

Emna Elouni, Ghassen Elkahla, Mehdi Darmoul, Mohamed Zaher Boudouara, Jalel Kallel
Neurosurgery Departement, National Institute of Neurology, Tunis, Tunisia Neurosurgery Departement of Fattouma Bourguiba University Hospital, Monastir, Tunisia Neurosurgery department of Hbib Bourguiba University hospital, Sfax, Tunisia

42 LONG-TERM OUTCOMES OF PITUITARY ADENOMAS : COMPLICATIONS, VISUAL ASSESSMEN AND EXTENT OF RESECTION (A SERIES OF 400 CASES)

Belgacem Ibrahim, Si Tayeb Fatima Zohra, Chahed Mbarek, Djouadi Yasmine, Aboudjabel Mohamed Maameri Lila, Katia Ait Slimani, Ait Bachir Mustapha
Department of Neurosurgery, CHU Nedir Mohamed, Tizi Ouzou, Algeria

43 CUSHING'S DISEASE WITHOUT A VISIBLE PITUITARY ADENOMA ON MRI : THE ROLE OF INFERIOR PETROSAL SINUS SAMPLING

Belgacem Ibrahim, Si Tayeb Fatima Zohra, Chahed Mbarek, Djouadi Yasmine, Aboudjabel Mohamed Maameri Lila, Katia Ait Slimani, Ait Bachir Mustapha
Department of Neurosurgery, CHU Nedir Mohamed, Tizi Ouzou, Algeria

44 vertebromedullary trauma in children

EL KARTIT FATIMA, Mohammed Khoulali, Hamid Khay, Mohammed Al amine El farissi, Mohamed Dahamou,
Mohammed VI university hospital of OUJDA, Morocco

45 Pediatric Intracranial Suppurations : Three Distinct Etiologic Pathways—A Bicentric Hypothesis-Generating Study

Firas Gahbiche, M. Borni, M. Znazen, F. Kolsi, M. Taallah, MZ. Boudawara
Habib Bourguiba University Hospital - Sfax, Tunisia

46 Encephalocele Experience of the Neurosurgery Department of Mohammed VI University Hospital of Oujda (About 11 Cases)

Dahamou Mohamed, Elfarissi Mohammed Alamine, Khoulali Mohamed, Khay Hamid Kada amine, Elkartit Fatima, Aniya Loubna
Neurosurgery Department, Mohammed VI University Hospital, Oujda, Morocco

47 Optic Pathway Gliomas in Children: Visual Outcome and Prognostic Factors — A 14-Year Single-Center Retrospective Study

oualha zied, N.Nessib , F.Kolsi , A.Slimane , F.Sliti ,M.Naceur ,A.Bouhoula , S.Bouali , K.Abderrahmen, I.B. Said, J.Kallel
Department of Neurosurgery, National institute of neurology, Tunis, Tunisia.

48 Surgical techniques of non-syndromic craniostenosis: results and long-term outcome of a retrospective Serie of 122 cases

TOUFIK SELMANE, Z. Abdellaoui, A. Chabat, S. Chennaoui, Z. Fellag, D. Dergham, K. Bouaita
NEUROsurgical specialized hospital, Cherchell 42002, Wilaya of TIPAZA, ALGERIA

VIDEO PRESENTATIONS

V1 MECKEL CAVE MENINGIOMA WITH CONCOMITTANT NEUROVASCULAR CONFLIT CAUSING SEVERE TRIGEMINAL NEURALGIA SURGICAL APPROACH

KTARI OMAR, BSILI LASSAAD
OLIVIER CLINIC, SOUSSE, TUNISIA.

V2 Pretemporal Transcavernous Approach for Pituitary Macroadenomas with Cavernous Sinus Invasion : Video Presentation of Two Cases

Lassaad Bsili, Ahmed Maatoug
OLIVIER CLINIC, SOUSSE, TUNISIA.

V3 Is Complete Resection of Craniopharyngioma Always Possible ? a Challenging Surgical Case with Video Demonstration

Farah Bahri, F.Ben Atig[2], H.Hdhili, M.A.Kharrat, M.Bounemra, A.Hermassi, S.Ben Zekri, A.Bedioui, M.Rkhami M.Badri, K.Bahri, I.Zammel
Center of Traumatology and Burns of Ben Arous, Regional Hospital Sadok Mokaddem of Djerba, Tunisia

V4 Facing the Triple Challenge : Surgical Management of Triple Cerebral Aneurysms

Ferial Mokfi, Houari, Derbal, Belahoul, Guezzen, Benamara, Mimouni, Arab, Belebna, Guerbouz.
Department of neurosurgery 1 Novembre Oran, Algeria.

V5 Microsurgical Clipping of Rupted Large Posteriorly Directed Anterior Communicating Artery Aneurysms : Video Presentation of Two Illustrative Cases

AHMED MAATOUG, BSILI LASSAAD
OLIVIER CLINIC, SOUSSE, TUNISIA.

V6 Micosurgical management of large paraclinoid aneurysms : video presentation of two illustrative cases

bsili lassaad, Maatoug Ahmed
OLIVIER CLINIC, SOUSSE, TUNISIA.

V7 Surgical management of cervical ruptured AVM

Abdelaziz Bennadji, Ouarda Guerza -Lobna Hamadou- Zakia Guerfi
University Batna, Batna university hospital center, Algeria

VIDEO PRESENTATIONS

V8 Superficial Temporal Artery to Middle Cerebral Artery Bypass in Moyamoya disease: a video case

Khalil Ghedira, (1), Roua Latrach(1), Firas Sliti(1), Wissal Nsiri(2), Insaf Dkhil(3), Amine Ben Lakhal(3) Adonis Halouani(3)

1: Neurosurgery Department ; 2: Department of Anesthesiology and Resuscitation ; 3: Department of Neuroradiology Mongi Ben Hamida National Institute of Neurology of Tunis, Tunisia

V9 Surgical management of intraventricular hydatid cyst :technical notes

Abdelaziz Bennadji, Abdelhak Benzid,Ouarda Zeroual, Zhor Mekentichi

University Batna 2-Batna university hospital center.Algeria

V10 Endoscopic transnasal resection of an optic nerve cavernoma: 2- dimensional operative video

Nesrine JEMEL, MD[1,2,3]; Lavigne Philippe MD[1,4]; Fournier Sebastien PhD, DABNM[5,6]; Alqadasi Khalil MD[1,2] Rouleau Jacinthe MD[1,7]; Labidi Moujahed MD[1,2,3]

[1]*CHUM: Centre Hospitalier Universitaire de l'Université de Montréal, Montreal, Quebec, Canada;*

[2]*Division of Neurosurgery, Department of Surgery, University of Montreal, Montreal, Quebec, Canada;*

[3]*Centre de recherche du Centre hospitalier de l'Université de Montréal (CRCHUM), Montreal, Quebec, Canada;*

[4]*Division of Otorhinolaryngology, Department of Surgery, University of Montreal, Montreal, Quebec, Canada;*

[5]*Rampart Neurophysiology Inc., Levis, Quebec, Canada;*

[6]*Department of Surgery, Laval University, Quebec City, Quebec, Canada;*

[7]*Department of Ophthalmology, University of Montreal, Montreal, Quebec, Canada*

V11 Endoscopic Endonasal Management of Papillary and Adamantinomatous Craniopharyngiomas A Comparative Operative Video with a Proposed Role for Intraoperative Raman-Spectroscopy

Nesrine JEMEL, [1], Ana Bokasova MSc[2], Najib Nassiri BSc[2], Philippe Lavigne MD FRCSC[3], Frederic Leblond PhD[2] Moujahed Labidi MD FRCSC[1]

[1]*Division of Neurosurgery , Centre Hospitalier de L'Université de Montréal, Montreal, QC, Canada;*
[2]*Polytechnique Montréal, Dept. of Engineering Physics, Montreal, QC, Canada;*
[3]*Division of Otolaryngology-Head and Neck Surgery, Centre Hospitalier de L'Université de Montréal, Montreal, QC, Canada*

V12 When Endoscopy Meets Synovial Cysts: A Minimally Invasive Route to Complete Neural Decompression

Hajer Kammoun, K. Bouzouita, S. Farhat, A. Affes, S. Achoura, A. Harbaoui, R. Chkili, M.D. Yedeas, K. Radhouane

Neurosurgery department, Principal Military Hospital of Instruction of Tunis, Tunisia

V13 Primary Central Nervous System B-Cell Lymphoma Presenting as an intraventricular lesion with Obstructive Hydrocephalus: A Case Report

Khalil Ayadi, F. Kolsi, B Kammoun, MZ Boudawara

Department of neurosurgery Habib Bourguiba University Hospital

V14 Navigating the Third Ventricle: Lessons from 20 Endoscopic Third Ventriculostomies.

Djouadi yasmina, I.Belgacem.M.Abou Djabel.M.Chahed.M.Ait Bachir.

Department of Neurosurgery, CHU Nedir Mohamed.Tizi Ouzou, Algeria

V15 Endoscopic Identification of Septal Abnormality in Triventricular Hydrocephalus : A Case Report

Farah Bahri, F.Ben Atig[2], H.Hdhili, S.Ben Yakoub, M.Bounemra, A.Hermassi, S.Ben Zekri, A.Bedioui, M.Rkhami M.Badri, K.Bahri

Center of Traumatology and Burns of Ben Arous, [2]Regional Hospital Sadok Mokaddem of Djerba, Tunisia

10:00 – 12:15

PLENARY SESSION IV

Les Jasmins Hall

Functional Neurosurgery I : Trigeminal Neuralgia & Epilepsy Surgery

Moderators : Kamel Bahri, Nejib Khouja, Sofiane Bouali, Benaissa Abdennebi, Abdurrahmen Shudaifat, Mohamed Albalooshi

10:00 Since 2000, Have We Made Progress in the Neurosurgical Treatment of Trigeminal Neuralgia ?
Benaissa Abdennebi (Algeria)

10:15 Microvascular Decompression (MVD) for 54 Cases of Trigeminal Neuralgia: One Hand Surgeon
Jalal Najjar (Syria)

PLENARY SESSION IV

Les Jasmins Hall

10:30 Microvascular Decompression of the Trigeminal Nerve: Experience of the National Institute of Neurology
Abdelhafidh Slimane / Ala Belhadj (INN Tunis)

10:45 Treatment of Trigeminal Neuralgia by Gamma Knife: Single Institute Experience
Abdurrahmen Shudaifat (Jordan)

11:00 Navigating Precision : Anatomical Insights into the Efficacy of Masks Versus Stereotactic Frames in Icon Gamma Knife Treatment for Trigeminal Neuralgia
Moneer Faraj (Iraq)

11:15 Stereotactic and Functional Surgical Treatments for Drug Resistant Epilepsy
Fadi Almahariq (Croatia)

11:30 Radiosurgery and Ablative Epilepsy Surgery
Hussein Hamdi (Egypt)

11:45 Invasive EEG in Epilepsy Surgery : Does It Improve Surgical Success?
Mahmoud Abdallah (Jordan)

12:30 – 14:00 *Lunch Break* | MIETHKE *Symposium*

14:00 – 16:30

PLENARY SESSION V

Vascular Neurosurgery

Les Jasmins Hall

Moderators : Ihsen Zemmal, Ridha Chkili, Lassaad Bsili, Abdessamad El Ouahabi, Islam Gawish, Mouna Rkhami

14:00 Arteriovenous Malformations (AVM) : One of the Greatest Challenges in Neurosurgery
Abdeslam Elkhamlichi (Morocco)

14:15 Posterior Cerebellar Artery with an Extradural Origin More Common on the Non-Dominant Vertebral Artery
Muneyoshi Yasuda / Taiki Isaji (Japan)

14:30 Pterional Approach for Ruptured Intracranial Aneurysms: Surgical Results, Occlusion Rates and Perioperative Outcomes
Kamel Bouaita (Algeria)

14:45 Management of Intracranial Aneurysms in Mauritania
Hamoud Sidi Mohamed (Mauritania)

15:00 Dural and Extradural Cavernous Venous Malformations
Walid Ibn Essaied (USA)

15:15 Anterior Clinoidectomy for Aneurysm Surgery
Lassaad Bsili (Sousse, Tunisia)

15:30 Current Management of Complex Cerebral Aneurysm: What is the Best Treatment Option?
Abdessamad El Ouahabi (Morocco)

15:45 Anterior Communicating Artery Aneurysm Clipping: Lessons Learned from Parent Vessel Geometry
Tamer Hassan (Alexandria, Egypt)

PLENARY SESSION V

Les Jasmins Hall

16:00 Minimally Invasive Microsurgery for Ruptured and Complex Intracranial Aneurysms : Limitations, Technical Evolution and Future Perspectives
Islam Gawish (Berlin, Germany)

16:15 Learning Vascular Neurosurgery in the Era of Endovascular Treatment
Khalil Ghedira (INN, Tunis)

16:30 – 16:45 *Coffee Break*

16:45 – 18:15

PLENARY SESSION VI

Functional Neurosurgery II : Parkinson & Spasticity

Les Jasmins Hall

Moderators : Nejib Hattab, Hichem Ammar, Sadok Ben Amor, Fadi Almahariq, Abdelhakim Lakhdar, Faisal Taleb

16:45 The Parallel Path : Establishing a DBS Center and Training in Functional Neurosurgery
Fadi Almahariq (Palestine / Croatia)

17:00 Deep Brain Stimulation: Contribution and Challenges
Abdelhakim Lakhdar (Morocco)

17:15 How to Achieve Good Results in Parkinson's Surgery : A Series of 143 Patients
Lakhdar Guenene (Algeria)

17:30 Combined Unilateral Pallidotomy and Thalamotomy in Tremor-Dominant Parkinson's Disease Versus Pallidotomy Alone: A Prospective Comparative Study
Abdulrahman Alkish (Libya)

17:45 Non-Invasive Thalamotomy for Tremors
Hussein Hamdi (Egypt)

18:00 Selective Dorsal Rhizotomy for Management of Spasticity Due to Cerebral Palsy : Libyan Experience
Abdulrahman Alkish (Libya)

16:45 – 17:30

TWO PARALLEL SESSIONS

Oral presentations

Free-paper communications presented in two rooms.

ORAL COMMUNICATIONS VI

Lilas Conference Room

Moderators : Sobhy Houissa, Fatma Kolsi, Kais Maamri
Amro Khaldoun, Sidi Salem Memou, Ali Ayed

ORAL COMMUNICATIONS VII

Hortensia Conference Room

Moderators : Mouna Rkhami, Sameh Achoura, Jalal Najjar
Mahmoud Abdallah, Mohamed Ben Zagmout

ORAL COMMUNICATIONS VI

49 After the Long Road : Professional Satisfaction, Burnout, and Career Aspirations Among Tunisian Neurosurgery Residents — A National Cross-Sectional Survey

AMEUR AFFES, Rachdi M.A., Affes A, Hdhili H, Kammoun T, Akrout F, Chkili Ridha, Radhouen K.
Neurosurgery Department, Military Hospital of Tunis, Tunis, Tunisia.

50 Beyond Borders : Saudi Arabia's Evolving Model of Philanthropic and Global Neurosurgery

Ibrahim Alnaami, Ibrahim Alnaami
King Khalid University, Abha, Saudi Arabia.

51 Establishing a Subthalamic Nucleus Deep Brain Stimulation Program for Parkinson's Disease : Early Outcomes and Complications in the First 10 Patients

Soumia Benallag, Z. Abdellaoui, S. Chennaoui, K. Bouaita
Neurosurgery Department, EHS Cherchell, Blida Faculty of Medicine, Algeria.

52 Factors Associated with Recurrence of Colloid Cysts of the Third Ventricle : A Retrospective Surgical Series and Literature-Based Discussion

Ouared Habiba, S. Benallag, A. Meliani, A. Mati, T. Selmane, K. Bouaita
Department of Neurosurgery, EHS Cherchell, Tipaza, Algeria.

53 Low Cost Cranial Neuronavigation System Based on a Smartphone and PC : Development Assisted by Artificial Intelligence

Sofiane IMEKRAZ, S. IMEKRAZ (1), N. FRISSOU (2,3)
(1) Faculty of Medicine of Annaba, Annaba University Hospital, Algeria;
(2) Environmental Research Center of Annaba, Algeria; (3) IFORCE Faculty of Mathematics, USTHB Algiers, Algeria.

ORAL COMMUNICATIONS VII

54 Management of Disabling Spasticity with Functional Neurosurgery (Selective Microsurgical Neurotomy)

AFIF AFIF, MD, PhD, HDR
Department of Neurosurgery; Department of Anatomy, INSERM U 1028; Pain Center, Pierre Wertheimer Hospital, Lyon 1 University European Hospital, Paris, France.

55 Neurosurgical Management of Treatment-Resistant Obsessive-Compulsive Disorder

Ghassen SOUISSI, G. SOUISSI, J. FARISSE, A. CRETOL, A. BALOSSIER, J. RÉGIS
Department of Functional and Stereotactic Neurosurgery and Gamma Knife Radiosurgery, La Timone University Hospital, Marseille, France 2. Department of Psychiatry, La Conception University Hospital, Marseille, France.

56 Patient-Specific 3D-Printed Molds for Low-Cost Cranioplasty : A Multicenter Prospective Series Demonstrating an Affordable Alternative to Custom Cranial Implants

Houssem Hdhili, F. Akrout, S. Farhat, T. Kamoun, S. Achoura, A. Harbaoui, R. Chkili, M.D. Yedeas, K. Radhouane
Department of Neurosurgery, Military Hospital of Tunis, Tunisia.

57 Percutaneous Radiofrequency Thermocoagulation for Classical Trigeminal Neuralgia : A 13-Year Single-Center Experience

Houssem Hdhili, S. Farhat, A. Belhaj, Z. Oualha, J. Kallel, S. Bouali
Neurosurgery Department, National Institute of Neurology, Mongi Ben Hmida, Tunis, Tunisia.

58 Usefulness of Awake Craniotomy in Tuberculoma Resection in the Motor Area : Report of Two Cases

Emna Mzoughi, Emna Mzoughi, Khalil Ghedira, Nesrine Chaouch, Emna Ouni, Wissal Nsiri, Insaf Dkhil Khansa Abderrahmen
Department of Neurosurgery, National Institute of Neurology, Tunisia.

59 Wired for Pleasure : What Neurosurgery Teaches Us About the Brain's Sexual Plasticity

AMEUR AFFES, Barkache M, Akrout F, Rachdi MA, Kammoun T, Farhat S, Chkili R, Radhouen K
Neurosurgery Department, Military Hospital of Tunis, Tunis, Tunisia.

E-POSTERS

Poster Sessions

MORNING

POST 1

P152-P177

Moderators :
Mohamed Znazen
Kaouther Somrani

POST 2

P178-P203

Moderators :
Mohamed Amine Hadj Taieb
Chiheb Abdelileh

POST 3

P204-P229

Moderators :
Mohamed Boukhit
Fatma Ben Atig

AFTERNOON

POST 1

P230-P255

Moderators :
Ghassen El kahla
Omar Hattab

POST 2

P256-P281

Moderators :
Marwen Taalah
Sinda Ben Zekri

POST 3

P282-P302

Moderators :
Firas Stiti
Ala Belhaj

XEN Laboratoires
ABDiIBRAHIM
PHILADELPHIA PHARMA Health Priority
Prothefab innovation for better care
LYNK&CO
VOLVO
ARAmez MEDICAL
TT Tunisie Telecom

Official Partners

Elekta









November 8, 2026

SUNDAY

08:30 – 10:00

TWO PARALLEL SESSIONS

Oral presentations

Free-paper communications presented in two rooms.

ORAL COMMUNICATIONS VIII

Lilas Conference Room

Moderators : Brahim Kammoun, Mohamed Dehmani Yedeas Abdelghaffar Kiwan, Ahmed Jradi

ORAL COMMUNICATIONS IX

Hortensia Conference Room

Moderators : Iadh Ksira, Ghassen Gader, Abdulrahman Alkish Hamoud Sidi Mohamed

ORAL COMMUNICATIONS VIII

60 Surgical Management of Mesial Temporal Gliomas Associated with Drug-Resistant Temporal Lobe Epilepsy : Lesionectomy Alone or Combined Epilepsy Surgery ? A Four-Case Series

MAATOUG AHMED, Bsili Lassaad
OLIVIER CLINIC, SOUSSE, TUNISIA.

61 Epidemiological and Histopathological Profile of Primary CNS Tumors in Eastern Morocco : A 5-Year Review of 120 Cases

Mohammed Al amine El Farissi, Mohamed Dahamou1, Hamid Khay1, Khoulali Mohamed Anas Haloui2, Amal Benani2
1 Department of Neurosurgery, Mohammed VI University Hospital, Faculty of Medicine and Pharmacy of Oujda, Mohammed First University Oujda, Morocco. 2 Laboratory of Pathological Anatomy, Mohammed VI University Hospital, Faculty of Medicine and Pharmacy of Oujda, Mohammed First University, Oujda, Morocco.

62 Awake Craniotomy with Functional Mapping and Intraoperative Ultrasound for Glioma Resection : Maximizing Extent of Resection While Preserving Neurological Function

Kamel Bouaita, S. Benallag, N. Baz, A, Alem
Neurosurgery departement EHS Cherchell, Blida Faculty of medecine, Algeria

63 Management of parasagittal meningiomas: multimodal strategies and risk stratification in the era of molecular classification.

MESSAI Saddem, MECHICHE Zohir , MAHDAOUI Rima , HALLACI Azeddine .
Neurosurgery Department, SETIF, Algeria.

64 Surgical Management of Central Nervous System Hemangioblastomas : A 32-Case Experience

HALLACI Azzedine, D.Hallaci , S.Messai , R.Mahdaoui , , Z.Mechiche.
Neurosurgery Department, SETIF, Algeria.

65 Posterior Fossa Tumors : A Comparative Study Between Pediatric and Adult Populations

Ines Ferchichi, Mohamed Amine Hadj Taieb, Nader Yahyaoui, Mehdi Darmoul
Neurosurgery Departement of Fattouma Bourguiba University Hospital, Monastir, Tunisia

66 Surgery for Brain Metastases: Which Patients Gain the Greatest Survival Benefit ?

Majdouline Barkache, R.Benfredj, A.Affes, H.Kammoun ,I.kisra
Department of Neurosurgery, Sahloul Hospital, Sousse, Tunisia

67 Glioblastoma in the Elderly : Who Benefits From Aggressive Treatment ?

Majdouline Barkache, R.Ben fredj, H. Kmmoun, A. Hmida, I. Kisra
Department of Neurosurgery, Sahloul Hospital, Sousse, Tunisia

68 Gamma Knife Radiosurgery Role in the Management of Brain Stem Cavernous Angiomas

Essam Eldein AbdelKawy, Ahmed Ragab AbdelSalam, M.Sc., Ayman Abd Elraouf Abd Elghafar Elshazly MD Ahmed Faisal Tobar MD, Ahmad Mohamed Abd Raheim Elsabaa MD, Sameh Roshdy Tawadros MD
Department of Neurosurgery, Faculty of Medicine, Ain Shams University, Egypt.

69 Acute Spinal Cord Injury Management Integrating Evidence, Guidelines, and Controversies

Riadh Rebai, --
King Fahd hospital, Second health cluster, Jeddah; kSA

70 Penetrating Traumatic Adult Brain Injury in the North of Palestine : Analysis of 380 cases at one year post injury

Mazhar Darwazeh, Rami Darwazeh
Specialized Arab Hospital (SAH) - Nablus - Palestine

71 Low cost personalized cranioplasty for post traumatic cranial defects using a desktop 3D printer : a 30 patient series.

Sofiane IMEKRAZ, S. FARFAR , M. BOUAZIZ
Faculty of Medicine of Annaba. Neurosurgery Department. Annaba University Hospital. Algeria

72 Operated Thoracolumbar Spine Trauma: Epidemiological and Outcome Profile in the Neurosurgery Department of Oujda University Hospital

Mohammed Al amine El Farissi, Mohamed Dahamou, Hamid Khay, Khoulali Mohamed.
Department of Neurosurgery, Mohammed VI University Hospital, Faculty of Medicine and Pharmacy of Oujda, Mohammed First University, Oujda, Morocco.

73 MANAGEMENT OF PENETRATING TRANSFIXING TRAUMATIC BRAIN INJURY AT THE OUAHIGOUYA REGIONAL UNIVERSITY HOSPITAL (BURKINA FASO)

Wendlasida Serge Pacôme Arnauld YAMEOGO, YAMEOGO Wendlasida Serge Pacôme Arnauld1 ZONGO Adama2, BIOGO Wend-toin Joseph1, PASGO Ismael3, CONGO Judicael4, TAPSOBA Franck William2 SAWADOGO Benjamin1, MEHOUNO Martine1, ZABSONRE Denlewende Sylvain5.
1. Neurosurgery Department of the Ouahigouya Regional University Hospital, BURKINA FASO
2. Anesthesia and Intensive Care Unit of the Ouahigouya Regional University Hospital, BURKINA FASO
3. Pediatric Surgery Department of the Ouahigouya Regional University Hospital, BURKINA FASO
4. Medical Imaging Department of the Ouahigouya Regional University Hospital, BURKINA FASO
5. Neurosurgery Department of the Yalgado OUEDRAOGO University Hospital, BURKINA FASO

74 To Drill or Not to Drill: ICP Monitoring versus Transcranial Doppler in the Surveillance of Comatose TBI Patients

Maryem Khayat, Affes A, Akrout F, Rachdi MA, Bouzouita K, Chkili R, Radhouen K
Neurosurgery Department, Military Hospital of Tunis, Tunis, Tunisia

75 MRI Predictors of Neurological Recovery After Subaxial Cervical Spine Trauma

Mohamed Amine Hmida, K.Maamri, R.BenMhenni, M.AliKhelifa, K.Bouattour, M.Darmoul
Neurosurgery Department, Fattouma Bourguiba University Hospital of Monastir, Tunisia

76 Awake but Safe: Patient Selection and Psychological Preparation for Awake Craniotomy

AMEUR AFFES, Rachdi M.A., Hdhili H, Bouzouita K, Achoura S, Chkili Ridha, Radhouen K.
Neurosurgery Department, Military Hospital of Tunis, Tunis, Tunisia

77 How Much Is Enough? Balancing Oncological Radicality and Functional Preservation in Awake Craniotomy for Glioma

AMEUR AFFES, Rachdi M.A., Hdhili H, Bouzouita K, Achoura S, Chkili Ridha, Radhouen K.
Neurosurgery Department, Military Hospital of Tunis, Tunis, Tunisia

78 High-Grade Intracranial Meningiomas: A 10-Year Retrospective Study of 50 Cases

O. JAMAL, A. JEHRI, A. LAIDI, K. GUETTABI, M. MAKHCHOUNE, K. IBAHIOUINE, A. NAJA, A. LAKHDAR.
Department of Neurosurgery at the Ibn Rochd University Hospital Center in Casablanca Laboratory for Diseases of the Nervous System Sensory Nerves, and Disabilities

79 Spinal Epidural Hemangioma : A Series of 15 Cases

A. Jehri[1,2], O. Jamal[1,2], K. El Gheuttabi[1,2], K. Ibahioin[1,2], S. Hilmani[1,2], A. Lakhdar[1,2]
1 Department of Neurosurgery, Ibn Rochd University Hospital, Casablanca, Morocco
2 Laboratory for Diseases of the Nervous System, Sensory Nerves, and Disabilities

10:00 – 12:30

PLENARY SESSION VII

Oncology, Epilepsy & Endoscopy

Les Jasmins Hall

Moderators : Moujahid Labidi, Mohamed Badri, Mohamed Ladib, Souhil Tliba, Ahmed Ali Morsy, Ghanem Alsulaity

10:00 Glioma Surgery Through and Fro From Highest Equipped Centers to Lowest Ones
Sameh El Morsy Hassen (Egypt)

10:15 Glioma Surgery : Awake Craniotomy is Not a Luxury
Sadok Ben Amor (Tunisia)

10:30 Designing an Epilepsy Surgery Program : The Sfax Experience
Fatma Kolsi (Sfax, Tunisia)

10:45 Mesial Temporal Lobe Epilepsy Surgery : Our Initial Experience and Results
Hichem Ammar | Ines Cherif (Military Hospital, Sfax, Tunisia)

11:00 Role of Endoscope in Brain Stem Surgery
Ali Ayed (Jordan)

11:15 Endoscopic Transorbital Surgery : Indications and Technique
Moujahid Labidi (Montreal)

11:30 Why Go Through the Nose ? Rethinking Pituitary Surgery
Souhil Tliba (Algeria)

11:45 Endoscopic Endonasal Management of GH-Secreting Pituitary Adenomas : From Surgical Strategy to Endocrine Remission
Mohamed Badri (Tunisia)

12:00 Decompressive Craniectomy in Malignant Stroke : Current Evidence and Guidelines
Brahim Kammoun (Tunisia)

12:30 – 12:45

CLOSING EVENT

Awards Ceremony

Awards for the best resident presentations.

CLOSING

End of the Congress

12:45

unimed
Laboratoires مخابر

ARA mez MEDICAL

Official Partners





الجمهورية التونسية
République Tunisienne
وزارة الصحة
Ministère de la Santé

الجمعية التونسية لجراحة الجهاز العصبي
ASSOCIATION TUNISIENNE DE NEUROCHIRURGIE

Pan Arab Neurosurgical Society
الجمعية العربية للجراحة العصبية

15th PANARAB NEUROSURGICAL SOCIETY CONFERENCE

39th Congress of the Tunisian Association of Neurosurgery

November 6th – 8th 2026

Russelior Hotel - Yasmine Hammamet - TUNISIA



Oral Presentations

O1 - Comparative clinical outcomes and safety of endoscopic TLIF versus minimally invasive TLIF in degenerative lumbar spine disease:a systematic review and meta-analysis

Oral I

Abdelrahman Alitr

Global Neurosurgical Students Council

Background: Endoscopic transforaminal lumbar interbody fusion (Endo-TLIF) has emerged as an alternative to minimally invasive transforaminal lumbar interbody fusion (MIS-TLIF) for degenerative lumbar spine disease (DLSD), but comparative evidence remains inconsistent.

Objective: To compare the clinical outcomes and safety of Endo-TLIF versus MIS-TLIF in patients undergoing surgery for DLSD.

Methods: A systematic review and meta-analysis was conducted according to PRISMA guidelines. PubMed, Scopus, and the Cochrane Library were searched for English-language human studies published between 2020 and 2025 comparing Endo-TLIF with MIS-TLIF in DLSD. Eligible studies reported at least one of the following outcomes: operative time, estimated blood loss, length of hospital stay, fusion rate, complications, Visual Analog Scale, or Oswestry Disability Index. Random-effects meta-analysis was performed using mean differences (MDs) for continuous outcomes and odds ratios (ORs) for dichotomous outcomes, each with 95% confidence intervals (CIs). Risk of bias was assessed using the Newcastle-Ottawa Scale and RoB 2, and the review protocol was registered in PROSPERO (CRD420261341025).

Results: Twelve studies were included. Operative time was longer with Endo-TLIF, but not significantly (MD 13.71 minutes, 95% CI -10.01 to 37.44; p=0.257). Estimated blood loss was lower with Endo-TLIF, though not significantly (MD -34.09 mL, 95% CI -82.17 to 13.99; p=0.165). Length of stay was also slightly shorter without significance (MD -0.43 days, 95% CI -1.84 to 0.98; p=0.553). Complication rates were comparable between groups (OR 0.69, 95% CI 0.41 to 1.17; p=0.171). Clinical and fusion outcomes were qualitatively similar.

Conclusions: Endo-TLIF and MIS-TLIF show comparable safety and effectiveness for DLSD. Larger high-quality studies are needed to clarify whether Endo-TLIF offers meaningful clinical advantages.

O2 - Management of degenerative cervical myelopathy: our experience

Oral I

Mechiche Zohir, Messai Saddem, Mahdaoui Rima, Hallaci Azzedine

Neurosurgery Department - CHU SETIF - ALGERIA

Introduction: Degenerative cervical myelopathy is a clinical syndrome related to the narrowing of the spinal canal, with cervical spondylosis and cervical disc herniation being the primary etiologies. Treatment aims to restore the dimensions of the cervical spinal canal and achieve neural decompression. Neurosurgical techniques are diverse; the choice of the surgical technique is guided by the analysis of preoperative clinical signs and imaging, determining whether an anterior, posterior, or, exceptionally, a combined approach will be performed.

Materials and methods: A retrospective study was conducted between 2014 and 2024, involving 160 patients operated on in our department. Data collection was based on patient medical records (pre- and postoperative clinical evaluations) and imaging (pre- and postoperative X-rays, CT scans, and MRI).

Results: A total of 160 patients were included in our study: 96 males (60%) and 64 females (40%), with a mean age of 54 years. Patients presented with various symptoms, including cervicobrachial neuralgia, limb heaviness, and sphincter dysfunction. An anterior approach was performed in 128 patients (80%), consisting of a discectomy with cage or bone graft placement, with or without plating. Twenty patients (12.5%) were operated on via a posterior approach (1- to 3-level laminectomy), and 12 patients (7.5%) underwent a combined approach. The overall outcome of our patients was favorable in 87.5% of cases, stationary in 8.75%, worsened in 2.5%, with a mortality rate of 1.25%.

Discussion: The objective of surgery is to relieve the compression of the spinal cord and nerve roots while maintaining spinal stability. The choice of the surgical approach is made on a case-by-case basis and must consider several factors. In the literature, there have been controversial opinions regarding the optimal surgical approach.

Conclusion: Myelopathy is a common pathology in neurosurgical practice. Surgical intervention remains the most effective strategy in the management of degenerative cervical myelopathy. Various surgical approaches are utilized based on clinical and radiological data, and patient outcomes remain highly favorable when management is initiated early.

O3 - Outcome and accuracy of posterior craniovertebral junction fixation techniques: a cohort prospective study of 44 cases.

Oral I

Selmane Toufik, Z.Abdellaoui, Z.Fellag, D.Dergham, A.Meliani, A.Mati, K.Bouaita

Neurosurgical specialized hospital, Cherchell, wilaya of TIPAZA 42002, ALGERIA

Background: Posterior fixation techniques for the craniovertebral junction can be indicated for many causes of instability. However, the anatomic variations, the bony malformations and deformations in addition to vascular relationship to C0-C1-C2 region make a successful and accurate fixation difficult to achieve when compared to the ideal goal of surgery.

Methods: A prospective cohort study of 44 cases presenting with different causes of instability of occipito-C1-C2 complex was conducted between June 2021 and June 2026. Posterior fixation techniques were optimised for every case. All patients of different age were included. Traumatic, congenital and tumoral causes were included. Patient's outcome and complications were assessed post operatively along with the accuracy of screw placement which was evaluated between the ideal screw placement during planification and the final screw placement on post operative Ct scan. all fixation procedures were done without navigation tools.

Results: The age of our patients ranges from 7 to 75 years old. Three types of fixations were used: The Harms-Goel technique was adopted in 61.3% | The Wright technique was adopted in 13.6% | Screw-plate Occipitocervical fixation was adopted in 25 %. The rate of Per operative dural breach = 4.5% (02 cases), the need for per operative transfusion = 2.2% (01 case), Per operative vertebral artery injury = 01 case, post operative tracheostomy 4,5 % (02 cases). Screw placement accuracy = 94%. Mild Post operative neurological worsening = 2.2% (01 case), Objective Long term neurological improvement = 63,6%, Long term neurological stability = 34%. Fatigue failure = 4,5 % (02 cases) Instrumentation failure = 2,2% (01 case) | Infectious complications = 0 | Operative mortality =0 | Revision surgery = 01 case

Conclusion: The posterior craniovertebral junction fixation techniques is a safe technique when performed with caution and valuable preoperative planning. Further per operative navigation techniques help achieve better long-term outcome for a diverse craniovertebral junction pathology.

O4 - Osteoporotic thoracolumbar vertebral fractures: a 10-year retrospective case series from a neurosurgical center

Oral I

Hamid Khay, Amine Kada, Mohamed Dahamou, Mohammed Al Amine El Farissi, Mohammed Khoulali

University hospital Center Mohammed VI Oujda, Morocco

Background: Osteoporosis is a progressive age-related skeletal disorder characterized by reduced bone mass and deterioration of bone microarchitecture, resulting in increased fracture risk. Vertebral compression fractures are among the most common and disabling complications, particularly in older adults, leading to chronic pain, spinal deformity, and functional impairment.

Methods: We conducted a retrospective study of 40 patients with osteoporotic thoracolumbar vertebral fractures managed in the Department of Neurosurgery at Mohammed VI University Hospital, Oujda, Morocco, over a 10-year period. Demographic characteristics, mechanisms of injury, clinical presentation, imaging findings, fracture classification, treatment strategies, and early outcomes were analyzed.

Results: The mean age was 62.5 years (range, 45–95 years), with a slight female predominance (51.7%). Low-energy trauma accounted for most fractures, with falls from standing height representing 37.9% of cases and stair falls 10.3%. Back pain was the predominant presenting symptom, whereas radicular pain, kyphotic deformity, and sphincter dysfunction were less frequent. Computed tomography was performed in all patients, while magnetic resonance imaging and bone mineral density assessment were obtained in selected cases. Most fractures (89.6%) involved the thoracolumbar junction (T11–L2), and 44.8% were classified as OF4 according to the Osteoporotic Fracture (OF) classification. Conservative management was the initial treatment in all patients and remained definitive in 24.1%, whereas 75.9% required surgery because of fracture severity, failure of conservative treatment, or neurological compromise. Surgical procedures included vertebroplasty, kyphoplasty, and open posterior fixation. Early outcomes demonstrated significant pain relief and functional recovery in 75.9% of patients.

Conclusion: This 10-year experience confirms that osteoporotic thoracolumbar fractures predominantly affect older adults following low-energy trauma and frequently involve the thoracolumbar junction. Management should be individualized according to fracture severity, neurological status, and patient characteristics. Early diagnosis and timely treatment are essential to optimize functional recovery and improve quality of life in this growing patient population.

O5 - Tubular endoscopy-assisted lumbar microdiscectomy using the easygo® system: a single-center case series of 31 patients

Oral I

Aziz Bedioui, S. Ben Zekri [2], G. Gader [1], S. Ben Yaacoub [1], M. Bounemra [2], Ma. Hermassi [1], M. Rkhami [1], M. Badri [1], K.Bahri [1], I. Zammel [1]

[1] Neurosurgery department, Center of traumatology and severe burns of Ben Arous, Tunisia
[2] Regional Hospital of Zaghouan, Tunisia

Introduction: The growing adoption of minimally invasive spine surgery has transformed the management of lumbar disc herniation. Endoscopic and endoscopy-assisted procedures have gained increasing popularity because of their potential benefits, including smaller incisions, reduced muscle injury, less postoperative pain, shorter hospital stay, and faster functional recovery. This study presents our initial experience with tubular endoscopy-assisted lumbar discectomy using the EasyGO® system (Karl Storz).

Materials and methods: A retrospective analysis was conducted on 31 consecutive patients who underwent tubular endoscopy-assisted lumbar discectomy using the EasyGO® system, from April 2025 to May 2026 . The cohort included 21 men and 10 women, with a mean age of 45 years. All patients presented with unilateral sciatica secondary to lumbar disc herniation. The L4–L5 level was involved in 24 cases, while the remaining cases affected other lumbar levels. Patients were followed clinically for one year. Clinical outcomes and postoperative complications were assessed.

Results: All 31 patients experienced significant postoperative improvement in radicular symptoms. Three patients (9.7%) required revision surgery because of recurrent or residual disc herniation. Dural tear occurred in three patients (9.7%). Conversion to open surgery happened in four cases (13%). One patient (3.2%) developed a postoperative surgical site infection, which was successfully managed. No major neurological complications were observed. At one-year follow-up, most patients demonstrated sustained clinical improvement with satisfactory outcomes, five patients reported neuropathic pain.

Conclusion: Tubular endoscopy-assisted lumbar discectomy using the EasyGO® system is a safe and effective minimally invasive technique for the treatment of lumbar disc herniation, providing excellent clinical outcomes with a low complication rate. Compared with uniportal and biportal full-endoscopic techniques, the tubular approach offers a shorter learning curve, familiar microsurgical instrumentation, while still minimizing soft tissue disruption. It therefore represents an attractive and reproducible minimally invasive alternative for spine surgeons transitioning from conventional microsurgery to endoscopic-assisted techniques.

O6 - Minimally invasive surgery for lumbar disc herniation: endoscopic discectomy versus tubular microdiscectomy

Oral I

Ines Cherif, Zohra Souei, Imen Dammak, Fares Ferjani, Hichem Ammar

Department of Neurosurgery, Sfax Military University Hospital, Tunisia

Introduction: Minimally invasive techniques, particularly endoscopic discectomy and tubular microdiscectomy, are widely used in the management of lumbar disc herniation. The aim of this study was to compare their clinical and perioperative outcomes.

Materials and methods: We conducted a comparative study in our Department of Neurosurgery over a five-month period. Included patients presented with symptomatic radicular pain confirmed by MRI after failure of conservative treatment. The assessed parameters were operative time, blood loss, length of hospital stay, visual analog scale (VAS), Oswestry Disability Index (ODI), MacNab score, complications, and surgical revisions.

Results: Thirty-eight patients were included and divided into two groups of 19 patients each. The mean operative time was shorter in the endoscopic group, 80.71 ± 29.01 minutes, compared with 119.67 ± 40.29 minutes in the tubular group. Blood loss was lower in the endoscopic group, 12.14 ± 4.69 cc versus 53.67 ± 23.64 cc. The median hospital stay was 3 days versus 4 days. The median postoperative VAS score was 0 versus 1. According to the MacNab criteria, the outcome was excellent in 15 patients after endoscopic discectomy and in 16 patients after tubular microdiscectomy. Two surgical revisions were required after endoscopic discectomy.

Conclusion: Endoscopic discectomy provides clinical outcomes comparable to those of the tubular approach, with less blood loss, shorter operative time, and a slightly reduced hospital stay.

O7 - Why do pedicle screws fail ? identifying predictors of instrumentation loosening after spine surgery

Oral I

Majdouline Barkache, R. Ben Fredj, A. Affes, A. Hmida, I.Ksira

Neurosurgery Department of Sahloul, Sousse - Tunisia

Background: Pedicle screw loosening remains a significant complication in spine surgery, leading to mechanical failure, pseudarthrosis, and the need for revision surgery. Understanding the factors associated with instrumentation failure is essential to improve surgical planning and outcomes. This study aims to identify potential predictors of pedicle screw loosening after spine surgery.

Methods: A retrospective analysis was conducted on 85 patients who underwent instrumented spine surgery between 2022 and 2024. Clinical, radiological, and surgical variables were reviewed, including age, sex, bone quality, diagnosis, number of fused levels, and presence of osteoporosis or vitamin D deficiency. Screw loosening was assessed using radiological criteria on follow-up imaging. Univariate and multivariate analyses were performed to identify independent risk factors.

Results: Pedicle screw loosening was observed in a relevant proportion of patients during follow-up. Higher rates of loosening were associated with poor bone quality, osteoporosis, multilevel fixation, and long-segment constructs. Patients with metabolic bone impairment, including vitamin D deficiency, showed increased incidence of instrumentation failure. On multivariate analysis, osteoporosis and multilevel fusion emerged as the strongest independent predictors of screw loosening. Age and low bone mineral density were also contributing factors, while surgical indication and approach were less significant.

Conclusion: Pedicle screw loosening is a multifactorial complication strongly influenced by bone quality and construct length. Osteoporosis and extensive fusion levels represent the main predictors of instrumentation failure. Optimization of bone health and careful surgical planning are essential to reduce mechanical complications after spine surgery.

O8 - Posterior-only occipito-cervical fixation with foramen magnum decompression for basilar invagination and craniovertebral junction malformations : a 20-patient series from algeria

Oral I

Dergham Djamel Eddine, D.Dergham, T. Selmane, A.Chabat, Z.Fellag, S.Benallag, K.Bouaita

Department of neurosurgery, neurosurgery hospital Cherchall, Algeria

Background: Basilar invagination (BI) is a complex craniovertebral junction malformation characterized by multifactorial mechanisms of neural compromise. Surgical management remains challenging and controversial, with multiple paradigms emerging in recent decades.

Aim: To evaluate the clinical and radiographic outcomes of posterior-only surgical management in patients with basilar invagination and craniovertebral junction malformations treated with occipitocervical fixation and posterior fossa decompression.

Methods: A retrospective descriptive analysis of 20 consecutive patients surgically treated for basilar invagination or craniovertebral junction malformations at the Neurosurgery Department of Cherchell Hospital between November 2022 and November 2025. All procedures employed a standardized posterior approach combining suboccipital craniectomy with foramen magnum enlargement and instrumented occipitocervical fixation using occipital plate-to-cervical screw-rod constructs. Patient demographics, clinical presentation, preoperative imaging characteristics, surgical techniques, postoperative complications, and clinical outcomes were systematically reviewed.

Results: The cohort included 20 patients (18 with basilar invagination, 2 with MCOV) who underwent surgical management. Chiari malformation was documented in 40% (8/20), and syringomyelia in 20% (4/20). All 20 patients underwent posterior-only surgery with suboccipital decompression and occipitocervical fixation (O-C2 or O-C3). Postoperative complications included one CSF fistula (5%, managed conservatively with lumbar punctures and acetazolamide). Mean length of stay was 4.6 ± 2.2 days. No patient required reoperation or secondary decompression. Neurological outcomes were favorable in 100% of patients with documented postoperative assessment (7/7; 95% CI 59–100%). The single patient who developed a postoperative CSF fistula (1/20; 5%) achieved favorable clinical resolution with conservative management, including subtractive lumbar punctures and acetazolamide. No patient experienced permanent neurological deterioration or required secondary decompression during follow-up.

Conclusion: Posterior-only surgical management combining rigid occipitocervical stabilization with systematic foramen magnum decompression provides safe and effective treatment for basilar invagination and complex craniovertebral junction malformations, achieving favorable clinical outcomes with minimal morbidity. This approach is appropriately aligned with contemporary WFNS consensus for anatomically complex cases and supports the view that multiple effective surgical paradigms exist, with phenotype guiding strategy selection.

O9 - Neuronavigation-guided C1–C2 fixation

Oral I

Nader Yahyaoui, Belkahla Ghassen, Mohamed Amine Hadj Taieb, Mohamed Maher Hadhri, Kais Maamri, Mehdi Darmoul.

Neurosurgery Department, Fattouma Bourguiba University hospital, Monastir, Tunisia.

Background: Posterior C1–C2 fixation remains the preferred surgical treatment for atlantoaxial instability. Nevertheless, instrumentation of the upper cervical spine is technically demanding because of the complex osseous anatomy and the close proximity of the vertebral artery and spinal cord. The use of intraoperative neuronavigation has gained increasing interest as a means of improving the precision of screw placement while reducing the risk of neurovascular complications.

Methods: Four consecutive patients underwent posterior C1–C2 fixation using intraoperative neuronavigation. The indications included atlantoaxial instability associated with Down syndrome , rheumatoid arthritis , a displaced odontoid fracture , and traumatic rupture of the transverse atlantal ligament . Preoperative CT imaging was used for surgical planning, and neuronavigation guided the insertion of C1 lateral mass and C2 pedicle screws according to the individual anatomy. Surgical feasibility, screw placement accuracy, perioperative complications, and early clinical outcomes were evaluated.

Results: Neuronavigation enabled successful instrumentation in all four patients. Accurate screw placement was achieved in every case without vertebral artery injury, neurological deterioration, or screw malposition. The technique proved particularly valuable in patients with altered anatomy related to Down syndrome and rheumatoid arthritis. Postoperative imaging confirmed satisfactory implant positioning ,no vertebral artery injury, neurological deterioration, or screw malposition was observed.

Conclusion: Neuronavigation provides a reliable adjunct for C1–C2 fixation by improving the accuracy of screw placement and enhancing the safety of the procedure, particularly in patients with complex upper cervical anatomy. Although further comparative studies are needed, our findings support the routine use of navigation in atlantoaxial stabilization when available.

O10 - Strategies and philosophy in the management of sciatic nerve injury

Oral I

Bassam Addas

King Fahd hospital, Second health cluster, Jeddah; KSA

The management of sciatic nerve injury is a major challenge in the field of peripheral nerve surgery. Obtaining a good results is not common and usually takes a long time during which most patient may go on for secondary procedures which may mask the results of the nerve repair. The author is presenting his personal experience in the management of these injuries which mainly includes penetrating injuries caused by gunshot wounds injury to the sciatic nerve. Different options of surgical repair will be presented in the presentation.

O11 - Uniportal transforaminal endoscopic surgery for foraminal and extraforaminal lumbar disc herniations: clinical outcomes and technical advantages

Oral I

Houssem Hdhili, M.D.Yedeas, T.Kamoun, H.Kammoun, S.Achoura, A.Harbaoui, R.Chkili, K.Radhouane

Department of Neurosurgery, Military Hospital of Tunis, Tunisia

Background: Foraminal and extraforaminal lumbar disc herniations account for approximately 7–12% of lumbar disc herniations. Their lateral location often causes severe radicular pain while posing significant diagnostic and surgical challenges. Conventional approaches frequently require extensive bone and soft tissue dissection to access these lesions. Uniportal transforaminal endoscopic discectomy has emerged as a minimally invasive alternative, providing direct access to the pathology while preserving normal anatomical structures. This study aimed to evaluate the clinical outcomes and safety of this technique.

Methods: We retrospectively reviewed patients who underwent uniportal transforaminal endoscopic surgery for foraminal or extraforaminal lumbar disc herniation between April and December 2025. Demographic characteristics, affected spinal level, operative time, complications, and clinical outcomes were analyzed. Pain and functional status were assessed using the Visual Analog Scale (VAS) and Oswestry Disability Index (ODI) preoperatively, immediately after surgery, and at 3- and 6-month follow-up.

Results: Eighteen patients were included, with a mean age of 50 years. Herniations involved L3–L4 in five patients, L4–L5 in eleven, and L5–S1 in two. The transforaminal endoscopic approach was successfully performed in all cases. Mean operative time was 50 ± 20 minutes. Mean VAS improved from 8.1 preoperatively to 2.3 at 3 months and 1.6 at 6 months, while ODI decreased from 62% to 18% at final follow-up. Complications were uncommon and included one case of transient postoperative dysesthesia following prolonged surgery, one early recurrence requiring revision surgery, and one postoperative infection in a diabetic patient. No permanent neurological deficits were observed.

Conclusion: Uniportal transforaminal endoscopic surgery is a safe and effective treatment for foraminal and extraforaminal lumbar disc herniations. It provides targeted neural decompression with excellent clinical outcomes, low morbidity, and rapid recovery, making it an attractive minimally invasive alternative to conventional surgery for these challenging lesions.

O12 - Pretemporal transcavernous anterior petrosal approach for large petroclival meningiomas

Oral II

Lassaad Bsili, Ahmed Maatoug
OLIVIER CLINIC, SOUSSE, TUNISIA

Background: Pituitary macroadenomas invading the cavernous sinus remain a surgical challenge because of their intimate relationship with critical neurovascular structures. While endoscopic endonasal approaches are widely used, selected cases may benefit from transcranial routes that provide direct access to the lateral compartment of the cavernous sinus.

Objective: To demonstrate the surgical nuances and outcomes of the pretemporal transcavernous approach in the management of pituitary macroadenomas with significant cavernous sinus invasion through a video presentation of two illustrative cases.

Methods: Two patients harboring large pituitary macroadenomas with extensive cavernous sinus invasion underwent microsurgical resection via a pretemporal transcavernous approach. Preoperative imaging, surgical technique, anatomical landmarks, extent of resection, and postoperative outcomes were analyzed and highlighted in the video.

Results: The pretemporal transcavernous approach provided adequate exposure of the parasellar region and cavernous sinus, allowing safe tumor debulking and resection under direct visualization. Gross-total or near-total resection was achieved while preserving the internal carotid artery and cranial nerves traversing the cavernous sinus. Both patients experienced favorable postoperative outcomes with improvement of presenting symptoms and no permanent new neurological deficits.

Conclusion: The pretemporal transcavernous approach is a valuable option for selected pituitary macroadenomas with substantial cavernous sinus invasion. It offers wide surgical exposure, facilitates tumor removal from the cavernous sinus, and enables preservation of critical neurovascular structures. The presented video illustrates the key operative steps, technical pearls, and anatomical considerations of this approach.

O13 - Challenges in the surgical management of intrasellar and suprasellar neuroendocrine tumors

Oral II

Belgacem Ibrahim, Chahed Mbarek, Si Tayeb Fatima Zohra, Djouadi Yasmine, Aboudjabel Mohamed, Maameri Lila, Ait Bachir Mustapha

Department of Neurosurgery, CHU Nedir Mohamed, Tizi Ouzou, Algeria

Introduction: The surgical treatment of intrasellar and suprasellar neuroendocrine tumors remains a significant challenge despite substantial advances in neuroimaging, microsurgical techniques, endoscopic procedures, and the biological understanding of these lesions. Their intimate relationship with the optic apparatus, pituitary gland, cavernous sinus, and major intracranial vessels makes surgical planning particularly demanding. Several operative routes are available, including the endoscopic endonasal approach, unilateral or bilateral subfrontal approaches, interhemispheric approaches, and the classical pterional transsylvian route. The selection of the optimal surgical strategy remains one of the most difficult decisions for contemporary neurosurgeons. Tumor volume, extension, vascular encasement, distance from the optic chiasm, and especially tumor consistency are major factors influencing surgical resectability and outcomes.

Patients and methods: We retrospectively reviewed a series of 700 patients operated on between 2004 and 2023 for intrasellar tumors with suprasellar extension or clival lesions extending into the sellar region. Patients ranged in age from 8 to 60 years, with a predominance of female patients. All patients underwent preoperative neuroradiological assessment using computed tomography (CT) and/or magnetic resonance imaging (MRI). The most commonly employed surgical approaches were the transcranial (high route) and endoscopic endonasal (low route) approaches.

Results: The most frequent postoperative complications included nasal mucosal dryness, transient disturbances of smell and taste, epistaxis, cerebrospinal fluid leakage, sinusitis, meningitis, neurogenic diabetes insipidus, delayed hyponatremia, and visual deterioration. Cosmetic sequelae were uncommon and generally transient. Total anterior pituitary insufficiency was exceptionally rare and occurred mainly after resection of large macroadenomas. Seizures were infrequently observed. Most complications were successfully managed with appropriate medical or surgical treatment.

Conclusion: Tumor consistency, size, anatomical location, and extension are the principal determinants of surgical difficulty and extent of resection. Careful selection of the surgical approach is crucial to maximize tumor removal while minimizing morbidity. Successful outcomes depend on a thorough preoperative evaluation, meticulous surgical planning, and the surgeon's experience.

O14 - Visual outcomes following surgical resection of tuberculum sellae meningiomas: a retrospective analysis

Oral II

Kamel Bouaita, S. Benallag, T. Selmane, A.Mati, N.Baz

Neurosurgery departement EHS Cherchell, Blida Faculty of medecine, Algeria

Background: Tuberculum sellae meningiomas are benign skull base tumors arising from the tuberculum sellae, limbus sphenoidale, and chiasmatic sulcus. Due to their intimate relationship with the optic nerves, optic chiasm, and surrounding neurovascular structures, visual impairment is often the presenting symptom. Preservation and improvement of visual function represent the primary goals of surgical treatment.

Methods: We conducted a retrospective study of patients who underwent microsurgical resection of tuberculum sellae meningiomas. Clinical presentation, preoperative visual status, radiological findings, extent of resection, and postoperative visual outcomes were analyzed. Visual function was assessed through ophthalmological examination, including visual acuity and visual field evaluation, before and after surgery. Factors associated with visual recovery were also investigated.

Results: Visual impairment was the most common presenting symptom, ranging from decreased visual acuity to visual field defects and, in advanced cases, severe visual loss. Gross total resection was achieved in the majority of patients while preserving the integrity of the optic apparatus. Postoperatively, visual improvement was observed in most patients, whereas visual function remained stable in a smaller proportion. A limited number of patients experienced visual deterioration. Favorable visual outcomes were associated with shorter duration of symptoms, better preoperative visual status, smaller tumor size, and early surgical intervention. Complete decompression of the optic nerves and optic canal, when involved, contributed significantly to visual recovery.

Conclusion: Microsurgical resection of tuberculum sellae meningiomas is an effective treatment for visual dysfunction caused by optic pathway compression. Early diagnosis and timely surgical intervention maximize the chances of visual recovery while minimizing the risk of postoperative deterioration. Visual outcomes remain a key indicator of surgical success in the management of these challenging skull base tumors.

O15 - Hearing preservation microsurgery for vestibular schwannomas using the subperineurial plane: a contemporary surgical case series

Oral II

Ala Belhaj, Joe Saliba, Moujahed Labidi

[1]Division of Neurosurgery, Department of Surgery, Centre Hospitalier de l'Université de Montréal (CHUM), Montréal, Quebec, Canada

[2]Division of Oto-rhino-laryngology, Department of Surgery, Centre Hospitalier de l'Université de Montréal (CHUM), Montréal, Quebec, Canada

[3]Centre de Recherche du CHUM, Montréal, Quebec, Canada

Background: Hearing preservation remains a key goal in the management of small to medium-sized vestibular schwannomas (VS) in patients with serviceable hearing. The retrosigmoid (RS) and middle cranial fossa (MCF) approaches each offer distinct advantages. We present our contemporary multidisciplinary experience focused on hearing preservation based on a subperineurial dissection technique that allows identification and anatomical preservation of the facial and cochlear nerves.

Methods: A retrospective review was conducted of 11 consecutive patients with sporadic VS who underwent hearing-preservation microsurgery at our institution between January 1st, 2021 and June 15th, 2026. Inclusion criteria were preoperative AAO-HNS class A or B hearing and vestibular schwannoma amenable to surgical resection. The RS approach was favored in all but one case in which a MCF approach was used. All cases involved a neurosurgery-neurotology team, with intraoperative facial nerve monitoring and brainstem auditory evoked potentials monitoring. Outcomes assessed included extent of resection, hearing preservation rate, facial nerve function, and complications.

Results: 11 patients were included with 8 men and 3 women with a mean age of 47 years. 1 patient underwent an MCF approach and 10 underwent an RS approach. Mean tumor size was 2.2 cm. Serviceable hearing (class A or B) was preserved in 72% of patients. Gross total resection was achieved in 7 cases; near-total resection was intentionally performed in 4 cases to protect cochlear nerve integrity. There was 1 postoperative CSF leak via a perforated tympanum managed conservatively without reoperation. ! patient had subcutaneous abscess that required surgical revision and plate removal. Facial nerve function was preserved (House-Brackmann (HB) grade I–II) in 10 patients and the sole case of facial nerve palsy (HB 3) completely resolved at 6 months (HB 1). No other permanent morbidity occurred.

Conclusions: In this series, hearing preservation microsurgery for VS yielded favorable auditory and facial nerve outcomes with a low complication rate. Perineurial preservation, multidisciplinary collaboration, and intraoperative neuromonitoring were found to be helpful in optimizing hearing outcomes while achieving maximal resection. These findings support microsurgery as a viable strategy for hearing preservation in appropriately selected VS patients.

O16 - Endoscopic transorbital approach for a diverse spectrum of skull base lesions: the CHUM montreal experience

Oral II

Ala Belhaj, Erika Masicotte, Moujahed Labidi

[1]Division of Neurosurgery, Department of Surgery, Centre Hospitalier de l'Université de Montréal (CHUM), Montréal, Quebec, Canada

[2]Division of Ophthalmology, Centre Hospitalier de l'Université de Montréal (CHUM), Montréal, Quebec, Canada

[3]Centre de Recherche du CHUM, Montréal, Quebec, Canada

Background: The endoscopic transorbital approach (ETOA) is gaining traction as a minimally invasive corridor to the anterior and middle skull base. While its anatomical foundations are well described, clinical series documenting its versatility across diverse pathologies remain limited. We present our multidisciplinary experience with ETOA for a heterogeneous series of lesions.

Methods: A retrospective review was conducted of all consecutive patients who underwent ETOA at our institution between August 1st, 2024 and May 31st, 2026. All procedures were performed jointly by neurosurgery and oculoplastics, employing image-guided neuronavigation and intraoperative neurophysiological monitoring (electromyography) when appropriate. Data on operative technique, extent of resection, visual outcomes, complications, and length of stay were collected.

Results: 15 patients were included, 9 men and 6 women, with a mean age of 58 years. Pathologies included 5 meningiomas, 3 schwannomas, 4 secondary lesions, 1 lymphoma and 1 spontaneous cerebrospinal (CSF) leak of the lateral sphenoidal wall, and 1 dural arteriovenous fistula (dAVF).The transorbital corridor (superior eyelid or precaruncular) provided adequate surgical access in all cases. Gross total resection was achieved in meningiomas, schwannomas, and the cavernous hemangioma where intended (7 gross total resection (GTR) and 4 subtotal resection (STR)); diagnostic biopsy of cavernous sinus malignancy wielded a diagnosis in 2 cases, there was no recurrence of the CSF leak in the case of sphenoidal wall defect and the dAVF was successfully obliterated. Visual function remained stable or improved in the majority of patients; transient diplopia occurred in a minority and resolved spontaneously within weeks. There were no instances of postoperative cerebrospinal fluid leak, meningitis, permanent cranial nerve deficit, or cosmetic deformity. Mean length of stay was short, and no patient required reoperation.

Conclusions: The endoscopic transorbital approach is a versatile and safe strategy for a wide range of skull base pathologies, extending beyond traditional indications to include intra-axial and vascular lesions. Multidisciplinary collaboration, neuronavigation, and intraoperative monitoring are key to optimizing outcomes. This series supports the inclusion of ETOA in the modern skull base surgeon's armamentarium.

O17 - Resection of the cavernous sinus medial wall for corticotroph and somatotroph adenomas

Oral II

Ala Belhaj, Axel Eluid Renteria, Philippe Lavigne, Moujahed Labidi

[1]Division of Neurosurgery, Department of Surgery, Centre Hospitalier de l'Université de Montréal (CHUM), Montréal, Quebec, Canada

[2]Division of Oto-rhino-laryngology, Department of Surgery, Centre Hospitalier de l'Université de Montréal (CHUM), Montréal, Quebec, Canada

[3]Centre de Recherche du CHUM, Montréal, Quebec, Canada

Background: Pituitary adenomas infiltrating the cavernous sinus pose a surgical challenge, particularly in functioning tumors where biochemical remission depends on complete resection. Resection of the cavernous sinus medial wall has emerged as an adjonctive technique that may enhance extent of resection and endocrine outcomes. We present our multidisciplinary experience with cavernous sinus medial wall resection in Cushing's disease and acromegaly, and ongoing efforts to identify predictive factors for cavernous sinus invasion.

Methods: A retrospective review was conducted of consecutive patients with corticotroph adenomas and somatotroph adenomas (who underwent endoscopic endonasal resection of their adenoma in our institution between July 2018 and June 2026. Preoperative Knosp grading, extent of resection, early/late biochemical remission, and complications were analyzed. Clinical, radiological, and biochemical factors potentially predicting histological invasion of the cavernous sinus medial wall are being evaluated. All procedures were performed by a dedicated skull base team using neuronavigation, intraoperative Doppler ultrasound, and selective neurophysiological monitoring.

Results (preliminary): A total of 86 patients were included, 55 men and 31 women, with a mean age of 51 years. 44 adenomas were corticotroph and 42 were somatotroph. Resection of the cavernous sinus medial wall was performed based on radiological suspicion of invasion or intraoperative findings in a significant proportion of cases. Histological infiltration of the medial wall was confirmed in a substantial proportion of specimens, even in Knosp grade 0 to 3A tumors. Gross total resection was achieved in the majority of patients with lower-grade cavernous sinus involvement. Early biochemical remission rates were high for both Cushing's disease and acromegaly in Knosp 0 to 3A subgroups, and remained meaningful in selected Knosp 3B to 4 tumors. Complications were uncommon: only one patient presented a transient diplopia but she had no limitation of extraocular movements (no new cranial nerve palsy), there was no postoperative cerebrospinal fluid leak in this surgical series.

Conclusions: Endoscopic resection of the cavernous sinus medial wall is a safe, technically feasible strategy that may improve biochemical control in invasive functioning pituitary adenomas. Appropriate patient selection, advanced surgical expertise, and intraoperative adjuncts are essential. Our ongoing analysis of factors predicting invasion of the cavernous sinus medial wall aims to refine selection criteria and further optimize outcomes. Long-term follow-up continues to assess sustained remission.

O18 - Cystic craniopharyngiomas in the elderly: neurosurgical aspects, diagnostic criteria , and management specificities

Oral II

Talel Kamoun, Khaled Radhouane, Amine Rachdi, Houssem Hedhili, Mohamed Dahmeni Yedeas, Ridha Chkili

Neurosurgery Department, Military Hospital of Tunis, Tunis, Tunisia

Craniopharyngiomas (CPs) are low-grade benign epithelial tumors (WHO Grade 1) arising from embryonic remnants of Rathke's pouch. Although histologically benign, they are characterized by an aggressive biological behavior, a perilous anatomical location in close proximity to critical neurovascular structures, and a frequently severe functional prognosis. Consequently, they represent one of the most complex intracranial pathologies in modern neurosurgery. We report a clinical series of three elderly patients aged 67, 71, and 75 years, who presented with an insidious onset of symptoms. The classical triad was variably expressed: frontal-type cognitive decline and progressive visual loss (Case 1); a frank increased intracranial pressure (ICP) syndrome with bitemporal hemianopsia (Case 2); and severe fatigue, somnolence, and profound hyponatremia (122 mmol/L) signaling panhypopituitarism (Case 3). Diagnosis was established using computed tomography (CT) and magnetic resonance imaging (MRI) based on core radiological criteria: a predominant cystic component with heterogeneous T1/T2 signals, nodular or ring-like wall enhancement, and wall calcifications. Patients underwent either an endoscopic transsphenoidal approach or a pterional minicraniotomy tailored to limit hypothalamic injury. In elderly patients, CPs can deceptively mimic cystic or necrotic pituitary macroadenomas. Preoperative mapping must accurately detail vascular displacement and third ventricle floor distortion. Modern surgical targets have shifted from aggressive gross total resection to maximal visual pathway decompression while strictly preserving hypothalamic integrity, guided by the preoperative Puget classification. Given the intrinsic fragility of a multi-morbid geriatric population, subtotal resection or simple cyst fenestration—combined when necessary with adjuvant stereotactic radiotherapy or an Ommaya reservoir—constitutes the safest therapeutic approach, prioritizing quality of life over the dogma of radical excision.

O19 - Facial nerve preservation in cerebellopontine angle surgery: outcomes, determinants, and the role of intraoperative monitoring

Oral II

Kamel Bouaita, S. Benallag, T. Selmane, A. Mati, A. Meliani

Neurosurgery departement EHS Cherchell, Blida Faculty of medecine, Algeria

Background: Preservation of facial nerve function is a key objective in cerebellopontine angle (CPA) surgery. Despite advances in microsurgical techniques, postoperative facial nerve dysfunction remains a relevant concern due to the complex neurovascular anatomy and variable tumor- nerve interface. This study evaluates facial nerve outcomes and analyzes the main factors influencing postoperative function, with emphasis on the role of intraoperative neurophysiological monitoring.

Methods: A retrospective analysis was conducted on patients undergoing microsurgical resection of cerebellopontine angle lesions, including vestibular schwannomas, meningiomas, and epidermoid cysts, through standard skull base approaches. Facial nerve function was assessed pre and postoperatively using the House–Brackmann grading system. Data collected included tumor size, degree of nerve adhesion, consistency of the lesion, preoperative neurological status, extent of resection, and use of intraoperative neuromonitoring (NIM), including facial nerve electromyography and stimulation mapping.

Results: Overall, favorable facial nerve outcomes were achieved in the majority of cases. Postoperative function was strongly influenced by tumor size, degree of arachnoid plane preservation, and intraoperative nerve adhesion. Lesions with well-defined cleavage planes were associated with near-complete functional preservation, whereas firm adherence or nerve encasement increased the risk of transient or permanent dysfunction. The use of intraoperative NIM contributed to improved nerve identification, real-time feedback during dissection, and early detection of nerve stress, allowing adjustment of surgical strategy. Most postoperative deficits, when present, improved during follow-up.

Conclusion: Facial nerve preservation in CPA surgery is multifactorial and depends primarily on anatomical relationships, tumor characteristics, and surgical technique. Intraoperative neurophysiological monitoring plays a crucial role in optimizing functional outcomes by enhancing nerve visualization and guiding safe dissection. A meticulous microsurgical strategy combined with systematic use of NIM allows maximal safe resection while minimizing facial nerve morbidity.

O20 - Vestibular schwannoma : a multicenter study of 129 cases

Oral II

Emna Elouni, Haifa Mechergui, Salim Bachraoui, Roua Latrach, Khalil Ghedira, Sofiene Bouali, Jalel Kallel

Neurosurgery Departement, National Institute of Neurology, Tunis, Tunisia

Background: Vestibular schwannomas (VS) are the most common cerebellopontine angle tumors accounting for 75% of all lesions in this location. The controversy in management lies in the choice of therapeutic modality. The aim of our study was to evaluate the epidemiological, clinical, radiological, and therapeutic aspects of VS and to identify the prognostic factors of its management.

Methods: A retrospective cohort study was conducted over an 11-year period, including 129 patients who were managed in all neurosurgical departments across Tunisia. Data on patient and tumor characteristics, quality of resection , and postoperative clinical factors were collected in this study. A statistical analysis was conducted to investigate the predictive factors for facial nerve (FN) outcomes.

Results: The average age of the patients was 48.2 years, with a male-to-female ratio of 0.46. Unilateral hearing loss was present in 94 % of cases. According to the Koos classification, 2.3 % of patients were grade I, 4.7 % were grade II, 23.3 % were grade III, and 69.8 % were grade IV . Observation was performed in 10 % of cases. In this group of patients, the average tumor growth rate was 2.3 mm/year. Observation was interrupted in 38.4 % of cases. Microsurgical resection was performed in 93.7 % of cases. The retrosigmoid approach was employed in 90 % of cases, while the translabyrinthine approach was performed in 9.1 % of cases. Intraoperative monitoring was utilized in 28.1 % of cases. Total removal was achieved in 77 % of cases. A near-total resection was obtained in 12 % of cases, and a subtotal in 11 % of cases. A postoperative FN palsy was present in 64 % of cases. We identified tumor size, cystic appearance, use of intraoperative FN monitoring, degree of adherence between the FN and the tumor capsule, and quality of resection as independent predictive factors for FN outcomes($p<0,05$). Postoperative tumor regrowth was observed in 7.4 % of cases.

Conclusion: Our study demonstrated that the management of VS is individualized and depends on tumor size, age of patient, hearing status, lesion consistency, degree of adhesion as well as the surgeon’s experience. The main prognostic factors are tumor size and quality of resection.

O21 - Multidisciplinary management of craniopharyngioma: a single-center experience

Oral II

Sara Dellaldja, A.Terrak[2]; Ch.Zair[3]; W.Moudjer[4]; R.Chetaibi[4]; L.Atroune[5]

ESH ALI AIT AIDIR, ALGIERS, ALGERIA

Background: Craniopharyngioma is a benign sellar tumor associated with significant neurological, visual, and endocrine morbidity due to its close relationship with the optic apparatus, hypothalamus, and pituitary stalk. Optimal management requires a multidisciplinary approach to minimize complications and improve long-term outcomes.

Methods: We conducted a retrospective study of patients treated for craniopharyngioma in the Department of Neurosurgery at EHS Ali Ait Idir between 2021 and 2025. Among 24 operated patients, 19 with complete medical records were included. Postoperative complications and clinical outcomes were analyzed to assess the impact of multidisciplinary management.

Results: Neuroendocrine disorders were the most frequent postoperative complications. Central diabetes insipidus occurred in 80% of patients, while thyrotropic and corticotropic insufficiency were observed in 80% and 85% of cases, respectively. Hypothalamic obesity developed in 10% of patients, mainly in the pediatric population. Postoperative seizures occurred in 26% of cases, and the mortality rate was 10%. Most patients (78%) required a short intensive care unit stay (<14 days), whereas prolonged hospitalization was associated with seizures, infections, or postoperative hemorrhage.

Conclusions: The management of craniopharyngioma requires close collaboration between neurosurgeons, endocrinologists, ophthalmologists, intensivists, nutritionists, and psychologists. A multidisciplinary approach is essential to reduce postoperative complications, optimize functional recovery, and improve patients' quality of life. It should be considered the standard of care for these complex lesions.

O22 - Neurosurgical management of intraorbital tumors: a six-case series and review of surgical approaches

Oral II

Emna Mzoughi, Nesrine Nessib, Amina Oueslati, Abdelhafid Slimane, Amel Chebbi, Khalil Ghedira, Sofiene Bouali

Department of neurosurgery , National Institute of Neurology, Tunisia.

Introduction: Intraorbital tumors comprise a heterogeneous group of benign and malignant lesions with variable clinical presentation, radiological characteristics, and surgical complexity. Progressive unilateral exophthalmos is the most frequent presenting symptom, while visual impairment and ocular motility disorders may occur depending on tumor location and extension. Surgical management requires meticulous anatomical planning and a multidisciplinary collaboration between neurosurgeons and ophthalmologists to achieve maximal safe resection while preserving visual function. We report our experience in the management of six intraorbital tumors using different neuro-ophthalmological surgical approaches.

Methods: We retrospectively reviewed six female patients aged 19 to 50 years who underwent surgery for intraorbital tumors. Clinical presentation, imaging findings, surgical approach, histopathological diagnosis, and postoperative outcomes were analyzed. Surgical corridors were selected according to tumor location and included transconjunctival, transpalpebral, and frontotemporal orbitozygomatic (FTOZ) approaches. One highly vascular malignant tumor underwent preoperative embolization to minimize intraoperative blood loss.

Results: Progressive unilateral exophthalmos was the predominant presenting symptom in all patients, with variable degrees of severity. Histopathological examination demonstrated both benign and malignant orbital tumors, reflecting the pathological diversity of intraorbital lesions. Surgical strategy was individualized according to tumor location, extension, and vascularity. Preoperative embolization facilitated safe resection of the highly vascular malignant lesion. Gross total or maximal safe resection was achieved in all patients. No major intraoperative complications occurred. Postoperative recovery was favorable, with satisfactory cosmetic outcomes, preservation of visual function, and no permanent neurological or ophthalmological deficits.

Conclusion: The management of intraorbital tumors should be tailored to the anatomical location, biological behavior, and vascular characteristics of each lesion. Careful preoperative imaging, appropriate selection of the surgical approach, and close collaboration between neurosurgeons and ophthalmologists are essential to optimize functional and oncological outcomes. Preoperative embolization represents a valuable adjunct in selected hypervascular tumors. Our experience highlights the safety and effectiveness of individualized neuro-ophthalmological approaches for the treatment of diverse intraorbital tumors.

O23 - Blood, clots, and clarity: does T1 hyperintensity predict visual outcome in pituitary apoplexy?

Oral III

Radhouane Khaled, Farhat S, Affes A, Kammoun T, Kammoun H, Bouzouita K, Chkili Ridha, Yedeas MD, Ghedira K

Neurosurgery Department, Military Hospital of Tunis, Tunis, Tunisia

Background: Magnetic resonance imaging (MRI) plays a central role in the diagnosis and characterization of pituitary apoplexy (PA). T1-weighted signal intensity is commonly used as a surrogate marker of intratumoral hemorrhage, but its correlation with histopathological findings (necrosis vs. hemorrhage) and its prognostic value for visual recovery remain insufficiently characterized.

Methods: We retrospectively analyzed MRI and histopathological data of 32 patients surgically treated for PA via the transsphenoidal route. Tumor size, extension pattern (classified according to the SIPAP classification: Suprasellar, Infrasellar, Parasellar, Anterior, Posterior), and the presence of T1 hyperintensity were assessed and correlated with histopathological findings (necrosis, hemorrhage, or mixed necrotic-hemorrhagic pattern) and with postoperative visual outcomes (visual acuity, fundoscopy, visual field, oculomotor function).

Results: Most adenomas were macroadenomas, with 84.4% measuring ≥ 2 cm. Suprasellar extension was the most common pattern (68.8%), followed by parasellar (34.4%) and chiasmatic extension (25.0%); infrasellar extension was rare (3.1%). A T1 hyperintense signal was present in 65.6% of cases. Histopathology revealed necrosis in 40.7%, hemorrhage in 37.5%, and a mixed necrotic-hemorrhagic pattern in 21.9% of cases. Neither tumor size, extension pattern, nor T1 hyperintensity were significantly associated with postoperative recovery of visual acuity, visual field, or oculomotor function ($p > 0.05$), and recovery rates remained high and homogeneous (59–62% for visual acuity, 86–91% for visual field, 91–95% for oculomotor function) regardless of T1 signal status. The only significant radiological association was between parasellar extension and a lower rate of fundoscopic improvement ($p = 0.002$). Similarly, the histopathological pattern (necrosis, hemorrhage, or both) showed no significant association with recovery of any visual parameter ($p = 0.594–0.857$).

Conclusion: In this cohort, standard preoperative MRI features—tumor size, extension pattern, and T1 signal intensity—did not reliably predict the underlying histopathological pattern (necrosis vs. hemorrhage) nor postoperative visual recovery, with the exception of parasellar extension, which was associated with poorer fundoscopic outcome. These findings suggest that, while MRI remains essential for diagnosis and surgical planning, its value as an isolated prognostic tool for visual recovery in PA appears limited.

O24 - Necrosis, hemorrhage, or both? histopathological spectrum of pituitary apoplexy and its clinical correlates

Oral III

Radhouane Khaled, Farhat S, Affes A, Hdhili H, Kammoun H, Bouzouita K, Chkili Ridha, Yedeas MD, Ghedira K

Neurosurgery Department, Military Hospital of Tunis, Tunis, Tunisia

Background: Pituitary apoplexy (PA) results from acute hemorrhage and/or infarction within a pre-existing pituitary adenoma. Although necrosis and hemorrhage are often described as the two histopathological hallmarks of PA, their relative frequency, coexistence, and clinical or radiological correlates remain incompletely characterized.

Methods: We retrospectively reviewed the histopathological findings of surgical specimens from 32 patients operated via the transsphenoidal route for PA, classifying lesions as hemorrhagic, necrotic, or mixed necrotic-hemorrhagic. These patterns were analyzed in relation to clinical presentation, T1-weighted MRI signal, and postoperative recovery of visual acuity, fundoscopic findings, visual field, and oculomotor function.

Results: Histopathological examination revealed necrosis in 40.7% of cases, hemorrhage in 37.5%, and a combined necrotic-hemorrhagic pattern in 21.9%, indicating that pure and mixed forms were almost equally represented and that no single pattern clearly predominated. A T1 hyperintense signal, classically considered a marker of intratumoral hemorrhage, was present in 65.6% of cases overall, without a clear-cut correspondence to the histopathological pattern. Regarding postoperative outcomes, the histopathological pattern (necrosis, hemorrhage, or both) was not significantly associated with recovery of visual acuity, fundoscopic findings, visual field, or oculomotor function ($p = 0.744$, 0.594, 0.857, and 0.857, respectively). A non-significant trend toward more frequent fundoscopic improvement was noted in patients with isolated hemorrhage (91.7%) compared with those with necrosis or mixed lesions.

Conclusion: Necrosis and hemorrhage coexist in a substantial proportion of apoplectic pituitary adenomas, and neither pure nor mixed histopathological patterns appear to significantly influence postoperative visual recovery. These findings suggest that, once surgical decompression is achieved, the underlying histopathological substrate of apoplexy — whether predominantly necrotic, hemorrhagic, or both — has limited additional prognostic value for visual outcome, reinforcing the primacy of timely decompression over histological subtype in determining functional recovery.

O25 - Out of the blind spot: recovery after complete visual loss in pituitary apoplexy

Oral III

Radhouane Khaled, Farhat S, Affes A, Kammoun T, Kammoun H, Bouzouita K, Chkili Ridha, Yedeas MD, Ghedira K

Neurosurgery Department, Military Hospital of Tunis, Tunis, Tunisia

Background: Severe visual impairment, including blindness, represents the most feared functional consequence of pituitary apoplexy (PA). Data on visual recovery after emergency surgical decompression in patients presenting with profound visual loss remain limited, particularly regarding cases of unilateral or bilateral blindness.

Methods: Among 32 patients surgically treated for PA via the transsphenoidal route, we focused on patients presenting with severe visual acuity impairment (visual acuity < 5/10 or bilateral involvement), including two patients presenting with complete blindness (one unilateral, one bilateral). Visual acuity, visual field, fundoscopic, and oculomotor outcomes were assessed at postoperative day 3, 1 month, and 6 months.

Results: At admission, 78.1% of patients presented with decreased visual acuity, unilateral in 34.4% and bilateral in 43.8% of cases; among these, 62.5% had severe impairment, including one patient with unilateral blindness and one with bilateral blindness. Overall, postoperative visual acuity improved in 50% of patients at day 3 and in 59.4% at 1 and 6 months, with 37.5% remaining stationary and 12.5% worsening at day 3. Among the two blind patients, the one with unilateral blindness showed partial recovery of visual acuity, whereas the patient with bilateral blindness showed no improvement in visual acuity at follow-up. Notably, both blind patients experienced improvement of their visual field postoperatively, consistent with the overall favorable visual field outcome observed in the cohort (87.5% improvement at 1 month). Fundoscopic and oculomotor function also improved in the majority of patients (84.4% and 93.7% respectively at 6 months).

Conclusion: Even in cases of complete blindness due to pituitary apoplexy, emergency transsphenoidal decompression can be associated with meaningful visual field recovery, although recovery of visual acuity appears more limited, particularly in bilateral blindness. These findings support an aggressive surgical approach even in the most severe presentations, while underscoring the need for realistic counseling regarding visual acuity prognosis in bilateral blindness.

O26 - Prognostic factors for visual recovery after surgery for pituitary apoplexy

Oral III

Radhouane Khaled, Farhat S, Affes A, Kammoun T, Kammoun H, Bouzouita K, Chkili Ridha, Yedeas MD, Ghedira K

Neurosurgery Department, Military Hospital of Tunis, Tunis, Tunisia

Background: Visual impairment is among the most feared consequences of pituitary apoplexy (PA), and identifying factors that predict visual recovery after surgical decompression remains a clinically relevant question.

Methods: In a retrospective cohort of 32 patients surgically treated for PA via the transsphenoidal route, we analyzed the influence of clinical (age, sex, comorbidities), endocrine (tumor secretory status, anterior pituitary insufficiency), radiological (tumor size, extension, T1 hyperintensity), histopathological (necrosis vs. hemorrhage), and temporal (time from apoplexy to surgery) factors on postoperative recovery of visual acuity, fundoscopic findings, visual field, and oculomotor function. Univariate analysis was performed using Chi-square or Fisher's exact test, with a significance threshold of $p < 0.05$.

Results: Overall, postoperative improvement was observed in 59.4% of patients for visual acuity, 84.4% for fundoscopic findings, 87.5% for visual field, and 93.8% for oculomotor function. Age, sex, diabetes, hypertension, tumor secretory status, and the degree of anterior pituitary insufficiency were not significantly associated with visual outcome for any parameter ($p > 0.05$). Anticoagulant/antiplatelet use was significantly associated with absence of visual field improvement (75.0% vs 7.1%, $p = 0.008$). Tumor size, suprasellar/parasellar extension, and T1 hyperintensity on MRI did not significantly influence recovery, except for a parasellar extension being associated with poorer fundoscopic recovery ($p = 0.002$). Histopathological pattern (necrosis, hemorrhage, or both) showed no significant association with any visual outcome. A shorter time from apoplexy to surgery (≤ 7 days) was associated with a non-significant trend toward better recovery of visual acuity (68.4% vs 50%), visual field, and oculomotor function.

Conclusion: In this series, most classical clinical, endocrine, radiological, and pathological variables did not significantly predict visual recovery after surgery for PA, except for anticoagulant use (associated with worse visual field outcome) and parasellar extension (associated with worse fundoscopic outcome). A trend favoring early surgery was noted but did not reach statistical significance, likely reflecting limited sample size. These findings underline the overall favorable visual prognosis of surgically treated PA, largely independent of baseline tumor characteristics.

O27 - The pituitary apoplexy score (PAS) and surgical timing: implications for visual outcome

Oral III

Radhouane Khaled, Farhat S, Affes A, Kammoun T, Kammoun H, Bouzouita K, Chkili Ridha, Yedeas MD, Ghedira K

Neurosurgery Department, Military Hospital of Tunis, Tunis, Tunisia

Background: The optimal timing of surgery in pituitary apoplexy (PA) remains debated. The Pituitary Apoplexy Score (PAS) and the commonly used 7-day cut-off for time from apoplexy to surgery (ATS) have been proposed as tools to guide management, but their prognostic value for visual recovery is inconsistently reported in the literature.

Methods: We retrospectively reviewed 32 patients who underwent transsphenoidal surgery for PA, comparing visual outcomes (visual acuity, fundoscopic findings, visual field, oculomotor function) between patients operated within 7 days (early surgery) versus after 7 days (delayed surgery). Results were also compared with the existing literature regarding the PAS and surgical timing.

Results: The median ATS was 5 days, with 62.5% of patients operated within 7 days, 21.9% between 8 and 21 days, and 15.6% after 21 days. Early surgery was associated with a higher rate of visual acuity improvement (68.4% vs 50%, $p = 0.73$), and all patients who improved in visual field and oculomotor function belonged to the early-surgery group, while non-improving patients were operated after 7 days; however, these differences did not reach statistical significance. No significant association was found with fundoscopic recovery ($p = 1.000$).

Conclusion: Although the 7-day cut-off did not reach statistical significance in our cohort, a consistent trend favored earlier surgical decompression for visual recovery, in line with several reports advocating for the existence of a critical therapeutic window. These findings support the relevance of the PAS and ATS as practical decision-making tools, while highlighting the need for larger multicenter studies to clarify the existence and limits of this critical window.

O28 - Thin blood, thick trouble: anticoagulant use and visual field recovery after surgery for pituitary apoplexy

Oral III

Radhouane Khaled, Farhat S, Affes A, Hdhili H, Kammoun H, Bouzouita K, Chkili Ridha, Yedeas MD, Ghedira K

Neurosurgery Department, Military Hospital of Tunis, Tunis, Tunisia

Background: Anticoagulant and antiplatelet agents are a recognized precipitating factor for intratumoral hemorrhage in pituitary adenomas, but their impact on postoperative visual recovery after surgery for pituitary apoplexy (PA) has been rarely studied.

Methods: Among 32 patients surgically treated for PA via the transsphenoidal route, we analyzed the association between anticoagulant/antiplatelet therapy and postoperative recovery of visual acuity, fundoscopic findings, visual field, and oculomotor function, using Chi-square or Fisher's exact test (significance threshold $p < 0.05$).

Results: Anticoagulant or antiplatelet therapy was present in 5 of 32 patients (15.6%). While no significant association was found between anticoagulant use and recovery of visual acuity, fundoscopic findings, or oculomotor function ($p = 1.000$ for all), a strong and significant association was observed for visual field recovery: anticoagulant use was significantly more frequent among patients without visual field improvement than among those who improved (75.0% vs 7.1%, $p = 0.008$). In other words, the majority of patients who failed to recover their visual field were on anticoagulant or antiplatelet therapy, whereas this was rare among patients who improved.

Conclusion: Anticoagulant/antiplatelet therapy was the only factor in our series significantly associated with poorer visual field recovery after surgery for pituitary apoplexy, despite having no detectable effect on visual acuity, fundoscopy, or oculomotor function. This selective impact on the visual field suggests a possible role of ongoing microvascular or hemorrhagic phenomena affecting the chiasmal pathways. These findings argue for heightened vigilance, careful perioperative management of anticoagulation, and tailored counseling regarding visual field prognosis in this subgroup of patients.

O29 - Descriptive study of 32 cases of pituitary apoplexy managed by transsphenoidal surgery

Oral III

Radhouane Khaled, Farhat S, Affes A, Hdhili H, Kammoun H, Bouzouita K, Chkili Ridha, Yedeas MD, Ghedira K

Neurosurgery Department, Military Hospital of Tunis, Tunis, Tunisia

Background: Pituitary apoplexy (PA) is a rare but potentially severe neuro-endocrine emergency resulting from acute hemorrhage and/or infarction within a pre-existing pituitary adenoma. We describe the epidemiological, clinical, hormonal, radiological, and pathological features of a surgical cohort of PA.

Methods: We conducted a retrospective, single-center cohort study of 32 patients who underwent transsphenoidal surgery for PA at the National Institute of Neurology of Tunis over a 14-year period (2010–2023). Clinical, ophthalmological, hormonal, radiological, and histopathological data were collected and analyzed.

Results: The mean age at diagnosis was 52.3 ± 13.6 years, with a male predominance (59.4%, sex ratio 1.46). Headache was the most frequent symptom (72.2%), followed by vomiting (31.3%) and meningismus (34.4%). Visual acuity was decreased in 78.1% of patients, with severe impairment in 62.5% of affected eyes, and bilateral visual field defects were found in 53.1%. Oculomotor palsy was present in 46.9% of patients. Non-functioning adenomas accounted for 75% of cases, and 62.5% of patients had anterior pituitary insufficiency (partial in 37.5%, complete in 25%). On MRI, 84.4% of adenomas measured ≥ 2 cm, with suprasellar extension in 68.8%, and a T1 hyperintense signal was present in 65.6%. Histopathology showed necrosis in 40.7%, hemorrhage in 37.5%, and a combination of both in 21.9%. The median time from apoplexy to surgery (ATS) was 5 days; 62.5% of patients were operated within 7 days. Postoperatively, visual acuity improved in 59.4% of patients at 1 and 6 months, fundoscopic findings improved in 84.4%, visual field defects improved in 87.5%, and oculomotor function improved in 93.7% at 6 months. Diabetes insipidus (18.8%) and corticotropic insufficiency (15.6%) were the most common postoperative complications.

Conclusion: This series confirms that PA predominantly affects middle-aged men with large, non-functioning macroadenomas, frequently complicated by visual and hormonal deficits. Transsphenoidal surgery, performed within a median delay of 5 days, was associated with favorable functional outcomes across all visual parameters, supporting its role as the cornerstone of management.

O30 - Beyond the shunt: quality of life and functional outcomes in children with treated hydrocephalus

Oral IV

Firas Gahbiche, F. Kolsi[1], I. Cherif[2], K. Ayadi[1], B. Essid[1], S. Abdelmoula[1], S. Chaari[1], M. Taallah[1], M. Borni[1], B. Kammoun[1], W. Elleuch [3] Boudawara Mz[1].

[1] Neurosurgery department , Habib Bourguiba Hopsital , sfax , Tunisia

[2] Neurosurgery department , HMUS , sfax , Tunisia

[3] Physical Medicine and Rehabilitation, HMUS , sfax , Tunisia

Introduction: Hydrocephalus is the most common neurosurgical condition in the pediatric population. Despite treatment with ventriculoperitoneal shunt (VPS), affected children remain at risk of persistent psychological and functional morbidities that may significantly impair their quality of life (QoL). Anxiety, depression, fatigue and pain are among the most frequently reported postoperative symptoms, yet their combined impact on QoL remains insufficiently characterized, particularly in low- and middle-income settings. This study aimed to analyze the relationship between these functional symptoms and QoL in children with hydrocephalus treated by VPS, using the Theory of Unpleasant Symptoms (TOUS) by Lenz as the theoretical framework.

Methods: A cross-sectional study was conducted including all children who underwent VPS placement for hydrocephalus at Habib Bourguiba University Hospital, Sfax, Tunisia, between 2014 and 2022. Sociodemographic and clinical data were retrieved from medical records. Two validated instruments were administered to parents: the Hydrocephalus Outcome Questionnaire (HOQ), assessing QoL across three domains (physical health, socio-emotional health, and cognitive function); and the Patient-Reported Outcomes Measurement Information System (PROMIS-25 v2.0), measuring anxiety, depression, fatigue, and pain. Statistical analysis included descriptive statistics, bivariate correlation tests, and multiple linear regression, performed using SPSS Advanced Statistics version 26.

Results: A total of 47 children met the inclusion criteria and were enrolled in the study. The mean global HOQ score was 0.61, with mean sub-scores of 0.64 for physical health, 0.59 for socio-emotional health, and 0.62 for cognitive function. Mean PROMIS scores were 49.8 for depression, 52.4 for anxiety, 58.6 for fatigue, and 65.7 for pain. Bivariate analysis revealed strong positive correlations between all functional symptoms and the global HOQ score. Sociodemographic variables and VPS-related clinical characteristics showed no statistically significant association with QoL variation ($p>0.05$). Multivariate regression analysis identified fatigue as the sole predictor of both physical health ($\rho=0.716$; $p=0.001$) and socio-emotional health ($\rho=0.682$; $p=0.001$).

Discussion: These findings confirm that functional symptoms, particularly fatigue, are major determinants of QoL in children with hydrocephalus bearing a VPS. Fatigue, a frequently underestimated symptom in postoperative follow-up, appears to play a central role in the deterioration of both physical and relational well-being. These results are consistent with the TOUS theoretical framework. The absence of a significant association between QoL and sociodemographic or clinical variables underscores the predominant role of symptom burden over contextual factors in shaping health-related QoL outcomes in this cohort.

Conclusion: Systematic screening for functional comorbidities and targeted fatigue management should be integrated into routine postoperative care for children with hydrocephalus.

O31 - Congenital myelomeningocele and hydrocephalus: a clinical audit

Oral IV

Seraj Ajaj, Faisal Taleb[1], Samira Abudia [3], Lali Ali Albakoush [4]

Departments of Neurosurgery [1,2] and Obstetric and Gynecology [3,4]. Tripoli University Hospital, Tripoli, Libya

Background: Congenital Myelomeningocele and congenital Hydrocephalus are among the most common pediatric neurosurgery diseases in Libya. This paper elucidates the experience of authors in clinical audit of seventy four cases diagnosed as congenital Myelomeningocele and hydrocephalus, in the period of time (Feb 2017 to Dec 2017).

Materials and methods: This was a prospective study of 74 cases whose data were collected as per the pre-prepared data sheet in a single tertiary Institute in Tripoli (Tripoli Medical Center) from February 2017 and December 2017.

Results: Management of 74 patients with complete data was analyzed. Of 74 patients, 20 (27%) patients were isolated MMC, 25 (34%) were isolated HCP, and 29 (39%) occurring in association with MMC. From a total of 74 patients, 34 (45%) were male and 40 (54%) were female. Furthermore, 27 (36%) patients delivered as premature infant and 47 (63%) were full term. The method of delivery was by cesarean section in 69 (93%) cases and by normal vaginal delivery in 5 cases (1%). The prenatal diagnosis of MMC and HCP using ultrasound was established in 70 (94%) cases. Head circumference of all cases at the time of delivery was ranged from 33 to 56 cm.The surgical management of all 74 cases after the diagnosis in our neurosurgical department was as follows: Ventriculoperitoneal (VP) shunts inserted in 63 cases (85%). MMC repair was performed in 38 cases (51%). Most patients 55 (74%) were discharged routinely after VP shunt insertion and MMC repair, while 19 (26%) died in hospital. Further, folic acid intake by dose of (0.4 mg) orally was documented in 31 (41%) pregnant women, and 43 (58%) cases were not taken folic acid. The timing of folic acid intake was after the pregnancy was confirmed in all cases.

Conclusion: This review demonstrates a single-institute experience and the current challenges in the management of both MMC and HCP in Libya. The Awareness of the mandatory intake of folic in our society is a national call.

O32 - Endoscopic management of hydrocephalus experience of the neurosurgery department of mohammed VI university hospital of oujda

Oral IV

Dahamou Mohamed, Elfarissi Mohammed Alamine; Khoulali Mohamed; Khay Hamid

Neurosurgery Department, Mohammed VI University Hospital, Oujda, Morocco

Hydrocephalus is a frequent neurosurgical disorder resulting from impaired circulation or absorption of cerebrospinal fluid, leading to ventricular dilatation and increased intracranial pressure. In recent years, neuroendoscopic procedures have emerged as minimally invasive and effective alternatives to conventional shunt surgery, particularly in obstructive hydrocephalus. We report the experience of the Neurosurgery Department of Mohammed VI University Hospital of Oujda in the neuroendoscopic management of hydrocephalus. This retrospective study included patients treated endoscopically for different etiologies of hydrocephalus. Clinical presentation, radiological findings, surgical indications, operative techniques, and postoperative outcomes were analyzed. Endoscopic third ventriculostomy was the main procedure performed, with satisfactory clinical improvement in the majority of patients. The technique reduced dependence on ventriculoperitoneal shunts and minimized shunt-related complications. However, a limited number of patients required secondary cerebrospinal fluid diversion procedures. Neuroendoscopy constitutes a reliable and minimally invasive approach in the treatment of selected forms of hydrocephalus. Appropriate patient selection and regular postoperative follow-up are crucial for achieving favorable long-term outcomes.

O33 - Surgical management of chiari I malformation associated with syringomyelia: analysis of 132 cases, effect of surgery on chiari I and syrinx, and our intraoperative findings

Oral IV

Belgacem Ibrahim, Si Tayeb Fatima Zohra, Chahed Mbarek, Djouadi Yasmine, Aboudjabel Mohamed, Maameri Lila, Ait Bachir Mustapha

Department of Neurosurgery, CHU Nedir Mohamed, Tizi Ouzou, Algeria

Objective: Several surgical techniques have been proposed for the treatment of syringomyelia associated with Chiari I malformation (CM-I). The aim of this study was to evaluate the clinical and radiological outcomes of posterior fossa decompression with duraplasty, to analyze the effect of surgery on syringomyelia, and to report our main intraoperative findings.

Methods: We retrospectively reviewed 132 adult patients with Chiari I malformation associated with syringomyelia who underwent surgical treatment between November 2002 and 2020. The series included 68 women and 64 men, aged 28 to 50 years. Diagnosis was established by magnetic resonance imaging (MRI) in all cases. All patients underwent a limited suboccipital craniectomy combined with wide duraplasty. Clinical and radiological outcomes were assessed during long-term follow-up.

Results: The most remarkable intraoperative finding was the presence of a thin membranous structure covering the foramen of Magendie in a large number of patients, potentially contributing to cerebrospinal fluid flow obstruction at the craniovertebral junction. Postoperative follow-up demonstrated clinical improvement in 87 patients (63.1%), stabilization in 38 patients (31.1%), and neurological deterioration in 5 patients (4.1%). Better surgical outcomes were observed in patients with a shorter duration of symptoms before surgery. MRI follow-up showed reduction or stabilization of the syrinx in the majority of cases. Two deaths were recorded during the study period, resulting in a mortality rate of 1.5%.

Conclusion: Suboccipital decompression associated with duraplasty, with or without cerebellar tonsillar reduction, provides long-term stabilization or improvement in most patients with Chiari I malformation and syringomyelia. Early diagnosis and timely surgical intervention are important prognostic factors. Our experience suggests that a limited 3–4 cm suboccipital craniectomy centered on the foramen magnum is sufficient to achieve adequate decompression while potentially reducing postoperative complications.

O34 - The m.scio implantation for intracranial pressure monitoring: a promising device for personalized management of complex hydrocephalus

Oral IV

Haifa Mechergui, Salim Bachraoui, Khalil Ghedira

Surgery Department, Bougatfa Hospital Bizerte, Tunisia

Departement of Neurosurgery, national instiut of neurology of Tunis, Tunisia

Complex hydrocephalus refers to a subset of hydrocephalus in which abnormal or compartmentalized ventricular anatomy and/or recurrent shunt dysfunction complicate management and necessitate a tailored neurosurgical approach. Its management remains challenging, particularly in patients with idiopathic intracranial hypertension, multiple shunt revisions, intermittent shunt dysfunction, or radioclinical dissociation.The aim of this presentation is to to highlight the role of the M.scio in optimizing the management of patients with complex hydrocephalus. The M.scio® device is an implantable telemetric monitoring of intracranial pressure (ICP) integrated into the cerebrospinal fluid shunt system. It allows repeated, non-invasive intracranial pressure measurements in different positions using an external reader. These measurements provide objective pressure data during follow-up and may guide clinical decision-making, particularly in patients with persistent or recurrent symptoms after shunt placement. By providing real-time pressure monitorin, the M.scio® device helps differentiate between intermittent obstruction, pressure variation throughout the day and normal-pressure situations. This facilitates individualized adjustment of programmable valves, and may prevent unnecessary imaging, invasive monitoring, hospital admissions and reduce surgical revisions. In complex hydrocephalus, where ventricular size may not accurately reflect intracranial pressure, telemetric monitoring offers a more precise and dynamic evaluation of cerebrospinal fluid physiology.

Conclusion: The M.scio® device represents a valuable adjunct in the management of complex hydrocephalus. Its ability to provide repeated non-invasive intracranial pressure measurements supports personalized shunt management, improves diagnostic accuracy, reduces surgical revision and contributes to safer and more tailored patient care.

O35 - Ultrasound-guided percutaneous ventriculoatrial shunting: a safe, minimally invasive alternative for adult cerebrospinal fluid diversion

Oral IV

Houssem Hdhili, F.Akrout, S.Farhat, H.Kammoun, S.Achoua, A.Harbaoui, R.Chkili, M.D.Yedeas, K.Radhouane

Department of Neurosurgery, Military Hospital of Tunis, Tunisia

Background: While ventriculoperitoneal shunting (VPS) remains standard for hydrocephalus, hydrocephalus (iNPH), and post-traumatic hydrocephalus. ventriculoatrial shunts (VAS) are reserved for select cases due to the risks associated with open neck dissection. This study evaluates an ultrasound-guided, percutaneous VAS technique that avoids open dissection in adult patients with idiopathic intracranial hypertension (IIH), idiopathic normal pressure.

Methods: In this prospective cohort study (Jan 2024–Jun 2026), 32 adult patients (iNPH=23, IIH=6, posttraumatic=3) underwent ultrasound- and fluoroscopy-guided percutaneous VAS. The distal catheter was introduced via the internal jugular vein and positioned in the right atrium; neuronavigation was used for ventricular access in IIH cases. Four procedures were performed under local anesthesia, and 28 under general anesthesia. Operative time, perioperative complications, hospital stay, and clinical outcomes were recorded prospectively.

Results: All procedures were technically successful, with accurate catheter placement confirmed by CT in all cases. Mean operative time was 22 ± 10 minutes. No major complications were reported. The median hospital stay was 2 days. At 3-month follow-up, all patients demonstrated meaningful clinical improvement: gait and cognitive gains in the iNPH group, headache resolution and improved visual function in IIH patients, and symptomatic relief in post-traumatic hydrocephalus.

Conclusion: Ultrasound-guided percutaneous VAS is a safe, efficient, and minimally invasive alternative to VPS for iNPH, IIH, and post-traumatic hydrocephalus. This single-center series confirms previous systematic review findings, suggesting lower rates of shunt dysfunction or obstruction with VAS, and no increased morbidity. We recommend considering this approach as a primary CSF diversion strategy, particularly in patients with elevated anesthetic risk.

O36 - Understanding ventriculoperitoneal shunt failure: predictors of revision in pediatric hydrocephalus

Oral IV

Majdouline Barkache, M.Ben Messsaoud, H. Kammoun, A. Affes, I. Ksira

Department of Neurosurgery, Sahloul Hospital, Sousse, Tunisia

Background: Ventriculoperitoneal (VP) shunting remains the standard treatment for pediatric hydrocephalus, yet shunt failure requiring revision is frequent and represents a major source of morbidity. Identifying predictors of shunt failure is essential to improve surgical planning, follow-up strategies, and long-term outcomes. This study aims to analyze factors associated with VP shunt revision in children.

Methods: A retrospective study was conducted including 58 pediatric patients who underwent VP shunt insertion for hydrocephalus between 2020 and 2023. Clinical, etiological, and surgical variables were reviewed, including age at insertion, cause of hydrocephalus, nutritional and infection status, and imaging findings. Shunt failure was defined as any malfunction requiring surgical revision. Statistical analysis was performed to identify potential predictors of revision.

Results: During follow-up, a significant proportion of patients required at least one shunt revision. The most frequent causes of failure were mechanical obstruction, infection, and distal catheter malfunction. Higher revision rates were observed in infants and younger children, particularly those with post-infectious or post-hemorrhagic hydrocephalus. Complex hydrocephalus etiologies and early postoperative complications were also associated with increased risk of shunt failure. Infection was a major contributor to early revision, whereas mechanical obstruction predominated in late failures. Overall, patient-related factors (age, etiology) and device-related complications emerged as the main determinants of shunt survival.

Conclusion: VP shunt failure remains common in pediatric hydrocephalus, with revision risk strongly influenced by patient age, underlying etiology, and infection status. Early identification of high-risk patients may allow closer surveillance and tailored surgical strategies. Improving perioperative care and infection prevention may reduce revision rates and improve long-term shunt survival.

O37 - From a welding gun injury to evidence synthesis: endovascular therapy for traumatic vertebral artery injury—a systematic review and meta-analysis inspired by a clinical case

Oral V

Ibrahim Alnaami

King Khalid university,Abha, Saudi Arabia

Background: Traumatic vertebral artery injury (TVAI) is an uncommon but potentially devastating condition associated with hemorrhage, pseudoaneurysm formation, arteriovenous fistula, and posterior circulation stroke. We recently managed a young patient who sustained a penetrating vertebral artery injury from a welding gun projectile. The patient underwent successful endovascular treatment without neurological sequelae or procedural complications. Given the rarity of this injury and the absence of clear consensus regarding optimal management, this case prompted a systematic review and meta-analysis to evaluate the effectiveness and safety of endovascular therapy (EVT) in TVAI.

Methods: A comprehensive search of PubMed, Scopus, Web of Science, and the Cochrane Library was performed through October 2025. Studies reporting outcomes of EVT for traumatic vertebral artery injury were included. Primary outcomes were angiographic success, mortality, and stroke. Secondary outcomes included clinical improvement, procedural complications, clinical complications, and need for surgical intervention. A proportional meta-analysis using a random-effects model was conducted.

Results: Fourteen studies comprising 174 patients were included. EVT demonstrated a pooled angiographic success rate of 99% (95% CI, 95–100%; I^2=19%). Mortality and stroke rates were each 2%, while procedural and clinical complication rates were approximately 1%. Surgical intervention was required in 6% of patients, and clinical improvement was observed in 95%. Overall, the included studies were of moderate-to-high methodological quality.

Conclusions: A successful endovascular outcome in a young patient with penetrating vertebral artery injury prompted this evidence synthesis. The findings demonstrate that EVT achieves excellent technical success with low rates of stroke, complications, and mortality across a broad spectrum of traumatic vertebral artery injuries. These results support EVT as a safe and effective treatment option in appropriately selected patients and highlight the need for prospective comparative studies to better define its role relative to medical and surgical management.

O38 - Microsurgical clipping versus woven endobridge for intracranial aneurysms: a systematic review and meta-analysis

Oral V

Ibrahim Alnaami

King Khalid university,Abha, Saudi Arabia

Objective: To compare microsurgical clipping and Woven EndoBridge (WEB) embolization for the treatment of intracranial aneurysms, including ruptured and unruptured cases, with respect to angiographic occlusion, morbidity, mortality, and adverse events.

Methods: This systematic review and meta-analysis followed PRISMA guidelines and the Cochrane Handbook. PubMed, Scopus, and Web of Science were searched from inception to January 29, 2026 for comparative studies evaluating microsurgical clipping versus WEB embolization. Cohort studies and clinical trials were eligible regardless of aneurysm rupture status or morphology. Study selection and data extraction were performed independently by two reviewers. Risk of bias was assessed using the Newcastle–Ottawa Scale. Pooled risk ratios (RRs) with 95% confidence intervals (CIs) were calculated using a random-effects model. Heterogeneity was assessed with the I^2 statistic, and predefined subgroup and sensitivity analyses were conducted.

Results: Five cohort studies comprising 798 patients (402 clipping, 396 WEB) were included. Microsurgical clipping was associated with significantly higher complete occlusion rates compared with WEB (RR: 1.71, 95% CI: 1.21–2.42; P = 0.002), including analyses restricted to wide-neck aneurysms (RR: 2.04, 95% CI: 1.77–2.35). Adequate or complete occlusion also favored clipping (RR: 1.61, 95% CI: 1.24–2.11; P = 0.0004). There were no significant differences in morbidity (RR: 0.86, 95% CI: 0.33–2.25) or overall mortality (RR: 0.69, 95% CI: 0.37–1.28). Adverse event profiles differed between techniques, but overall rates were similar.

Conclusions: Microsurgical clipping provides higher rates of complete and adequate occlusion than WEB embolization, particularly for wide-neck aneurysms, without a significant increase in morbidity or mortality. Treatment selection should remain individualized based on aneurysm characteristics and clinical context.

O39 - Intracranial aneurysms with mass effect: why surgery remains the only complete answer — 55 cases

Oral V

Yacine Felissi, Meziani S., Handis C., Hadjali H., Ghozlane H., Morsli A.

Department of Neurosurgery, Bab El Oued University Hospital, Algiers, Algeria

Background: Intracranial aneurysms may present with progressive neurological deficits or life-threatening brain compression secondary to direct structural displacement or ruptured intracerebral hematomas. While endovascular techniques achieve effective vascular exclusion, they do not resolve local compressive phenomena. This study evaluates the efficacy of microsurgery in providing both definitive aneurysm occlusion and immediate mechanical decompression.

Methods: A retrospective review was conducted on 55 consecutive patients surgically treated for intracranial aneurysms presenting with acute or progressive mass effect. The cohort was stratified into three distinct neuroanatomical configurations: carotido-ophthalmic aneurysms causing optic pathway compression (managed via a pretemporal extradural approach); posterior communicating artery (PCoA) aneurysms presenting with oculomotor nerve palsy (treated with pterional clipping and direct nerve decompression); and ruptured aneurysms of the middle cerebral, anterior communicating, or posterior cerebral arteries complicated by compressive hematomas. The latter group required simultaneous hematoma evacuation and aneurysm securement.

Results: Complete or near-complete angiographic occlusion was systematically achieved across the cohort. Within the carotido-ophthalmic subgroup, postoperative visual function demonstrated stabilization or improvement, aligning with standard clinical expectations. Patients harboring PCoA aneurysms exhibited substantial rates of oculomotor recovery following early microsurgical decompression. For ruptured aneurysms complicated by compressive hemorrhage, a single-stage surgical procedure successfully facilitated both immediate intracranial pressure relief and aneurysm exclusion in all instances.

Conclusion: In the specific context of aneurysmal mass effect, whether manifested by cranial neuropathy or expansive intracerebral hemorrhage, microsurgery remains a definitive and critical therapeutic modality. Open surgical intervention uniquely offers the dual mechanism of vascular occlusion and direct neural decompression, representing a fundamental indication where endovascular approaches currently remain insufficient.

O40 - Surgical management of middle cerebral artery aneurysms through the distal transsylvian approach: technical rationale and outcomes

Oral V

Yacine Felissi, Meziani S., Handis C., Zireg H., Ghozlane H., Morsli A.

Department of Neurosurgery, Bab El Oued University Hospital, Algiers, Algeria

Background: . Middle cerebral artery (MCA) aneurysms account for approximately 20% of all intracranial aneurysms and represent a technically demanding entity due to their deep embedding within the sylvian fissure, complex branching anatomy, and frequent hemorrhagic presentation. While the transsylvian corridor is universally adopted for their surgical management, the entry point, direction of dissection, and interpretation of subarachnoid hemorrhage (SAH)-induced parenchymal changes vary substantially across surgical schools. The distal transsylvian approach reframes SAH-induced arachnoidal lysis as a surgical facilitator rather than a technical obstacle, sparing frontal lobe retraction on an already compromised brain.

Objective: . To report our surgical experience with the distal transsylvian approach for MCA aneurysms and to define its anatomical rationale, operative steps, and clinical outcomes.

Methods: . A retrospective analysis of 30 consecutive patients operated on for sylvian aneurysms between 2021 and 2026 was conducted. Subarachnoid hemorrhage was the predominant presentation. Preoperative planning systematically integrated sylvian fissure morphology analysis and MCA branching pattern assessment. The distal transsylvian corridor was applied as a standardized approach across all cases, prioritizing atraumatic fissure opening, early distal vascular control, and avoidance of frontal lobe retraction.

Results: . Complete aneurysm occlusion was achieved in 95% of cases. One patient (3.3%) developed postoperative hemiparesis. SAH-induced sylvian arachnoidal changes facilitated fissure dissection in the majority of hemorrhagic cases, consistent with the core premise of the approach.

Conclusion: . The distal transsylvian approach provides an anatomically coherent and reproducible operative strategy for sylvian aneurysm surgery. Redefining SAH as a surgical asset rather than a liability represents a conceptual shift with direct technical implications for approach selection and patient outcomes.

O41 - Determinants of long-term outcome in cushing's disease: a multicenter retrospective study

Oral V

Emna Elouni, Ghassen Elkahla, Mehdi Darmoul, Mohamed Zaher Boudouara, Jalel Kallel

Neurosurgery Departement, National Institute of Neurology, Tunis, Tunisia
Neurosurgery Departement of Fattouma Bourguiba University Hospital, Monastir, Tunisia
Neurosurgery department of Hbib Bourguiba University hospital, Sfax, Tunisia

Background: Despite major advances in the management of Cushing's disease, recurrence, persistent hypercortisolism, and treatment-related morbidity remain significant challenges. Identifying determinants of long-term outcomes is essential to optimize patient selection, treatment strategies, and postoperative follow-up. This study aimed to evaluate factors associated with remission, recurrence, and mortality in a multicenter cohort of patients with Cushing's disease.

Methods: We conducted a retrospective multicenter study including 73 patients treated surgically for Cushing's disease between January 2005 and June 2023 in three Tunisian tertiary neurosurgical centers. Demographic, clinical, endocrinological, radiological, pathological, therapeutic, and follow-up data were collected. Long-term outcomes were analyzed according to adenoma characteristics, imaging findings, surgical management, and postoperative course.

Results: The cohort showed a female predominance (80.8%) with a mean age of 39 years. Most adenomas were non-invasive (80.2%) and were treated by transsphenoidal surgery (98%). Initial remission was achieved in 78.2% of patients, while recurrence occurred in 21.7%. Persistent or recurrent disease required repeat surgery, medical therapy, or bilateral adrenalectomy, resulting in an overall remission rate of 76.7%. Long-term outcomes were primarily influenced by adenoma visibility on imaging, degree of cavernous sinus invasion, and extent of resection. In contrast, no significant difference in remission or recurrence rates was observed according to the surgical approach employed. Postoperative complications included diabetes insipidus (53.4%), cerebrospinal fluid leakage (8.2%), hypopituitarism (8.2%), and meningitis (2.7%). Overall mortality was 6.9%.

Conclusion: Long-term outcomes in Cushing's disease are determined mainly by tumor-related factors rather than the surgical technique itself. Early identification of invasive lesions and referral to experienced multidisciplinary centers may improve disease control and reduce recurrence and mortality.

O42 - Long-term outcomes of pituitary adenomas: complications, visual assessment and extent of resection (a series of 400 cases)

Oral V

Belgacem Ibrahim, Si Tayeb Fatima Zohra, Chahed Mbarek, Djouadi Yasmine, Aboudjabel Mohamed, Maameri Lila, Katia Ait Slimani, Ait Bachir Mustapha

Department of Neurosurgery, CHU Nedir Mohamed, Tizi Ouzou, Algeria

Introduction: Pituitary adenomas are common intracranial tumors that may lead to visual impairment, endocrine dysfunction, and neurological symptoms. This retrospective study evaluates long-term visual and endocrine outcomes, surgical complications, and extent of resection in a series of 400 patients treated between 2004 and 2020. A mean diagnostic delay of 24 months was observed, explaining the high rate of visual impairment at presentation.

Methods: We reviewed 400 consecutive patients who underwent surgery for pituitary adenomas. Radiological assessment included CT and MRI studies. Tumors were classified according to imaging findings and hormonal secretion profiles. Follow-up ranged from 6 months to 14 years.

Results: Radiological evaluation identified microadenomas in 10.6% of cases, intrasellar adenomas in 12.6%, and invasive macroadenomas in the remaining patients. Functional classification showed 31% prolactinomas, 30.5% non-functioning adenomas, 16% corticotroph adenomas, 14.6% somatotroph adenomas, 6.6% plurihormonal adenomas, and less than 1% thyrotroph and gonadotroph adenomas. All patients underwent surgical treatment. The endonasal transsphenoidal approach was performed in 83.3% of cases, whereas 11.5% required a transcranial approach. Gross total resection was achieved in 61% of patients, subtotal resection in 26%, and partial resection in 10%. Postoperative complications occurred in 32.7% of cases, mainly cerebrospinal fluid leakage (10.8%) and meningitis (8%). Overall mortality was 1.5%. Long-term follow-up demonstrated visual improvement in 61.5% of patients, stable visual status in 31.8%, and visual deterioration in 6.7%. Endocrine improvement was observed in approximately 60% of patients with hormone-secreting adenomas.

Conclusion: Surgical management of pituitary adenomas provides effective decompression of the visual pathways and favorable long-term outcomes. The extent of resection and postoperative functional recovery depend on tumor characteristics and early diagnosis. Timely surgical intervention remains essential to optimize visual and endocrine results while minimizing complications.

O43 - Cushing's disease without a visible pituitary adenoma on MRI: the role of inferior petrosal sinus sampling

Oral V

Belgacem Ibrahim, Si Tayeb Fatima Zohra, Chahed Mbarek, Djouadi Yasmine, Aboudjabel Mohamed, Maameri Lila, Katia Ait Slimani, Ait Bachir Mustapha

Department of Neurosurgery, CHU Nedir Mohamed, Tizi Ouzou, Algeria

Introduction: The diagnosis and management of Cushing's disease can be particularly challenging when pituitary magnetic resonance imaging (MRI) fails to identify a microadenoma. In such cases, Inferior Petrosal Sinus Sampling (IPSS) plays a crucial role in confirming a pituitary source of adrenocorticotropic hormone (ACTH) secretion and may help lateralize the lesion within the gland. The objective of this study was to evaluate the contribution of IPSS in patients with Cushing's disease and negative pituitary MRI findings.

Materials and methods: A retrospective study was conducted on 13 patients diagnosed with Cushing's disease between 2018 and 2024. The mean age was 24 years, with a sex distribution of 7 males and 6 females. All patients underwent comprehensive endocrinological evaluation and high-resolution pituitary MRI, which failed to demonstrate a visible adenoma in all cases. Inferior Petrosal Sinus Sampling (IPSS) was performed in every patient to confirm a central-to-peripheral ACTH gradient and to determine the side of excessive ACTH secretion within the pituitary gland. All patients subsequently underwent microscopic endonasal transsphenoidal surgery. In three patients, IPSS-guided hemihypophysectomy was performed because no adenoma could be identified intraoperatively.

Results: IPSS successfully confirmed a pituitary source of ACTH hypersecretion in all patients and provided valuable lateralization information for surgical planning. The endonasal transsphenoidal approach allowed targeted exploration of the pituitary gland despite the absence of MRI-visible lesions. In selected cases, IPSS-guided hemihypophysectomy facilitated treatment when no discrete adenoma was detected during surgery.

Conclusion: Inferior Petrosal Sinus Sampling is a valuable diagnostic and localization tool in patients with Cushing's disease and negative pituitary MRI. It improves diagnostic accuracy, guides surgical strategy, and increases the likelihood of identifying occult ACTH-secreting microadenomas, thereby optimizing patient management and surgical outcomes.

O44 - Vertebromedullary trauma in children

Oral V

El Kartit Fatima, Mohammed Khoulali, Hamid Khay, Mohammed Al Amine El Farissi, Mohamed Dahamou

Mohammed VI university hospital of OUJDA, Morocco

Background: pediatric spinal trauma is a potentially disabling injury that often results in a severe and permanent disability; its differs from those of adult by their causes, seats, evolution and treatments.

Objectives: the aim of this work is to evaluate the frequency of spinal cord injuries in children as well as to shed light on the clinical, radiological and therapeutic aspects of these lesions, as they are often unknown but have serious consequences both in health and socio-economic terms.

Materials and methods: our work is a retrospective study of 7 cases of spinal trauma in children under the age of 16 years old. the study was carried in neurosurgery departement of Mohammed VI university hospital over an 8 years period. all the children involved have benefited from clinical and radiological assessement including standard spine x ray, CT scan or MRI.Different epidemiological, clinical, para clinical and therapeutic aspects are reported and discussed.

Results: children between 11 and 16 years old were the most affected with a clear male sex predominance; various etiologies of vertebral trauma in children were identified but the most common in our Serie was a fall in 3 cases followed by road accidents in 2 cases and assaults in 2 cases as well. Clinical examination at admission ranged from simple spinal pain to complete loss of motor activity, sensory with vegetative disturbances depending on the level of spinal cord injury. all of our patients had neurological manifestations with a predominance of class A and B of Frankel classification. cervical spine, lumbar spine and the thoracolumbar junction were all equally affected, but injury of thoracic spine was reported in only one case. According to the radiological data, the various lesions objectified are: Fracture of the vertebral body or bone elements without dislocation in 4 cases, a disco ligamentous injury in 3 cases. medical and orthopedic treatments were proposed for all the children, surgery was performed on all patients; but only one patient underwent cervical traction.

Conclusion: spinal trauma is relatively rare in children, the upper cervical spine is the most vulnerable especially in young children. diagnosis is based on the clinic, CT scann and sometimes MRI. some patients can be treated by orthopedic means whereas surgery is reserved for precise indications. the evolution afterwards depend on the initial neurological state.

O45 - Pediatric intracranial suppurations: three distinct etiologic pathways—a bicentric hypothesis-generating study

Oral V

Firas Gahbiche, M. Borni, M. Znazen, F. Kolsi, M. Taallah, Mz. Boudawara

Habib Bourguiba University Hospital - Sfax, Tunisia

Background: Intracranial suppurations (ICS) in children differ fundamentally from adult disease in etiology, pathophysiology, and management considerations. Current guidelines are largely extrapolated from adult data, creating a knowledge gap in pediatric-specific practice.

Purpose: To describe the clinical, etiologic, and treatment characteristics of pediatric ICS in a bicentric cohort, and to identify factors associated with outcomes, generating hypotheses for future prospective studies.

Patients and methods: We conducted a retrospective, descriptive, bicentric study of pediatric ICS cases treated over a 7-year period (January 2012 – December 2018). From a total of 43 ICS cases, 10 pediatric patients (23.25%) were identified and form the basis of this analysis. Data on epidemiology, etiology, clinical presentation, imaging, microbiology, treatment, and outcomes (Glasgow Outcome Scale [GOS] at 6 months) were systematically collected and analyzed.

Results: The pediatric cohort (7 males, 3 females; sex ratio 2.33) showed a distinct age distribution with a peak in the 0–10 years age group. Three distinct etiologic pathways were identified: (1) post- meningitic subdural empyema (2 cases, infants <2 years); (2) hematogenous abscess from cyanogenic heart disease (2 cases: Tetralogy of Fallot, Ebstein's disease); and (3) locoregional spread from otitis/sinusitis (remaining cases). The classic Bergman triad was present in only 20% of pediatric cases. Neuroimaging confirmed cerebral abscesses (69.77% of total series) and empyemas (30.23% of total series). Streptococci were the predominant pathogens (75% of positive abscess cultures). Surgical intervention—puncture-aspiration for abscesses >2.5 cm or in eloquent zones (20 cases), and trepanation or craniotomy for empyemas (12 cases)—combined with targeted antibiotics was associated with favorable outcomes (GOS 4 or 5) in 80% of pediatric patients and 76.67% of all abscess cases. Recurrence occurred exclusively in patients with inadequately treated gateways.

Conclusion: Pediatric ICS follows distinct etiologic pathways: post-meningitic empyema in infants, hematogenous abscess in children with cyanotic heart disease, and locoregional spread from otitis/sinusitis in older children. Early recognition of these patterns, timely neuroimaging, and aggressive treatment of both the suppuration and its underlying gateway were associated with favorable outcomes in this series. Long-term sequelae including seizures and porencephaly are common, suggesting that sustained follow-up may be beneficial.

O46 - Encephalocele experience of the neurosurgery department of mohammed VI university hospital of oujda (about 11 cases)

Oral V

Dahamou Mohamed, Elfarissi Mohammed Alamine; Khoulali Mohamed; Khay Hamid; Kada Amine; Elkartit Fatima; Aniya Loubna

Neurosurgery Department, Mohammed VI University Hospital, Oujda, Morocco

Encephalocele is a rare congenital neural tube defect characterized by herniation of intracranial contents through a skull defect. Its clinical presentation and prognosis depend on the size, location, and associated cerebral malformations. We report a retrospective study of 11 cases of encephalocele managed in the Neurosurgery Department of Mohammed VI University Hospital of Oujda. The study included epidemiological, clinical, radiological, therapeutic, and outcome data. Most patients presented during infancy with a visible cranial mass. Neuroimaging, mainly computed tomography and magnetic resonance imaging, confirmed the diagnosis and evaluated associated anomalies. Surgical treatment was performed in all patients with excision of the sac and dural repair. The postoperative course was generally favorable, although some patients presented neurological sequelae and associated hydrocephalus requiring additional management. Encephalocele remains a rare but serious congenital malformation requiring early multidisciplinary management. Prenatal diagnosis and timely surgical treatment are essential to improve functional and cosmetic outcomes.

O47 - Optic pathway gliomas in children: visual outcome and prognostic factors — a 14-year single-center retrospective study

Oral V

Oualha Zied, N.Nessib, F.Kolsi, A.Slimane, F.Sliti, M.Naceur, A.Bouhoula, S.Bouali, K.Abderrahmen, I.B. Said, J.Kallel

Department of Neurosurgery, National institute of neurology, Tunis, Tunisia.

Optic pathway gliomas are low-grade glial tumors arising along the optic nerves, chiasm, and retrochiasmatic structures, accounting for ~1% of all intracranial tumors and 4-6% of pediatric tumors, with an incidence of 3-4 cases/100,000 children. Predominantly pediatric, 75% of cases occur within the first decade and 90% by the end of the second . Neurofibromatosis type 1 (NF1) accounts for 50-60% of OPG cases; sporadic forms, the remainder, follow a more aggressive course. Histologically, OPGs are predominantly pilocytic astrocytomas, though pilomyxoid and fibrillary variants carry less favorable outcomes. Despite their low-grade nature, visual prognosis remains highly variable and hard to predict, with no consensus on optimal treatment timing or strategy, particularly in NF1 patients. Determinants of long-term visual outcome — age at diagnosis, tumor extent, histological subtype, NF1 status, and therapeutic modality — remain insufficiently characterized. This study aimed to analyze the visual prognostic profile of OPGs and identify factors influencing long-term visual outcomes in a pediatric cohort managed at a single tertiary neurosurgical center over 14 years.******We conducted a retrospective single-center study of 15 patients treated for OPGs (Jan 2010-Dec 2023) at the Neurosurgery Dept, National Institute of Neurology of Tunis. Mean age at diagnosis: 5 years; M/F ratio 1.14. Visual acuity loss was the leading symptom (80%), followed by headaches (53%). Imaging showed chiasmatic/hypothalamic involvement (Dodge C) in 66%. All patients underwent surgery — 13 microsurgical, 2 stereotactic biopsy — for diagnostic/decompressive purposes, with histological confirmation in all cases. Low-grade lesions predominated: pilocytic astrocytoma grade I (80%), fibrillary astrocytoma grade II (13.3%), pilomyxoid astrocytoma grade II (6.7%). All NF1-associated cases were pilocytic astrocytoma grade I. Adjuvant treatment: first-line chemotherapy (40%), radiotherapy (33.3%); 2 patients needed second-line radiotherapy after chemo failure. Clinical deterioration, mainly visual, occurred in 33.3%, linked to tumor progression and treatment toxicity (especially radiotherapy). Stabilization occurred in 6.7%, meaningful regression in 13.3%. Bivariate analysis linked worse visual outcomes to: age <1 year, impaired baseline acuity, Dodge C, pilomyxoid histotype, and cerebral radiotherapy. NF1 association correlated with better visual prognosis. *******OPGs do not follow a single script. Visual course is shaped by age, histology, tumor extent, and treatment choices, each with its own weight. Some factors warn caution; others, like NF1, show biology can favor the patient. No two children with OPGs are alike. Early, individualized, multidisciplinary management remains key to visual preservation — because in a child, losing sight means losing a future.

O48 - Surgical techniques of non-syndromic craniostenosis: results and long-term outcome of a retrospective serie of 122 cases

Oral V

Toufik Selmane, Z. Abdellaoui, A. Chabat, S. Chennaoui, Z. Fellag, D. Dergham, K. Bouaita

NEUROsurgical specialized hospital, Cherchell 42002, Wilaya of TIPAZA, ALGERIA

Background: Non syndromic craniostenosis is define by a premature fusion of one or more cranial sutures that occurs 1 in 2000 to 2500 live births. Cranial deformities are often associated with cosmetic implications which could be added to high intracranial pressure and poor neurodevelopmental delays if they are not well managed surgically.

Methods: In this presentation, we describe the long-term outcome and results of craniosynostosis surgery performed in the Neurosurgery Department at EHS Cherchell between January 1, 2020, and June 1, 2026. Our series consists of a retrospective study of 123 cases aged between 4 to 22 months who underwent surgery for non-syndromic craniosynostosis. The collected data include the age of the child at the time of surgery, identification of fused sutures, the use of cranial vault remodeling, use of fronto-orbital advancement, per operative incidents, post operative complications, mortality and long-term cosmetic results

Results: The age range varies from 4 to 28 months with the value of 11 months as the mean age of our Serie. The mean follow-up period is 32 months. Cranial vault remodeling without removal of the frontal bone was performed in 57 cases (46.3%). Therefore, the sagittal suture synostosis is found to be the most frequent craniostenosis in our Serie. Bilateral remodeling of the frontoparietal vault alongside with fronto-orbital advancement was performed for unilateral coronal synostosis 32 cases (26%), bilateral coronal synostosis in 06 cases (4.8%), metopic synostosis in 11 cases (8,9%) and multi suture synostosis involving the unilateral or bilateral coronal suture in 16 cases (13%). One child only was operated for unilateral lambdoid synostosis. All patients needed blood transfusion at the time of surgery. Per operative dural tear was found in 12%. Infectious complications were nil (no meningitis nor wound infection). Cosmetic outcome was satisfactory. 01 child died after 08 hours (no massive bleeding nor any another specific complication).

Conclusion: Craniosynostosis causes an aesthetic and functional impairment requiring a true understanding of the deformity, an appropriate surgical treatment that should be adjusted for every patient at the appropriate age of the child.

O49 - After the long road: professional satisfaction, burnout, and career aspirations among tunisian neurosurgery residents — a national cross-sectional survey

Oral VI

Ameur Affes, Rachdi M.A., Hdhili H, Kammoun T, Akrout F, Chkili Ridha, Radhouen K.

Neurosurgery Department, Military Hospital of Tunis, Tunis, Tunisia

Background: . Neurosurgery stands among the most demanding medical specialties, characterized by an exceptionally long path to operative autonomy — one that frequently extends well beyond residency completion. Residents face sustained exposure to high-stakes decision-making, sleep deprivation, and limited control over their professional trajectory. While burnout and professional dissatisfaction have been extensively studied in Western neurosurgical training programs, no data currently exist on Tunisian neurosurgery residents, who operate under additional constraints specific to local resource availability, socioeconomic context, and a structurally uncertain post-residency landscape.

Objectives: This national cross-sectional study aims to: (1) assess the levels of professional satisfaction, burnout, and psychological wellbeing among Tunisian neurosurgery residents; (2) explore initial motivations and long-term career aspirations, including subspecialty interests and post-residency pathways; (3) characterize residents' perceptions of training strengths and structural limitations; and (4) capture their decision-making frameworks regarding the trade-offs inherent to neurosurgical practice — operative case selection, risk tolerance, procedural duration, and income expectations.

Methods: An anonymous, self-administered electronic questionnaire will be distributed to all Tunisian neurosurgery residents. The instrument incorporates validated psychometric tools — the Maslach Burnout Inventory for Health Services (MBI-HSS), the Work-related Flow Inventory (WOLF), the Dutch Work Addiction Scale (DUWAS), the French Big Five Inventory neuroticism subscale (BFI-Fr), the Generalized Anxiety Disorder scale (GAD-7), the Patient Health Questionnaire (PHQ-9), and the Insomnia Severity Index (ISI) — alongside original items probing training satisfaction, mentorship quality, material conditions, post-residency intentions (academic medicine, private practice, mixed, international, Gulf-region practice), and attitudes toward autonomy, remuneration, and case selection. Data will be analyzed using descriptive statistics, correlational analysis, and latent profile analysis.

Expected results: This survey will establish the first psychological and professional profile of the Tunisian neurosurgery resident, identify context-specific risk and protective factors, and generate evidence-based recommendations for improving training conditions, resident wellbeing, and long-term retention within the specialty.

Conclusion: At a critical juncture where neurosurgical workforce sustainability is under pressure in Tunisia, understanding the lived experience and aspirations of those in training is an essential prerequisite for meaningful systemic reform.

O50 - Beyond borders: saudi arabia's evolving model of philanthropic and global neurosurgery

Oral VI

Ibrahim Alnaami

King Khalid university,Abha, Saudi Arabia

Background: Global disparities in access to neurosurgical care remain substantial, particularly in low-resource and conflict-affected settings. Historically, philanthropic neurosurgery has largely relied on short-term, service-oriented missions with limited sustainability. In recent years, there has been a growing shift toward structured global neurosurgery models emphasizing capacity building, systems integration, and ethical accountability. Saudi Arabia has emerged as an active contributor to this evolving field through organized humanitarian efforts supported by institutional and academic neurosurgical engagement.

Methods: This presentation reviews and synthesizes Saudi-led philanthropic neurosurgical initiatives conducted across multiple regions worldwide. Initiatives were analyzed using a pragmatic design-and-implementation framework focusing on four key domains: (1) clinical service delivery and case prioritization, (2) training, mentorship, and local workforce development, (3) collaboration with host institutions and local health authorities, and (4) logistical, ethical, and governance considerations. Data sources included mission reports, institutional records, training outcomes, and documentation of partnerships with local and international collaborators. Particular emphasis was placed on program design, operational planning, and adaptation to local constraints.

Results: Saudi philanthropic neurosurgery initiatives have evolved from episodic surgical outreach toward more structured engagement incorporating longitudinal training, mentorship, and incremental system strengthening. Outcomes included the establishment of local neurosurgical workflows, skills transfer to regional surgeons and allied healthcare professionals, and improved integration with host-country healthcare systems. Common challenges included limited infrastructure, workforce shortages, security constraints, and difficulties with long-term follow-up. These challenges were addressed through phased implementation strategies, close collaboration with local stakeholders, and flexible clinical and educational models adapted to local needs.

Conclusion: The Saudi experience demonstrates that effective philanthropic and global neurosurgery depends on deliberate program design, institutional support, and sustained local engagement rather than short-term mission-based care alone. By emphasizing how initiatives are planned, implemented, and adapted in real-world settings, this experience provides a scalable and transferable framework for neurosurgical communities seeking to reduce global inequities in access to neurosurgical care.

O51 - Establishing a subthalamic nucleus deep brain stimulation program for parkinson's disease: early outcomes and complications in the first 10 patients

Oral VI

Soumia Benallag, Z. Abdellaoui, S. Chennaoui, K. Bouaita

Neurosurgery departement EHS Cherchell, Blida Faculty of medecine, Algeria

Background: Deep brain stimulation (DBS) of the subthalamic nucleus (STN) is an established therapeutic option for advanced Parkinson's disease (PD). We report our initial institutional experience, focusing on clinical outcomes and perioperative complications.

Methods: We conducted a retrospective analysis of 10 consecutive patients with advanced PD who underwent bilateral STN-DBS. All patients presented with motor fluctuations and/or dyskinesia refractory to optimized medical therapy. Procedures were performed using stereotactic techniques with intraoperative targeting. Clinical evaluation included pre- and postoperative motor assessment and documentation of complications.

Results: Postoperative follow-up showed overall improvement in motor symptoms in the majority of patients, with a reduction in dopaminergic treatment requirements. Procedure-related complications occurred in 2 patients (20%). One patient developed a postoperative intracranial hematoma leading to death. Another patient presented with a dysfunctional electrode, requiring further management. No infectious complications were observed.

Conclusions: STN-DBS is an effective therapeutic option for advanced PD, providing meaningful motor improvement. However, our experience highlights the potential for serious complications, including life-threatening hemorrhage and hardware dysfunction. These findings emphasize the importance of meticulous surgical technique, careful patient selection, and close postoperative monitoring, particularly during the early phase of adopting this technology.

O52 - Factors associated with recurrence of colloid cysts of the third ventricle: a retrospective surgical series and literature-based discussion

Oral VI

Ouared Habiba, S.Benallag, A.Meliani, A.Mati, T.Selmane, K.Bouaita.

Departement of Neurosurgery, EHS Cherchell, Tipaza, Algeria.

Background: Colloid cysts of the third ventricle are benign lesions with a potentially serious clinical course due to their proximity to the foramen of Monro and the associated risk of obstructive hydrocephalus. Recurrence remains a significant concern following treatment, particularly in the setting of incomplete cyst wall removal or inadequate long-term imaging surveillance.

Objective: To analyze recurrence in a retrospective surgical series and identify the principal factors associated with recurrence in light of the existing literature.

Methods: A retrospective review was conducted of 93 patients who underwent surgical treatment for third ventricular colloid cysts between 1997 and 2025. Surgical outcomes were compared between transcallosal microsurgery and endoscopic resection using institutional data. A focused discussion was developed based on the literature, including contemporary microsurgical recurrence data, comparative studies of microsurgical and endoscopic approaches, series of recurrent endoscopic cases, meta-analyses, and historical data on aspiration techniques.

Results: In the institutional cohort, recurrence was observed in 13 of 93 patients (15.47%), including 12 cases in the endoscopic group and 1 in the transcallosal microsurgical group. Reoperation was required in 10 endoscopic cases and 1 microsurgical case. Across the literature, recurrence appears to be influenced by duration of follow-up, extent of cyst wall removal, persistence of residual capsule, and initial surgical technique. Historical aspiration-based strategies have been associated with particularly high rates of late recurrence

Conclusion: The present series, together with the literature, suggests that recurrence following resection of third ventricular colloid cysts is multifactorial rather than attributable to a single operative variable. The most consistent determinants of recurrence include duration of follow-up, presence of residual or coagulated cyst wall, and the extent of resection. Microsurgical approaches are generally associated with lower recurrence rates but higher perioperative morbidity, whereas endoscopic techniques offer reduced immediate morbidity at the potential cost of residual remnants requiring long-term surveillance. Prolonged postoperative follow-up with serial imaging is therefore recommended, even after apparently complete resection, as recurrence may occur several years after the initial procedure.

O53 - Low cost cranial neuronavigation system based on a smartphone and PC: development assisted by artificial intelligence

Oral VI

Sofiane Imekraz, N. Frissou [2,3]

[1] Faculty of Medicine of Annaba. Annaba University Hospital. Algeria

[2] Environmental Research Center of Annaba. Algeria

[3] IFORCE Faculty of Mathematics, USTHB Algiers. Algeria

Background: Neuronavigation has become a standard in neurosurgery, but the high cost of commercial platforms limits their dissemination in low-resource settings. We report the development of a low-cost cranial neuronavigation system using a smartphone for image acquisition and a PC for 3D processing and visualization, engineered with the assistance of artificial intelligence.

Methods: The pipeline comprises: 1) import and processing of CT/MRI images in DICOM format with 3D reconstruction of the skull and surgical targets, 2) a PC-based backend for manual or semi-automatic segmentation, mesh generation and patient-to-image registration, 3) an Android application using the smartphone camera for real-time tracking of the face or fiducial markers, and 4) a network communication layer enabling projection of the 3D reconstruction as an augmented-reality overlay onto the patient. An AI assistant (large language model) was used systematically for algorithm design, code generation and bug fixing across both the mobile and PC modules, thereby accelerating development iterations.

Results: The system was tested on cranial models and 3D-printed phantoms derived from patient data. 3D reconstruction and registration were obtained reproducibly, enabling a stable AR overlay consistent with the underlying anatomy. The modular software architecture supported rapid iterative development, with a marked reduction in prototyping time attributed to AI-assisted coding and debugging.

Conclusions: This prototype demonstrates the feasibility of a low-cost cranial neuronavigation system combining a smartphone, a PC workstation and AI-assisted software development. The “surgeon-developer plus AI copilot” approach appears particularly relevant in low-resource environments. Future work will focus on integrating dedicated AI modules for automatic or advanced registration and trajectory optimization, as well as prospective clinical evaluation in patients.

O54 - Management of disabling spasticity with functional neurosurgery (selective microsurgical neurotomy)

Oral VII

Afif Afif, Hdr

Department of Neurosurgery, Department of Anatomy, INSERM U 1028, Pain Center, Pierre Wertheimer Hospital, Lyon 1 University; European Hospital, Paris, France neuro@drafifafif.com
https://www.drafifafif.com

Introduction: Spasticity is one of the most common sequelae of central neurological disorders. It is defined as a motor disorder characterized by a velocity-dependent increase in the tonic stretch reflex associated with an exaggeration of deep tendon reflexes. In a significant number of cases, spasticity can become disabling and lead to functional loss. When disabling spasticity is focused on one or a few muscle groups, selective peripheral neurotomy may be considered.

Preoperative procedures: Before undergoing these surgical programs, patients undergo a complete preoperative assessment using a block test of the targeted nerves using local anesthetics. The goal of these tests is to replicate the effects of surgery to determine potential functional improvement, which can be assessed by the patient, their family, and the medical team.

Surgical technique: After an approach tailored to the targeted nerve, the first step is microsurgical dissection of the nerve branches and the fascicles of each branch. The function of the different fascicles is then identified using bipolar or tripolar stimulation. The study of motor responses allows for the differentiation of motor fascicles from sensory fascicles, and then hyperexcited fascicles from others. After this identification, the fascicles are partially transected according to the preoperative plan. Rehabilitation is immediate and prolonged.

Results: In our series, patients who underwent selective neurotomy of the upper and lower limbs experienced significant suppression or reduction of spasticity and a reduction or disappearance of spasticity-induced pain. Functional improvement was significant (upper limb flexibility, hand and finger opening, limb reuse, improved gait and foot stability during stance and walking), with improvements in body image, comfort when dressing, and shoe fitting.

Conclusion: In the management of spasticity, selective microsurgical neurotomy has predictable effects based on preoperative testing. By eliminating excessive spasticity, correcting abnormal postures, and reducing associated pain, neurotomy allows for the resumption of active and effective rehabilitation and, in some cases, the reappearance or improvement of voluntary and useful motor skills. It is a modular and adaptable technique for each patient. It allows for the long-term reduction of focal spasticity at the cost of low morbidity.

O55 - Neurosurgical management of treatment-resistant obsessive-compulsive disorder

Oral VII

Ghassen Souissi, J. Farisse, A. Cretol, A. Balossier, J. Régis

[1]Department of Functional and Stereotactic Neurosurgery and Gamma Knife Radiosurgery, La Timone University Hospital, Marseille, France.

[2] Department of Psychiatry, La Conception University Hospital, Marseille, France.

Introduction: Obsessive-compulsive disorder (OCD) is a chronic and disabling condition. In severe treatment-resistant cases, neurosurgical interventions may provide meaningful clinical benefit by targeting CSTC circuits.

Method: We conducted a retrospective study at our institution including all consecutive patients with treatment-resistant obsessive-compulsive disorder (OCD) who underwent neurosurgical treatment between 2016 and 2023. Only patients with a postoperative follow-up of at least 2 years and up to 3 years were included in the analysis. Clinical outcomes were assessed using the Yale-Brown Obsessive Compulsive Scale (Y-BOCS). Treatment response was defined as a reduction of at least 35% in the Y-BOCS score compared with baseline, in accordance with established criteria for clinically meaningful improvement in OCD.

Results: A total of 18 patients were treated during the study period. Two patients underwent deep brain stimulation (DBS), 15 patients were treated with Gamma Knife radiosurgical anterior capsulotomy, and one patient underwent DBS followed by Gamma Knife radiosurgery. Three patients were lost to follow-up and were therefore excluded from the outcome analysis. Among the remaining 15 patients, 12 achieved a clinically significant response, defined as a reduction of at least 35% in the Yale-Brown Obsessive Compulsive Scale (Y-BOCS) score, whereas only 3 patients failed to respond to treatment. This corresponds to an overall treatment success rate of 80%. Treatment-related adverse events were rare. Two patients experienced weight gain following treatment, while no other major treatment-related complications were observed.

Conclusion: In conclusion, neurosurgical treatment appears to be an effective option for selected patients with severe treatment-resistant OCD, with most patients in our series showing meaningful clinical improvement.

O56 - Patient-specific 3D-printed molds for low-cost cranioplasty: a multicenter prospective series demonstrating an affordable alternative to custom cranial implants

Oral VII

Houssem Hdhili, F.Akrout, S.Farhat, T.Kamoun, S.Achoura, A.Harbaoui, R.Chkili, M.D.Yedeas, K.Radhouane

Department of Neurosurgery, Military Hospital of Tunis, Tunisia

Background: Cranioplasty is essential for restoring skull integrity and improving neurological and aesthetic outcomes. Custom 3D-printed titanium or PEEK implants provide excellent cosmetic results; however, their high cost limits accessibility. This study explores an affordable, patient-specific alternative using 3D printing to fabricate intraoperative molds for shaping high-viscosity bone cement.

Methods: In this prospective multicenter case series, forty-eight patients underwent cranioplasty using patient-specific, two-part, self-aligning 3D-printed molds. The molds were designed from preoperative CT scans and fabricated using 3D printing technology. High-viscosity bone cement was molded intraoperatively and implanted. Clinical, demographic, radiological, and economic data were collected. Postoperative imaging evaluated implant fitting accuracy and restoration of cranial symmetry. Aesthetic satisfaction was assessed using a five-point ordinal scale.

Results: Indications included bone flap loss following infection after empyema, decompressive craniectomy for severe traumatic brain injury, cerebral swelling after treatment of a ruptured aneurysm, calvarial tumors, bifrontal craniectomy, and malignant cerebral infarctions. Postoperative imaging confirmed accurate implant adaptation to the cranial defect, with smooth contour continuity and satisfactory symmetry compared to the contralateral side. All patients achieved excellent aesthetic outcomes (scores of 4–5/5), with no postoperative complications, including infection or implant failure. A single revision surgery was required due to implant displacement secondary to insufficient fixation. The mean material cost was approximately €300 per patient.

Conclusion: This approach demonstrates that high-viscosity bone cement shaped using low-cost, patient-specific 3D-printed molds is a safe, effective, and affordable alternative for cranioplasty. It provides excellent aesthetic results and is particularly suited to healthcare systems in resource-limited settings. Wider adoption of this technique may help democratize access to personalized cranial reconstruction.

O57 - Percutaneous radiofrequency thermocoagulation for classical trigeminal neuralgia: a 13-year single-center experience

Oral VII

Houssem Hdhili, S.Farhat, A.Belhaj, Z.Oualha, J.Kallel, S.Bouali

Neurosurgery department, nationale Institute of Neurology, Mongi Ben Hmida, Tunis, Tunisia

Background: Percutaneous radiofrequency thermocoagulation (RFT) is a well-established minimally invasive procedure for medically refractory classical trigeminal neuralgia (CTN), particularly in elderly patients or those with significant surgical comorbidities. Despite its widespread use, long-term outcome data from North African centers remain limited. We report our institutional experience, highlighting the technical aspects, efficacy, and safety of the procedure.

Methods: We retrospectively reviewed 22 consecutive patients with medically refractory CTN treated with percutaneous RFT at the National Institute of Neurology, Tunis, between January 2010 and June 2023. All procedures were performed using the Härtel approach under fluoroscopic guidance. Following cannulation of the foramen ovale, electrode positioning within the Gasserian ganglion was confirmed radiologically. Controlled thermal lesions were delivered for approximately 60 seconds with gradual temperature escalation up to 80°C, allowing selective ablation of nociceptive fibers while preserving tactile sensation. Clinical outcomes were evaluated immediately after surgery, at 1 month, between 1 month and 1 year, and beyond 1 year. Postoperative complications, need for medication, and repeat procedures were also analyzed.

Results: Immediate complete pain relief was achieved in 81.8% of patients and increased to 86.4% at one month. Complete pain relief remained stable in 77.3% during the first postoperative year and in 68.2% at long-term follow-up. Overall favorable outcomes (complete or partial pain relief) were maintained in 90.9% of patients after one year. No early treatment failures were observed. Trigeminal hypoesthesia occurred as an expected therapeutic effect and was generally well tolerated. Procedure-related morbidity was minimal, consisting of one case of anesthesia dolorosa and one transient masseter weakness. Only 13.6% of patients required low-dose carbamazepine during long-term follow-up, and repeat intervention was rarely necessary.

Conclusion: Percutaneous radiofrequency thermocoagulation is a safe, effective, and reproducible technique for the treatment of medically refractory CTN. It provides rapid pain relief, durable long-term outcomes, and a low complication rate. Accurate anatomical targeting through the Härtel approach and controlled temperature escalation are key technical factors contributing to successful treatment, making RFT an excellent surgical option, particularly for elderly or medically fragile patients.

O58 - Usefulness of awake craniotomy in tuberculoma resection in the motor area: report of two cases

Oral VII

Emna Mzoughi, Khalil Ghedira, Nesrine Chaouch, Emna Ouni, Wissal Nsiri, Insaf Dkhil, Khansa Abderrahmen

Department of neurosurgery , National Institute of Neurology, Tunisia.

Introduction: Intracranial tuberculoma remains a diagnostic and therapeutic challenge, especially when located in eloquent cortical areas. Pre-central lesions may present with focal motor or myoclonic seizures and carry a high surgical risk because of their proximity to the primary motor cortex and corticospinal tract. Awake craniotomy with intraoperative mapping allows real-time functional assessment and may help achieve maximal safe resection while reducing postoperative neurological morbidity. This work compares the outcomes of two patients operated on for pre-central brain tuberculoma, with and without awake functional mapping.

Methods: We report two female patients presenting with recurrent myoclonic seizures related to frontal pre-central tuberculomas. The first patient had a left pre-central lesion and underwent surgical excision under general anesthesia. The second patient had a right pre-central lesion and was operated on using awake craniotomy with cortical and subcortical mapping. Clinical presentation, MRI findings, surgical strategy, histopathological diagnosis, postoperative outcome, and relevant literature data were reviewed.

Results: Both patients presented with focal myoclonic seizures corresponding to the location of the pre-rolandic lesion. Brain MRI showed well-defined enhancing lesions with surrounding edema, ring or nodular enhancement, and T2 hypointensity, suggestive of caseating tuberculoma. Surgical resection was performed in both cases, and histopathological examination confirmed the diagnosis of tuberculoma. Postoperatively, both patients received antituberculous therapy. The patient operated on under general anesthesia developed a permanent postoperative motor deficit involving the right foot. In contrast, the patient operated on using awake craniotomy with functional mapping had no permanent postoperative motor deficit.

Discussion: Pre-central tuberculomas are challenging because they combine diagnostic uncertainty with a high functional risk. Although antituberculous therapy remains the cornerstone of treatment, surgery may be required for histological confirmation, mass effect, uncertain diagnosis, or medically refractory seizures. In lesions located near the motor cortex, preserving neurological function is a major objective. Awake craniotomy with cortical and subcortical mapping helps identify functional boundaries and motor pathways during surgery, which may reduce the risk of permanent postoperative deficit compared with surgery under general anesthesia.

Conclusion: Tuberculomas located in the motor area require careful clinical, radiological, and functional assessment. Awake craniotomy with intraoperative mapping appears to be a valuable strategy for safer resection and better preservation of motor function in selected cases.

O59 - Wired for pleasure: what neurosurgery teaches us about the brain's sexual plasticity

Oral VII

Ameur Affes, Barkache M, Akrout F, Rachdi Ma, Kammoun T, Farhat S, Chkili R, Radhouen K

Neurosurgery Department, Military Hospital of Tunis, Tunis, Tunisia

Background & objectives: Sexual function has long been considered a peripheral concern in neurosurgical practice. Yet evidence from functional neuroimaging, neuromodulation, and surgical lesion studies positions the brain as the primary organ of human sexuality. Neuroplasticity — the brain's capacity to reorganize its structure and function in response to experience, injury, or intervention — appears central to both the disruption and recovery of sexual function following neurosurgical pathology. This review critically examines the evidence linking cerebral plasticity to sexual function from a neurosurgical standpoint, separating established science from premature extrapolation.

Methods: Narrative review across PubMed, Scopus, and Cochrane databases (2000–2024), including fMRI studies, lesion-symptom mapping analyses, neuromodulation trials, and spinal cord injury recovery data.

Results & discussion: Lesion-based evidence: Neurosurgical pathology involving the prefrontal cortex, temporal lobes, hypothalamus, and limbic circuit consistently produces quantifiable alterations in sexual behavior — from hypersexuality in orbitofrontal lesions to complete loss of desire following hypothalamic injury — confirming that sexual function is neuroanatomically mapped and surgically vulnerable. Plasticity after spinal cord injury: Following incomplete cervical cord injury, cortical remapping of genital sensory areas has been documented on fMRI, with reorganization toward adjacent somatosensory regions. This rewiring correlates with partial recovery of erogenous sensitivity independent of peripheral nerve integrity, challenging the purely peripheral model of sexual recovery. Neuromodulation: Deep brain stimulation, spinal cord stimulation, and sacral neuromodulation produce documented effects on libido, arousal, and erectile function. DBS of the subthalamic nucleus illustrates bidirectional plastic modulation of the reward circuit, capable of both inducing and resolving hypersexuality. Structural plasticity: Gray matter volume changes in reward and limbic regions correlate with sexual experience and compulsive sexual behavior, mirroring addiction-related plasticity patterns and confirming experience-dependent remodeling of the sexual brain. Myth versus reality: Significant limitations persist — small cohorts, heterogeneous populations, and limited longitudinal data. Claims of complete cortical-driven sexual recovery currently outpace available evidence.

Conclusion: Sexual neuroplasticity is neither myth nor speculation — it is an emerging reality with direct neurosurgical implications. From pre-operative counseling before eloquent-area resections to optimizing neuromodulation targets and setting realistic expectations after spinal cord injury, understanding the brain's capacity to rewire its sexual circuitry is becoming a clinical necessity. Neurosurgery is uniquely positioned to lead this field forward.

O60 - Surgical management of mesial temporal gliomas associated with drug-resistant temporal lobe epilepsy: lesionectomy alone or combined epilepsy surgery? a four-case series

Oral VIII

Maatoug Ahmed, Bsili Lassaad
OLIVIER CLINIC, SOUSSE, TUNISIA

Background: Mesial temporal gliomas are an important cause of drug-resistant temporal lobe epilepsy (TLE). While lesionectomy remains the cornerstone of surgical treatment, the necessity of additional resection of mesial temporal epileptogenic structures, including the amygdala and hippocampus, remains controversial. We report our experience with four patients harboring mesial temporal gliomas presenting with refractory epilepsy and discuss the extent of surgical resection in light of current literature.

Methods: Four patients with mesial temporal gliomas and drug-resistant TLE underwent surgical treatment. Two pediatric patients underwent lesionectomy combined with amygdalohippocampectomy. A third adolescent patient underwent lesionectomy with temporo-amygdalectomy. The fourth patient, an adult with a dominant mesial temporal lesion, underwent lesionectomy through a paramedian supracerebellar transtentorial approach, aiming to preserve mesial temporal structures.

Results: The two pediatric patients and the adolescent patient achieved excellent postoperative seizure control, remaining seizure-free during follow-up. In contrast, the adult patient continued to experience disabling seizures after lesionectomy alone despite satisfactory tumor resection. Given the persistence of epilepsy, a complementary amygdalohippocampectomy has been proposed as a second-stage procedure. No major postoperative neurological deficits were observed in this series.

Discussion: This series highlights the ongoing debate regarding the optimal surgical strategy for mesial temporal gliomas associated with refractory epilepsy. While lesionectomy alone may be sufficient in selected patients, accumulating evidence suggests that combining tumor removal with resection of mesial temporal epileptogenic structures may improve seizure outcomes, particularly when long-standing epilepsy or hippocampal involvement is present. The indications for lesionectomy alone, lesionectomy with amygdalohippocampectomy, or more extensive temporo-amygdalohippocampectomy will be reviewed and discussed according to current literature.

Conclusion: Excellent seizure outcomes were obtained in patients treated with lesionectomy combined with tailored epilepsy surgery. Persistent postoperative seizures following lesionectomy alone in one patient underscore the importance of careful preoperative evaluation and individualized surgical planning. Further studies are required to define the optimal extent of resection in mesial temporal gliomas associated with drug-resistant epilepsy.

O61 - Epidemiological and histopathological profile of primary CNS tumors in eastern morocco: a 5-year review of 120 cases

Oral VIII

Mohammed Al Amine El Farissi, Mohamed Dahamou[1], Hamid Khay[1], Khoulali Mohamed, Anas Haloui[2], Amal Benani[2]

[1] Department of Neurosurgery, Mohammed VI University Hospital, Faculty of Medicine and Pharmacy of Oujda, Mohammed First University, Oujda, Morocco. /

[2] Laboratory of Pathological Anatomy, Mohammed VI University Hospital, Faculty of Medicine and Pharmacy of Oujda, Mohammed First University, Oujda, Morocco.

Background: Primary central nervous system (CNS) tumors comprise a heterogeneous group of neoplasms associated with disproportionately high global morbidity and mortality. Characterizing their regional epidemiological and histopathological distribution is critical to refining neuro-oncological management and resource allocation. However, comprehensive data regarding North African populations remain scarce. This study establishes the first baseline profile of primary CNS tumors in Eastern Morocco.

Methods: A retrospective descriptive study was conducted on all histologically confirmed primary CNS tumors diagnosed at the Mohammed VI University Hospital Center in Oujda, Morocco, over a five-year period (2021–2025). Demographic, clinical, and histopathological data were comprehensively analyzed and classified according to the updated 2021 World Health Organization (WHO) Classification of CNS Tumors.

Results: A total of 120 cases were evaluated. The median age at diagnosis was 40.6 years, with adults (40–64 years) . An overall male predominance was observed (sex ratio: 1.14). Topographical Distribution: Tumor location varied significantly across age categories (χ^2 = 19.3, $p < 0.001$). Infratentorial tumors heavily predominated in pediatric patients, whereas supratentorial and locations clustered in adult and elderly. Histopathology & Demographics: Adult-type diffuse gliomas (32.5%) and meningiomas (20.8%) were the most prevalent tumor groups. Tumor type was significantly associated with age (χ^2 = 141.0, $p < 0.001$); glioblastomas and meningiomas peaked in late adulthood, while pilocytic astrocytomas and medulloblastomas demonstrated a stark pediatric predilection. Compared to Western literature, this cohort demonstrates a markedly younger median age at diagnosis, a reversed sex ratio, and an elevated proportion of pediatric malignancies.

Conclusion: This study provides the first comprehensive overview of the primary CNS tumor landscape in Eastern Morocco. While aligning with national trends, our findings reveal a distinct regional epidemiological profile compared to Western series. These data contribute a vital benchmark to the North African neuro-oncological literature and support the integration of advanced diagnostic platforms in low- and middle-income settings.

O62 - Awake craniotomy with functional mapping and intraoperative ultrasound for glioma resection: maximizing extent of resection while preserving neurological function

Oral VIII

Kamel Bouaita, S. Benallag, N. Baz, A

Neurosurgery departement EHS Cherchell, Blida Faculty of medecine, Algeria

Background: Maximal safe resection is a major objective in glioma surgery, particularly for tumors involving eloquent brain regions. Awake craniotomy with cortical and subcortical mapping enables real-time functional assessment, while intraoperative ultrasound (IOUS) provides dynamic anatomical guidance throughout resection. This study reports our experience with the combined use of awake mapping and IOUS in glioma surgery.

Methods: A retrospective analysis was performed on 35 patients who underwent awake craniotomy for glioma resection. The cohort included 24 men and 11 women. Tumor locations involved the rolandic region in 17 patients, speech-eloquent areas in 9 patients, and other eloquent cortical or subcortical regions in the remaining cases. Intraoperative cortical and subcortical mapping was combined with ultrasound guidance for tumor localization, assessment of brain shift, and detection of residual tumor. Extent of resection and postoperative neurological outcomes were evaluated.

Results: All patients underwent successful awake mapping and ultrasound-guided resection. Gross total resection was achieved in 21 patients (60%), while the remaining 14 patients underwent subtotal or partial resection due to functional limitations encountered during surgery. Postoperatively, 18 patients (51.4%) experienced no new neurological deficit. Transient neurological deficits were observed in 15 patients (42.9%) and improved during follow-up. Permanent neurological deficits occurred in 2 patients (5.7%). No perioperative mortality was recorded. Intraoperative ultrasound provided reliable real-time visualization of tumor boundaries and facilitated adjustment for brain shift, contributing to safe resection near eloquent structures.

Conclusion: The combination of awake craniotomy, functional mapping, and intraoperative ultrasound represents a safe and effective strategy for glioma surgery in eloquent brain regions. This multimodal approach facilitates maximal safe resection while preserving neurological function, resulting in a high rate of gross total resection and a low incidence of permanent deficits.

O63 - Management of parasagittal meningiomas: multimodal strategies and risk stratification in the era of molecular classification.

Oral VIII

Messai Saddem, Mechiche Zohir, Mahdaoui Rima, Hallaci Azeddine .

Neurosurgery Department, SETIF, Algeria.

Introduction: Parasagittal meningiomas (PSMs) represent a major neurosurgical challenge due to their proximity to or invasion of the superior sagittal sinus (SSS). While maximal surgical resection remains the gold standard treatment, the paradigm is shifting from systematic surgical aggressiveness toward a more conservative multimodal strategy followed by radiosurgery, now guided by advances in molecular biology.

Objectives: To evaluate the impact of integrating molecular profiles and multimodal management (surgery and radiosurgery) on long-term tumor control and functional preservation in PSMs.

Methods: We analyze a retrospective and prospective cohort of patients operated on for PSMs. Tumors underwent stratification combining the classic histopathological WHO classification with molecular profiling, Ki-67 proliferation index, and CDKN2A/B status. Therapeutic strategies included surgical resection (Simpson grades II–IV) combined with early or salvage stereotactic radiosurgery (SRS) for invasive remnants within the SSS.

Results: The integration of molecular classification allowed for the restratification of 18% of tumors initially classified as WHO grade 1 into "high-risk" recurrence groups. For PSMs invading the SSS, subtotal resection (Simpson grade IV) followed by targeted SRS on the sinus remnant demonstrated a 5-year local control rate equivalent to aggressive resection (Simpson grades I–II), while significantly reducing the risk of venous complications and postoperative neurological deficits. Aggressive molecular subgroups benefited from closer radiological surveillance and early adjuvant irradiation.

Conclusion: The management of PSMs should no longer rely solely on histological grade and the extent of resection. A personalized multimodal strategy that preserves the SSS and is guided by molecular risk stratification optimizes tumor control while minimizing functional morbidity.

O64 - Surgical management of central nervous system hemangioblastomas: a 32-case experience

Oral VIII

Hallaci Azzedine, D.Hallaci, S.Messai, R.Mahdaoui, Z.Mechiche.

Neurosurgery Department, SETIF, Algeria.

Background: Hemangioblastomas are rare, highly vascularized, benign tumors of the central nervous system, often associated with Von Hippel-Lindau (VHL) disease or occurring sporadically. Because of their hypervascular nature and frequent localization in critical areas like the posterior fossa and spinal cord, surgical resection remains highly challenging. This study evaluates the clinical features, surgical strategies, and outcomes of patients operated on for hemangioblastomas.

Methods: We conducted a retrospective study of 32 patients who underwent surgical resection for central nervous system hemangioblastomas in our neurosurgery department. Clinical presentation, radiological findings, surgical techniques , and postoperative outcomes were analyzed.

Results: The cohort included 32 cases, with a predominance of cerebellar locations . Complete microsurgical resection was achieved in the majority of cases . Postoperative complications were carefully managed, with a significant long-term improvement in neurological status observed in most patients. Recurrence was rare and primarily observed in patients with underlying VHL disease.

Conclusion: Total microsurgical resection is the gold standard treatment for hemangioblastomas, offering excellent long-term tumor control and neurological recovery. A meticulous, step-by-step microdissection technique, preserving the surrounding arachnoid plane and controlling tumor feeders before draining veins, is essential to minimize bleeding and secure a safe, complete excision.

O65 - Posterior fossa tumors: a comparative study between pediatric and adult populations

Oral VIII

Ines Ferchichi, Mohamed Amine Hadj Taieb, Nader Yahyaoui, Mehdi Darmoul

Neurosurgery Departement of Fattouma Bourguiba University Hospital, Monastir, Tunisia

Background: Tumors of the posterior cranial fossa (PCF) differ significantly between children and adults in terms of epidemiology, clinical presentation, histology, management, and outcomes. This study aims to compare these characteristics between two cohorts of pediatric and adult patients treated in a single neurosurgical center.

Methods: We conducted a retrospective comparative study including 52 patients operated on for posterior fossa tumors at the Neurosurgery Department of Fattouma Bourguiba University Hospital, Monastir, between 2000 and 2013. The cohort included 24 children and 28 adults. Clinical records, imaging data, surgical reports, histopathological findings, postoperative outcomes, and long-term follow-up were analyzed. Variables assessed included demographic characteristics, presenting symptoms, tumor location and size, presence of hydrocephalus, extent of resection, histological type, postoperative complications, survival, and prognostic factors.

Results: The mean age was 7 years in the pediatric group and 45 years in the adult group. There was a slight female predominance among children and a slight male predominance among adults. Intracranial hypertension was the most common presenting symptom in both groups (87.5% in children vs 82.1% in adults), while cerebellar syndrome was the most frequent clinical sign (75% vs 67.9%, respectively). Neuroimaging revealed predominantly intra-axial tumors in children (87%) compared to adults (57%). Mean tumor size was 4.35 cm in children and 3.77 cm in adults. Hydrocephalus was present in all children and in 50% of adults, requiring treatment in 50% and 40%, respectively. Gross total or subtotal resection was achieved in 91.2% of children and 85.7% of adults. The most common histological types were medulloblastoma in children (38%) and meningioma in adults (21.7%). Postoperative complications were mainly neurological deficits (45.5% in children vs 29.2% in adults). At long-term follow-up, 9% of children and 29.2% of adults had persistent sequelae, while mortality rates were 31.8% and 25%, respectively. Mean overall survival was 1.8 years in children and 4.28 years in adults.

Conclusion: Posterior fossa tumors demonstrate distinct pediatric and adult profiles in terms of tumor biology, presentation, and outcomes. Prognosis appears to be influenced mainly by the extent of surgical resection in children and tumor intra-axial location in adults, highlighting the need for tailored management strategies in both populations.

O66 - Surgery for brain metastases: which patients gain the greatest survival benefit?

Oral VIII

Majdouline Barkache, R.Benfredj, A.Affes, H.Kammoun, I.Kisra

Department of Neurosurgery, Sahloul Hospital, Sousse, Tunisia

Background: Brain metastases are the most common intracranial tumors in adults and represent a major cause of morbidity and mortality in oncological patients. Despite advances in systemic therapies and radiosurgery, surgical resection remains a key treatment modality in selected cases. However, the survival benefit of surgery is not uniform across all patients. This narrative review aims to synthesize current evidence on which patient subgroups derive the greatest survival benefit from surgical management of brain metastases.

Methods: A narrative review of the literature published between 2010 and 2025 was performed using major databases including PubMed and Google Scholar. Studies evaluating survival outcomes after surgical resection of brain metastases were analyzed, with particular focus on prognostic factors such as patient performance status, number of lesions, extracranial disease control, primary tumor histology, and use of adjuvant therapies. Randomized trials, retrospective cohort studies, and large institutional series were included.

Results: Across studies, median overall survival after surgery ranged from 8 to 18 months depending on patient selection. Consistently, patients with a single brain metastasis, good neurological and functional status (Karnofsky Performance Status ≥70–80), and controlled systemic disease experienced the most significant survival benefit. Surgical resection provided improved local control and symptom relief, particularly in cases of large, symptomatic, or accessible lesions causing mass effect. Favorable outcomes were further enhanced when surgery was combined with postoperative stereotactic radiosurgery. In contrast, patients with multiple metastases, uncontrolled extracranial disease, or poor performance status derived limited survival benefit and were better candidates for non-surgical approaches.

Conclusions: The survival benefit of surgery for brain metastases is highly dependent on careful patient selection. The greatest benefit is observed in patients with single, resectable lesions, preserved functional status, and controlled systemic disease. Multidisciplinary decision-making remains essential to tailor treatment strategies and optimize outcomes in this heterogeneous population.

O67 - Glioblastoma in the elderly: who benefits from aggressive treatment?

Oral VIII

Majdouline Barkache, R.Ben Fredj, H. Kmmoun, A. Hmida, I. Kisra

Department of Neurosurgery, Sahloul Hospital, Sousse, Tunisia

Background: Glioblastoma (GBM) in elderly patients represents a major therapeutic challenge due to increased comorbidities, reduced physiological reserve, and generally poorer prognosis. While standard treatment consists of maximal safe resection followed by radiotherapy and temozolomide, the benefit of aggressive multimodal therapy in the elderly remains controversial. This narrative review aims to identify which elderly patients may benefit from aggressive treatment strategies.

Methods: A narrative review of the literature published between 2010 and 2025 was performed using PubMed and relevant neurosurgical and oncology journals. Studies evaluating outcomes of elderly GBM patients (commonly defined as ≥65 years) treated with surgery, radiotherapy, and chemotherapy were analyzed. Particular attention was given to prognostic factors including performance status, molecular markers (MGMT promoter methylation), extent of resection, and treatment intensity.

Results: Across studies, median overall survival in elderly GBM patients ranged from 4 to 12 months depending on treatment strategy and selection criteria. Patients with good preoperative functional status (Karnofsky Performance Status ≥70), MGMT promoter methylation, and ability to undergo maximal safe resection demonstrated the most significant survival benefit from aggressive treatment. Hypofractionated radiotherapy combined with temozolomide improved outcomes compared to radiotherapy alone in selected patients. Conversely, patients with poor performance status (KPS <60), significant comorbidities, or unresectable deep-seated tumors derived limited benefit from aggressive approaches, with best supportive care or short-course radiotherapy often being more appropriate.

Conclusions: Aggressive treatment for glioblastoma in the elderly should be individualized. The greatest benefit is observed in patients with good functional status and favorable molecular profiles, particularly MGMT methylation. Careful selection remains essential to balance survival benefit, treatment toxicity, and quality of life.

O68 - Gamma knife radiosurgery role in the management of brain stem cavernous angiomas

Oral VIII

Essam Eldein Abdelkawy, Ahmed Ragab Abdelsalam, M.Sc., Ayman Abd Elraouf Abd Elghafar Elshazly MD, Ahmed Faisal Tobar MD, Ahmad Mohamed Abd Raheim Elsabaa MD, Sameh Roshdy Tawadros MD

Department of Neurosurgery, Faculty of Medicine, Ain Shams University, Egypt

Background: Cavernous angioma or cavernoma is a benign vascular malformation, which can be found at any region within the brain. Brain stem cavernous angioma is rare. Although the optimal management of intracranial cavernous angiomas is open resection, Gamma Knife radiosurgery has played an important role in treating these deeply seated and high surgical risk malformations throughout the past 20 years.

Aim of the study: Our study aimed to evaluate the efficacy, and safety of Gamma Knife radiosurgery (GKR) in the management of brainstem cavernous angiomas. Case presentation: The authors reported 22 patients at Gamma Knife center, Nasser Institute. Evaluating the efficacy and side effects of Gamma Knife radiosurgery in the treatment of brainstem cavernous angiomas

Conclusion: As the development of stereotaxic radiosurgery and more experience accumulated, GKR has become an effective and safe alternative method for brainstem cavernous angiomas treatment.

O69 - Acute spinal cord injury management integrating evidence, guidelines, and controversies

Oral IX

Riadh Rebai

King Fahd hospital, Second health cluster, Jeddah; kSA

Acute spinal cord injury (SCI) demands time-sensitive intervention to optimize neurological recovery. Current guidelines strongly recommend early surgical decompression (within 24 hours), maintenance of mean arterial pressure (85–90 mmHg) for 3–7 days, and avoidance of hypotension. High-dose methylprednisolone remains controversial. Key prognosticating factors include baseline ASIA Impairment Scale grade (especially complete injury at presentation), age, injury level, and intramedullary hemorrhage length on MRI. Emerging biomarkers (e.g., serum S100B, GFAP) show promise but lack clinical adoption. The newly introduced intraoperative based ultrasound perfusion evaluation appears as a promising prognosticating tool. Ongoing controversies center on optimal blood pressure targets, the role of cerebrospinal fluid drainage, and varying surgical timing thresholds across centers. A personalized approach integrating evidence-based protocols, shared decision-making on steroids, and early prognostic stratification is essential for improving outcomes and guiding realistic recovery expectations.

O70 - Penetrating traumatic adult brain injury in the north of palestine: analysis of 380 cases at one year post injury

Oral IX

Mazhar Darwazeh, Rami Darwazeh

Specialized Arab Hospital (SAH) - Nablus - Palestine

Background: Traumatic brain injury (TBI) remains a significant cause of morbidity and mortality in Palestine, particularly as a result of bullet-induced head injuries. Despite the clinical importance of this condition, the available literature remains limited. During the Palestinian uprising (Intifada), a large number of patients with bullet-induced TBI were managed, providing a unique opportunity to evaluate their clinical characteristics and outcomes. This study reviews the etiology, patterns of injury, diagnostic modalities, treatment strategies and prognosis of bullet-induced TBI with particular emphasis on the dynamic changes observed on serial brain CT scans.

Methods and materials: A total of 380 adult patients with bullet-induced traumatic brain injury were evaluated over a four-year period. Patients were categorized according to age, sex, mechanism of injury, type of lesion, level of consciousness, radiological findings, neurological deficits and treatment modality. The Glasgow Coma Scale (GCS) was used to assess the level of consciousness at presentation, while outcomes were evaluated using the Glasgow Outcome Scale (GOS). Special attention was given to cases demonstrating spontaneous migration of retained intracranial missile fragments.

Results: The presenting clinical manifestations were systematically analyzed. Surgical intervention was required in 100 patients. Among these, 56 patients died, 26 achieved favorable outcomes, 2 remained in a vegetative state, and 16 developed severe disability. Spontaneous migration of retained intracranial missile fragments was observed in 16 patients. The remaining patients were managed conservatively; all survived except for 2 who developed severe disability. Serial CT imaging proved valuable in monitoring the evolution of cerebral lesions and guiding management decisions.

Conclusion: Craniectomy and craniotomy with bone flap removal were the most frequently performed surgical procedures. Brain CT scanning was indispensable for identifying the type, location, extent and progression of cerebral injuries and for guiding treatment decisions. The level of consciousness at presentation, severity of brain injury and treatment modality were the principal prognostic factors influencing patient outcomes. Spontaneous migration of retained intracranial missile fragments, although uncommon, represents an important phenomenon that should be recognized during follow-up and radiological assessment.

O71 - Low cost personalized cranioplasty for post traumatic cranial defects using a desktop 3D printer: a 30 patient series.

Oral IX

Sofiane Imekraz, S. Farfar, M. Bouaziz

Faculty of Medicine of Annaba. Neurosurgery Department. Annaba University Hospital. Algeria

Background: Post-traumatic cranial defects after decompressive craniectomy are frequent in neurotrauma and are associated with cosmetic, functional and protective issues. They compromise cerebral protection, may aggravate neurological dysfunction and alter cranial symmetry, with a negative impact on appearance, self-esteem and social reintegration. In many low-resource environments, access to custom titanium implants or high-end patient-specific prostheses is limited by cost and logistics. There is therefore a need for simple, affordable techniques that still provide reliable cosmetic and protective results.

Methods: We developed a low-cost, personalized cranioplasty technique using desktop 3D printing and intraoperative bone cement molding. Preoperative CT scans (DICOM) were used to segment the skull, generate a 3D model and virtually reconstruct the ideal cranial contour. From this virtual reconstruction, a negative, patient-specific mold was designed and printed on a standard desktop 3D printer using inexpensive polymer filament. After sterilization, the mold was used intraoperatively: bone cement was applied into the mold to create a personalized cranial implant, which was then demolded, minimally adjusted if required, and fixed to the surrounding bone. Operative time, ease of intraoperative handling, need for additional trimming, early and late complications, and cosmetic outcomes were assessed.

Results: This technique was applied in 30 neurotrauma patients with post-traumatic cranial defects. All patients underwent successful cranioplasty with accurate anatomical coverage of the defect. The 3D-printed molds enabled rapid and reproducible intraoperative fabrication of the implant, with minimal need for manual trimming. No major implant-related complications were observed during follow-up. Cosmetic outcomes were consistently rated as satisfactory to excellent by both surgeons and patients, with restoration of cranial symmetry and visible improvement in appearance.

Conclusions: Using desktop 3D-printed molds to guide intraoperative bone cement cranioplasty is a simple, rapid and inexpensive method for reconstruction of post-traumatic cranial defects. This approach provides reliable cosmetic outcomes without the cost of titanium or high-end custom implants, making it particularly attractive for neurotrauma care in low-resource environments.

O72 - Operated thoracolumbar spine trauma: epidemiological and outcome profile in the neurosurgery department of oujda university hospital

Oral IX

Mohammed Al Amine El Farissi, Mohamed Dahamou, Hamid Khay, Khoulali Mohamed.

Department of Neurosurgery, Mohammed VI University Hospital, Faculty of Medicine and Pharmacy of Oujda, Mohammed First University, Oujda, Morocco.

Introduction: Thoracolumbar spine trauma (TLST) is a common condition, responsible for potentially severe lesions that affect both functional and vital prognosis. Modern imaging (standard radiography, CT scan, MRI) is crucial for anatomo-pathological analysis and guides the therapeutic strategy. Management is based on a triad combining medical, surgical, and rehabilitation treatment. The objective of this study is to describe the epidemiological and outcome profile of patients operated on for TLST in our context.

Materials and methods: This is a retrospective study, conducted in the neurosurgery department of the University Hospital of Oujda, including all patients operated on for TLST over a 5-year period (2020-2025). Inclusion criteria were all patients presenting with TLST who underwent surgical treatment. Patients treated orthopedically were excluded. We analyzed the epidemiological, clinical, therapeutic, and outcome data of 120 medical records.

Results: Sex: Male predominance (sex ratio 3.16). Age: Bimodal distribution (30-39 years and 50-59 years). Mechanism: Falls (49%) > Road traffic accidents (36%). Seasonal variation: Bimodal summer peak (June, August). Presenting symptoms: Spinal syndrome (64%), neurological deficit, consciousness disorders. Clinical (Frankel grade): Grade E dominated (64%, vertebral trauma without deficit); Frankel A (12%). Imaging: Whole-body CT scan (46%), MRI (9%). Predominant lesions at the thoracolumbar junction (46%). Magerl classification: Majority type A (A1-A3). Associated injuries: Isolated spinal injury (52%); lower limb fractures, craniofacial and abdominal injuries. Surgical management: 79% underwent posterior arthrodesis, 15% vertebroplasty, 6% kyphoplasty. Postoperative outcome: Stable neurological status (76%), improvement (9%), worsening (9%), death (6%). Complications (17%): Urinary tract infection (30%), pressure ulcers (25%).

Conclusion: TLST is highly frequent, with a summer peak. Prognosis remains guarded. Immediate management improves recovery chances. Rehabilitation is a cornerstone of the therapeutic approach.

O73 - Management of penetrating transfixing traumatic brain injury at the ouahigouya regional university hospital (burkina faso)

Oral IX

Wendlasida Serge Pacôme Arnauld Yameogo, Zongo Adama[2], Biogo Wend-Toin Joseph[1], Pasgo Ismael[3], Congo Judicael[4], Tapsoba Franck William[2], Sawadogo Benjamin[1], Mehouno Martine[1], Zabsonre Denlewende Sylvain[5].

[1] Neurosurgery Department of the Ouahigouya Regional University Hospital, BURKINA FASO

[2] Anesthesia and Intensive Care Unit of the Ouahigouya Regional University Hospital, BURKINA FASO

[3] Pediatric Surgery Department of the Ouahigouya Regional University Hospital, BURKINA FASO

[4] Medical Imaging Department of the Ouahigouya Regional University Hospital, BURKINA FASO

[5] Neurosurgery Department of the Yalgado OUEDRAOGO University Hospital, BURKINA FASO

Introduction: A penetrating transfixing traumatic brain injury is characterized by a projectile or object penetrating the skull completely, with an entry and exit wound. It constitutes an absolute neurosurgical emergency. We report a case of a penetrating transfixing traumatic brain injury treated at the Ouahigouya Regional University Hospital.

Observation: We report the case of a 20-year-old female patient residing in a rural area of Burkina Faso. While asleep, she was struck on the head with a pickaxe by a person with mental health issues. This resulted in an initial loss of consciousness. She was admitted to the surgical emergency department of the Ouahigouya Regional University Hospital Center five hours after the injury. The patient was conscious. Motor function testing was difficult. A cranio-encephalic computed tomography (CT) scan revealed frontal lobe lesions with a significant metallic artifact. A craniectomy was performed, along with iron removal, debridement of necrotic tissue, dural repair, and skin closure. In the immediate postoperative period, a motor deficit was observed, which gradually resolved during hospitalization. The postoperative course was uneventful. The neurological examination one month postoperatively was normal.

Conclusion: Penetrating transfixing traumatic brain injuries are rare. The prognosis depends on the areas of the brain involved and the speed of medical and surgical intervention.

O74 - To drill or not to drill: ICP monitoring versus transcranial doppler in the surveillance of comatose TBI patients

Oral IX

Maryem Khayat, Affes A, Akrout F, Rachdi Ma, Bouzouita K, Chkili R, Radhouen K

Neurosurgery Department, Military Hospital of Tunis, Tunis, Tunisia

Background & objectives: Intracranial pressure monitoring (ICP) and transcranial Doppler ultrasonography (TCD) stand as the two cornerstones of cerebral surveillance in comatose traumatic brain injury (TBI) patients. The choice between an invasive, quantitative pressure monitor and a non-invasive, dynamic vascular assessment tool remains one of the most debated questions in neurocritical care. This review critically appraises current evidence to determine whether one modality should be favored, and under which clinical circumstances.

Methods: Narrative review of PubMed and Scopus databases (2000–2024), including randomized controlled trials, prospective cohort studies, and major neuromonitoring guidelines (Brain Trauma Foundation, NCS, ESICM).

Results & discussion: ICP monitoring: Continuous quantitative pressure data with established prognostic value remains the Brain Trauma Foundation standard for severe TBI (GCS ≤ 8, abnormal CT). The BEST TRIP trial, however, challenged its superiority over imaging-guided management alone, tempering the assumption that ICP monitoring unconditionally improves outcomes. Invasiveness, hemorrhagic risk, infection, and resource dependency limit its universal applicability. Transcranial Doppler: TCD provides non-invasive, repeatable assessment of cerebral blood flow velocities, pulsatility index, and autoregulation status. Its correlation with elevated ICP — particularly through pulsatility index thresholds — yields acceptable sensitivity (78–89%) and specificity (81–94%) for non-invasive ICP estimation. TCD additionally captures vasospasm, autoregulation failure, and circulatory arrest, parameters entirely invisible to pressure probes. Current evidence synthesis: Neither modality comprehensively addresses the complexity of post-traumatic cerebral hemodynamics alone. Emerging data support a multimodal surveillance strategy in which ICP monitoring anchors quantitative pressure management while TCD provides dynamic vascular context, guides therapeutic titration, and substitutes when invasive monitoring is contraindicated or unavailable.

Conclusion: The drill is not always necessary — but neither is it obsolete. Current evidence supports neither unconditional ICP monitoring nor TCD as a standalone substitute. A context-driven, multimodal approach integrating both tools represents the most defensible strategy for the comatose TBI patient in 2024.

O75 - MRI predictors of neurological recovery after subaxial cervical spine trauma

Oral IX

Mohamed Amine Hmida, K.Maamri, R.Benmhenni, M.Alikhelifa, K.Bouattour, M.Darmoul

Neurosurgery Department, Fattouma Bourguiba University Hospital of Monastir, Tunisia

Introduction: While computed tomography (CT) remains the gold standard for the initial assessment of osseous injuries, magnetic resonance imaging (MRI) has become indispensable for evaluating spinal cord and soft-tissue damage following cervical spine trauma. Beyond lesion detection, MRI provides unique insight into intramedullary pathology and ligamentous integrity. The relationship between specific MRI findings and long-term neurological recovery remains a major focus of contemporary spinal cord injury research.

Objective: To assess the prognostic value of spinal cord and disco-ligamentous MRI findings in predicting neurological recovery six months after subaxial cervical spine trauma.

Materials and methods: A retrospective study was conducted on 34 patients with subaxial cervical spine injuries. MRI was successfully performed in 88.2% of cases, while the remaining patients were excluded because of hemodynamic instability or MRI contraindications. Three principal MRI biomarkers were analyzed:Spinal cord edema: T2-weighted hyperintensity without a central hypointense component. Intramedullary hemorrhage: Presence of a central T2 hypointense signal consistent with hemorrhagic injury. Disco-ligamentous injury: Disruption of the anterior longitudinal ligament and/or the posterior ligamentous complex. Neurological outcomes were assessed using changes in the American Spinal Injury Association (ASIA) Impairment Scale at six months.

Results: MRI findings demonstrated strong prognostic value and outperformed initial clinical assessment alone in predicting neurological recovery. Among patients presenting with isolated spinal cord edema, 61.1% experienced significant neurological improvement during follow-up, suggesting the presence of potentially reversible spinal cord injury when timely decompression is achieved. In contrast, none of the patients with intramedullary hemorrhage achieved meaningful motor recovery. This subgroup exhibited the highest rates of mortality and severe permanent disability, including persistent tetraplegia. Extensive disco-ligamentous injuries were associated with chronic spinal instability, frequently requiring combined anterior and posterior surgical stabilization and resulting in poorer overall outcomes.

Conclusion: MRI is more than a diagnostic imaging modality; it is a powerful prognostic tool in subaxial cervical spine trauma. The distinction between spinal cord edema and intramedullary hemorrhage enables early stratification of neurological recovery potential and facilitates realistic prognostic counseling. Routine integration of MRI into acute trauma protocols may optimize therapeutic decision-making and improve rehabilitation planning.

O76 - Awake but safe: patient selection and psychological preparation for awake craniotomy

Oral IX

Ameur Affes, Rachdi M.A., Hdhili H, Bouzouita K, Achoura S, Chkili Ridha, Radhouen K.

Neurosurgery Department, Military Hospital of Tunis, Tunis, Tunisia

Background & objectives: Awake craniotomy with intraoperative brain mapping has become the gold standard for resection of tumors and epileptic foci in eloquent cortical areas, enabling real-time neurological monitoring while maximizing safe resection extent. However, patient cooperation throughout the procedure is the technique's critical prerequisite — and its most vulnerable element. Inadequate psychological preparation, patient anxiety, and intraoperative conversion to general anesthesia compromise both safety and oncological outcomes. This review examines current evidence on optimal patient selection and psychological preparation for awake craniotomy.

Methods: Narrative review of PubMed, Scopus, and Cochrane databases (2005–2024), including prospective cohort studies, psychological assessment reports, and anesthetic protocol analyses addressing awake craniotomy candidacy, preparation protocols, and intraoperative cooperation outcomes.

Results & discussion: Selection criteria: Optimal candidates demonstrate tumor or epileptic focus within or adjacent to eloquent cortex, ability to cooperate with neurological testing, absence of severe anxiety or claustrophobia, no significant cognitive impairment precluding task performance, and absence of obstructive sleep apnea compromising airway management during awake phases. Psychological preparation: Structured preoperative visits including surgical suite familiarization, task rehearsal, anxiety management coaching, and explicit expectation-setting significantly reduce intraoperative anxiety scores and conversion rates. Neuropsychological baseline assessment identifies patients at risk of intraoperative cognitive fatigue or testing failure. Anesthetic protocol: Asleep-awake-asleep technique with dexmedetomidine and propofol infusion represents the current standard, offering cooperative wakefulness during mapping phases while maintaining analgesic coverage and airway reflexes throughout. Intraoperative failure predictors: Preoperative anxiety scores above validated thresholds, language dominance uncertainty, and tumor proximity to primary motor cortex are independently associated with increased conversion rates and incomplete mapping.

Conclusion: Awake craniotomy success is determined preoperatively. Rigorous psychological selection, structured familiarization protocols, and individualized anesthetic planning are as critical to outcome as surgical technique, transforming patient cooperation from a variable into a controllable surgical parameter.

O77 - How much is enough? balancing oncological radicality and functional preservation in awake craniotomy for glioma

Oral IX

Ameur Affes, Rachdi M.A., Hdhili H, Bouzouita K, Achoura S, Chkili Ridha, Radhouen K.

Neurosurgery Department, Military Hospital of Tunis, Tunis, Tunisia

Background & objectives: Awake craniotomy for glioma resection in eloquent areas embodies the fundamental neurosurgical tension between oncological radicality and neurological function preservation. Extent of resection directly impacts survival in both low- and high-grade gliomas, while permanent neurological deficits profoundly compromise quality of life and patient-reported outcomes. Defining the optimal resection boundary — beyond which oncological gain no longer justifies functional risk — remains the central unresolved challenge of glioma surgery in eloquent areas. This review critically examines current evidence balancing extent of resection and functional outcomes in awake glioma surgery.

Methods: Narrative review of PubMed, Scopus, and Cochrane databases (2005–2024), including prospective survival analyses, extent of resection outcome studies, and functional outcome reports in awake craniotomy for eloquent-area glioma resection.

Results & discussion: Oncological evidence: Supratotal resection achieving greater than 98% volumetric removal is associated with significantly prolonged progression-free and overall survival in both LGG and GBM series, with each 10% increase in extent of resection conferring measurable survival benefit independent of adjuvant therapy. Functional boundaries: Direct cortical and subcortical stimulation mapping identifies functional boundaries dynamically, enabling resection up to — but not beyond — sites producing positive neurological responses. Subcortical white matter mapping of corticospinal and arcuate fasciculus tracts defines the true functional surgical margin. Postoperative deficits: Transient neurological deficits occur in 20–30% of awake craniotomy cases; permanent deficits are consistently reported below 5% in experienced centers, validating the technique's functional preservation superiority over surgery under general anesthesia in eloquent areas. Neuroplasticity and staged resection: Deliberate subtotal resection followed by rehabilitation-induced neuroplastic reorganization and planned second-look surgery represents an emerging strategy extending resection safely beyond initial functional boundaries.

Conclusion: Awake craniotomy optimizes the oncological-functional balance in eloquent glioma surgery, achieving maximal safe resection with permanent deficit rates below 5%. Dynamic intraoperative mapping, not anatomical landmarks, defines the true resection boundary.

O78 - High-Grade Intracranial Meningiomas: A 10-Year Retrospective Study of 50 Cases

Oral IX

O. JAMAL, A. JEHRI, A. LAIDI, K. GUETTABI, M. MAKHCHOUNE, K. IBAHIOUINE, A. NAJA, A. LAKHDAR.

Department of Neurosurgery at the Ibn Rochd University Hospital Center in Casablanca

Laboratory for Diseases of the Nervous System, Sensory Nerves, and Disabilities

Introduction: High-grade intracranial meningiomas (World Health Organization [WHO] grades II and III) are uncommon but biologically aggressive tumors characterized by high recurrence rates and poor clinical outcomes compared with grade I meningiomas. Despite advances in microsurgical techniques and adjuvant therapies, their management remains challenging. This study aimed to analyze the epidemiological, clinical, radiological, surgical, and prognostic characteristics of high-grade intracranial meningiomas treated at a tertiary neurosurgical center.

Methods: A retrospective descriptive study was conducted on 50 consecutive patients with histologically confirmed WHO grade II or III intracranial meningiomas treated at the Department of Neurosurgery, Ibn Rochd University Hospital, Casablanca, Morocco, between January 2011 and December 2021. Demographic, clinical, radiological, operative, histopathological, and follow-up data were collected and analyzed.

Results: High-grade meningiomas accounted for 11.82% of all surgically treated intracranial meningiomas during the study period. The mean patient age was 49 years (range, 10–72 years), with a female predominance (70%). Convexity was the most common tumor location (54%), followed by parasagittal (16%), falcine (14%), and skull-base lesions (8%). Headache was the leading presenting symptom (70%), followed by seizures (42%), motor deficits (38%), intracranial hypertension (36%), cranial nerve dysfunction (26%), and cognitive impairment (20%). Radiologically, peritumoral edema was identified in 58% of cases, heterogeneous contrast enhancement in 56%, cystic changes in 28%, bone lysis in 24%, and calcifications in 14%. Gross total resection (Simpson grades I–III) was achieved in 60% of patients. Postoperative neurological deterioration occurred in 16%, surgical site infection in 12%, and cerebrospinal fluid leakage in 6%. Tumor recurrence was observed in 20% of patients, with an overall mortality rate of 26% during follow-up.

Conclusion: High-grade intracranial meningiomas remain a major therapeutic challenge because of their aggressive biological behavior and high risk of recurrence. Maximal safe surgical resection remains the cornerstone of treatment, while close postoperative surveillance and appropriate adjuvant therapy are essential to optimize long-term outcomes and reduce disease recurrence.

Keywords: High-grade meningioma; WHO grade II meningioma; Anaplastic meningioma; Intracranial tumors; Neurosurgery; Tumor recurrence; Surgical outcomes.

O79 - Spinal Epidural Hemangioma: A Series of 15 Cases

Oral IX

A. Jehri[1,2], O. Jamal[1,2], K. El Gheuttabi[1,2], K. Ibahioin[1,2], S. Hilmani[1,2], A. Lakhdar[1,2]

1 Department of Neurosurgery, Ibn Rochd University Hospital, Casablanca, Morocco

2 Laboratory for Diseases of the Nervous System, Sensory Nerves, and Disabilities

Introduction: Spinal epidural hemangiomas are rare vascular lesions that may cause spinal cord or nerve root compression. The thoracic spine is the most frequently affected region. Their diagnosis is challenging because their clinical and radiological features may mimic other spinal epidural lesions.

Materials and Methods: We conducted a retrospective descriptive case series of patients diagnosed with spinal epidural hemangioma and managed at the Department of Neurosurgery, Ibn Rochd University Hospital, Casablanca, Morocco, over a 30-year period (1994–2024). Demographic, clinical, radiological, surgical, and follow-up data were collected and analyzed.

Results: Fifteen patients were included, comprising 11 women and 4 men, with a male-to-female ratio of 0.36. The mean age was 51.5 years (range: 31–76 years). One patient had a history of previous surgery for a cavernous hemangioma. Thirteen lesions were located in the thoracic region, one in the cervicothoracic region, and one in the thoracolumbar region. Most patients presented with progressive spinal cord compression, whereas one presented with a radiculomyelopathic syndrome. MRI was performed in all patients. The lesions appeared isointense on T1-weighted images in 10 cases and hypointense in 5 cases. All lesions were hyperintense on T2-weighted images and demonstrated intense, homogeneous enhancement following gadolinium administration. Spinal CT was performed in five patients, and myelography was performed in one. All patients underwent surgery consisting of laminectomy and complete lesion excision. The postoperative courses were uneventful.

Discussion: Spinal epidural hemangiomas are rare benign vascular lesions that may present with progressive neurological deficits or, less frequently, acute spinal cord compression secondary to intralesional hemorrhage. MRI is the imaging modality of choice, typically demonstrating T1 isointensity or hypointensity, T2 hyperintensity, and marked contrast enhancement. These features may help guide the diagnosis, although histopathological examination remains essential for definitive characterization. Complete surgical excision is the preferred treatment when feasible, generally through a posterior approach. Early diagnosis and appropriate surgical management are important to achieve favorable neurological outcomes.

Conclusion: Spinal epidural hemangiomas are rare lesions that should be considered in the differential diagnosis of spinal epidural masses, particularly in patients presenting with progressive spinal cord compression. MRI plays a key role in preoperative assessment, while histopathological examination establishes the definitive diagnosis. Surgical excision generally yields favorable outcomes, although management should be tailored to the lesion's location and relationship with surrounding structures.

الجمهورية التونسية
République Tunisienne
وزارة الصحة
Ministère de la Santé

الجمعية التونسية لجراحة الجهاز العصبي
ASSOCIATION TUNISIENNE DE NEUROCHIRURGIE

Pan Arab Neurosurgical Society
الجمعية العربية للجراحة العصبية

15th PANARAB NEUROSURGICAL SOCIETY CONFERENCE

39th Congress of the Tunisian Association of Neurosurgery

November 6th – 8th 2026

Russelior Hotel - Yasmine Hammamet - TUNISIA



Video Presentations

V1 - Meckel's cave meningioma with concomitant neurovascular conflict causing severe trigeminal neuralgia: surgical approach

Omar Ktari, Lassaad Bsili

Olivier Clinic, Sousse, Tunisia.

Introduction: Meckel's cave meningiomas are rare tumors accounting for less than 1% of intracranial meningiomas. Their deep location and proximity to the trigeminal nerve and major vascular structures make surgical management particularly challenging. We present the case of a patient with a Meckel's cave meningioma associated with a neurovascular conflict causing severe trigeminal neuralgia.

Case presentation: A 56-year-old woman presented with severe right-sided trigeminal neuralgia refractory to medical treatment. MRI revealed a right Meckel's cave meningioma extending into the posterior fossa, with compression of the trigeminal nerve. A concomitant neurovascular conflict involving the superior cerebellar artery was identified. The patient underwent surgical resection through a retrosigmoid approach. The tumor was carefully dissected from the trigeminal nerve, and microvascular decompression was performed by separating the superior cerebellar artery from the nerve using a Teflon pad. Gross total resection was achieved while preserving the trigeminal nerve and adjacent neurovascular structures. Postoperatively, the patient experienced immediate and complete relief of trigeminal neuralgia without neurological deficit.

Conclusion: This case highlights the importance of recognizing concomitant neurovascular conflict in patients with Meckel's cave meningiomas presenting with trigeminal neuralgia. Surgical treatment should address both tumor resection and vascular decompression to achieve optimal symptom relief. The retrosigmoid approach provides adequate exposure for the safe management of both pathologies.

V2 - Pretemporal transcavernous approach for pituitary macroadenomas with cavernous sinus invasion: video presentation of two cases

Lassaad Bsili, Ahmed Maatoug

Olivier Clinic, Sousse, Tunisia.

Background: Pituitary macroadenomas invading the cavernous sinus remain a surgical challenge because of their intimate relationship with critical neurovascular structures. While endoscopic endonasal approaches are widely used, selected cases may benefit from transcranial routes that provide direct access to the lateral compartment of the cavernous sinus.

Objective: To demonstrate the surgical nuances and outcomes of the pretemporal transcavernous approach in the management of pituitary macroadenomas with significant cavernous sinus invasion through a video presentation of two illustrative cases.

Methods: Two patients harboring large pituitary macroadenomas with extensive cavernous sinus invasion underwent microsurgical resection via a pretemporal transcavernous approach. Preoperative imaging, surgical technique, anatomical landmarks, extent of resection, and postoperative outcomes were analyzed and highlighted in the video.

Results: The pretemporal transcavernous approach provided adequate exposure of the parasellar region and cavernous sinus, allowing safe tumor debulking and resection under direct visualization. Gross-total or near-total resection was achieved while preserving the internal carotid artery and cranial nerves traversing the cavernous sinus. Both patients experienced favorable postoperative outcomes with improvement of presenting symptoms and no permanent new neurological deficits.

Conclusion: The pretemporal transcavernous approach is a valuable option for selected pituitary macroadenomas with substantial cavernous sinus invasion. It offers wide surgical exposure, facilitates tumor removal from the cavernous sinus, and enables preservation of critical neurovascular structures. The presented video illustrates the key operative steps, technical pearls, and anatomical considerations of this approach.

V3 - Is complete resection of craniopharyngioma always possible? a challenging surgical case with video demonstration

Farah Bahri[1], F. Ben Atig[2], H. Hdhili[1], M. A. Kharrat[1], M. Bounemra[1], A. Hermassi[1], S. Ben Zekri[1], A. Bedioui[1], M. Rkhami[1], M. Badri[1], K. Bahri[1], I. Zammel[1]

[1] Center of Traumatology and Burns of Ben Arous;
[2] Regional Hospital Sadok Mokaddem of Djerba, Tunisia.

Background: Complete resection of craniopharyngiomas remains a major neurosurgical challenge because of the tumor's intimate relationship with the hypothalamus, pituitary stalk, optic apparatus, and perforating vessels. While gross total resection offers the best chance of long-term tumor control, aggressive surgery may result in devastating neurological and endocrine sequelae. We present a challenging pediatric case illustrating the intraoperative decision-making process and discuss whether complete excision should always be pursued.

Methods: A 10-year-old boy presented with progressive headaches, visual impairment, and growth delay. Brain MRI revealed a large mixed solid-cystic suprasellar craniopharyngioma extending into the third ventricle. The patient underwent microsurgical resection through a transcranial approach. Operative findings, anatomical challenges, surgical strategy, postoperative outcome, and radiological follow-up were analyzed. An edited operative video highlighting the key microsurgical steps and decision-making process will be presented.

Results: Intraoperatively, the tumor was densely adherent to the hypothalamus, pituitary stalk, optic chiasm, and critical perforating arteries. Although gross total resection was initially intended, preservation of these eloquent structures became the surgical priority when safe dissection planes disappeared. A deliberate near-total resection was therefore achieved, leaving only a thin layer of tumor firmly attached to the hypothalamus. Histopathology confirmed the diagnosis. Postoperatively, the patient experienced visual improvement without new neurological deficits. Endocrine replacement therapy was required for pituitary dysfunction.

Conclusion: This case underscores that complete resection is not always the optimal surgical objective in pediatric craniopharyngiomas. Functional preservation should prevail over anatomical radicality when critical neurovascular structures are at risk. Planned near-total resection, combined with close radiological surveillance and selective adjuvant therapy, may offer the best balance between tumor control and long-term quality of life. The accompanying surgical video emphasizes the anatomical landmarks, microsurgical techniques, and intraoperative judgment that guided the extent of resection, providing valuable technical insights for skull base neurosurgeons.

V4 - Facing the triple challenge: surgical management of triple cerebral aneurysms

Ferial Mokfi, Houari, Derbal, Belahoul, Guezzen, Benamara, Mimouni, Arab, Belebna, Guerbouz

Department of Neurosurgery, 1 Novembre Hospital, Oran, Algeria.

Background: Multiple intracranial aneurysms are encountered in approximately 15–30% of patients with cerebral aneurysms. The presence of three aneurysms poses significant diagnostic and therapeutic challenges, particularly in determining the rupture site and selecting the optimal treatment strategy.

Case presentation: We report the case of a patient presenting with subarachnoid hemorrhage secondary to rupture of one of three intracranial aneurysms. Preoperative vascular imaging revealed three distinct aneurysms involving different cerebral arterial territories. Following multidisciplinary discussion, microsurgical clipping was selected. Through a tailored surgical approach, all aneurysms were successfully identified and clipped.

Discussion: The management of multiple intracranial aneurysms remains challenging and requires careful preoperative planning.

Conclusion: Triple intracranial aneurysms are rare and complex lesions. A tailored microsurgical strategy can achieve complete aneurysm occlusion with excellent clinical outcomes when performed in appropriately selected patients.

V5 - Microsurgical clipping of ruptured large posteriorly directed anterior communicating artery aneurysms: video presentation of two illustrative cases

Ahmed Maatoug, Lassaad Bsili

Olivier Clinic, Sousse, Tunisia.

Background: Large aneurysms of the anterior communicating artery (AComA) complex, particularly those with posterior projection, pose significant surgical challenges because of their deep location and close relationship with the perforating arteries, hypothalamic structures, and the A1–A2 segments. Careful microsurgical dissection is essential to achieve complete aneurysm exclusion while preserving critical vascular anatomy.

Objective: To present the microsurgical management of two large posteriorly directed anterior communicating artery aneurysms and to highlight the operative strategies and technical nuances through a surgical video.

Methods: Two patients with rupted large posteriorly projecting AComA aneurysms underwent microsurgical clipping through a tailored pterional approach. Preoperative imaging, microsurgical anatomy, aneurysm exposure, proximal vascular control, perforator preservation, clip reconstruction, and postoperative outcomes are demonstrated in the video. Particular attention was paid to the identification and preservation of the recurrent artery of Heubner and hypothalamic perforators.

Results: Complete aneurysm occlusion was achieved in both cases with preservation of the parent vessels and perforating arteries. Careful dissection of the interhemispheric fissure and AComA complex allowed safe clip application despite the posterior orientation of the aneurysm dome. Postoperative angiographic studies confirmed durable aneurysm exclusion without residual filling. Both patients experienced favorable clinical outcomes without new permanent neurological deficits.

Conclusion: Microsurgical clipping remains an effective and durable treatment option for large posteriorly directed AComA aneurysms. Detailed knowledge of the microsurgical anatomy of the AComA complex and meticulous perforator preservation are critical for achieving optimal results. The presented video illustrates key surgical steps, anatomical considerations, and technical pearls for the management of these challenging aneurysms.

V6 - Microsurgical management of large paraclinoid aneurysms: video presentation of two illustrative cases

Lassaad Bsili, Ahmed Maatoug

Olivier Clinic, Sousse, Tunisia.

Background: Large paraclinoid aneurysms represent a complex vascular pathology because of their proximity to the optic apparatus, internal carotid artery, and skull base structures. Despite advances in endovascular therapy, microsurgical clipping remains an important treatment option in selected cases, particularly when decompression of neural structures is required.

Objective: To illustrate the microsurgical management of large paraclinoid aneurysms through a video presentation of two representative cases and to highlight the technical nuances of surgical exposure, proximal control, and aneurysm clipping.

Methods: Two patients with large paraclinoid aneurysms underwent microsurgical treatment. The first patient presented with a large unruptured ophthalmic segment aneurysm causing progressive visual impairment. The second patient harbored a ruptured inferior paraclinoid aneurysm presenting with subarachnoid hemorrhage. Surgical planning, extradural anterior clinoidectomy, optic nerve decompression, aneurysm dissection, clip application, and postoperative outcomes are demonstrated in the video.

Results: Adequate proximal and distal vascular control was achieved in both cases through a tailored skull base approach. In the first case, clipping of the ophthalmic aneurysm resulted in complete aneurysm exclusion and postoperative improvement of visual symptoms. In the second case, the ruptured inferior paraclinoid aneurysm was successfully secured with preservation of the parent vessel and adjacent perforators. Postoperative imaging confirmed complete occlusion of both aneurysms without significant complications.

Conclusion: Microsurgical clipping remains a safe and effective treatment modality for selected large paraclinoid aneurysms. It provides durable aneurysm exclusion and allows direct decompression of the optic apparatus when necessary. The presented video emphasizes key anatomical landmarks, operative strategies, and technical pearls that facilitate successful management of these challenging lesions.

V7 - Surgical management of a ruptured cervical AVM

Abdelaziz Bennadji, Ouarda Guerza, Lobna Hamadou, Zakia Guerfi

University of Batna, Batna University Hospital Center, Algeria.

Background: Spinal arteriovenous malformations are congenital in origin and manifest before the age of 40 through subarachnoid haemorrhages (one-third of cases) and acute neurological symptoms, which are partially reversible but progress in episodes towards a bedridden state within 10 to 20 years. They are suspected on MRI and confirmed by angiography, with a wide range of presentations ranging from simple arteriovenous shunts to large multi-pedunculated malformations with pseudotumour-like venous drainage. The differential diagnosis includes cavernomas when they bleed. Treatment involves embolisation and, in certain situations, surgery.

Clinical case: A 25-year-old woman with no previous medical history was transferred to our department of neurosurgery with sudden-onset incomplete tetraplegia. Clinical examination revealed a conscious patient scoring 15/15 with incomplete tetraplegia predominantly affecting the lower limbs. A brain and spinal cord MRI revealed cervical spinal cord compression caused by a probable cavernoma that had haemorrhaged at the C4–C5 level. As angiography facilities were not available throughout the region, the patient underwent laminectomy at C4 and C5, and upon opening the dura mater, we were surprised to find a cluster of blood vessels with multiple posterior afferents suggestive of an arteriovenous malformation. Faced with the choice of either stopping the procedure or continuing, we opted to proceed with the surgery. We proceeded to preserve the posterior spinal artery and vein and to coagulate the afferents, which allowed the intramedullary nidus to collapse, whilst facilitating the evacuation of the haematoma via a small posterior cordotomy.

Results: The post-operative evolution was good, with mobility preserved in both upper limbs. The patient was referred to a rehabilitation centre. The histopathology report confirmed an arteriovenous malformation, and the follow-up angiography showed the absence of any vascular malformation.

Conclusion: Whilst diagnostic confirmation of arteriovenous malformations remains straightforward in centres equipped with angiography facilities, their therapeutic management remains challenging, with outcomes depending on the pre-operative neurological status.

V8 - Superficial temporal artery to middle cerebral artery bypass in moyamoya disease: a video case

Khalil Ghedira[1], Roua Latrach[1], Firas Sliti[1], Wissal Nsiri[2], Insaf Dkhil[3], Amine Ben Lakhal[3], Adonis Halouani[3]

[1] Department of Neurosurgery;

[2] Department of Anesthesiology and Resuscitation;

[3] Department of Neuroradiology, Mongi Ben Hamida National Institute of Neurology, Tunis, Tunisia.

Introduction: Moyamoya disease (MMD) is a chronic, occlusive cerebrovascular disease characterized by progressive stenosis at the terminal portion of the internal carotid artery and the development of an abnormal vascular network at the base of the brain (“puff of smoke”). Revascularization surgery for symptomatic MMD is considered the standard treatment for preventing further stroke.

Methods: We present a surgical video describing the different technical steps of a direct bypass between the superficial temporal artery and the middle cerebral artery. Clinical and imaging data of the patient are presented. A short literature review of this technique is exposed.

Results: A 47-year-old female patient was diagnosed with Moyamoya disease after three successive ischemic and hemorrhagic strokes. The patient was treated by an extracranial-intracranial bypass on the predominant side of carotid stenosis. A terminolateral anastomosis was achieved between the parietal branch of the left superficial temporal artery (STA) and a temporal M4 branch of the left middle cerebral artery (MCA). The patient tolerated the surgical procedure well. Postoperative imaging showed a functional revascularization.

Conclusion: Moyamoya disease is a rare neurovascular disease responsible for multiple strokes in adults and children. The only effective treatment is surgical revascularization, whether direct or indirect. The STA-MCA direct bypass is the most commonly used technique in adult Moyamoya patients, with high rates of good results.

V9 - Surgical management of an intraventricular hydatid cyst: technical notes

Abdelaziz Bennadji, Abdelhak Benzid, Ouarda Zeroual, Zhor Mekentichi

University of Batna 2, Batna University Hospital Center, Algeria.

Background: Echinococcosis is a parasitic disease resulting from infection with Echinococcus granulosus. Diagnosis is delayed and MRI confirms the diagnosis. Intraventricular localisation is rare. The hydropulsion excision is the best technique to prevent recurrences

Clinical case: This is the case of a six-year-old child, with no significant medical history apart from a history of sheep farming, who was admitted to the neurosurgery department with a syndrome of intracranial hypertension. Symptoms began one month prior to admission, characterised by severe headaches accompanied by vomiting and gait disturbance. Clinical exam revealed: a conscious patient scoring 15/15, presenting with intracranial hypertension syndrome and papilloedema on funduscopic examination; and a dragging of the legs whilst walking. The brain CT scan showed a large, thin-walled, cystic mass in the right frontal lobe with active hydrocephalus, suggestive of a hydatid cyst. The patient underwent emergency left ventriculo-peritoneal shunt surgery; a subsequent brain MRI confirmed the diagnosis. The patient subsequently underwent a second operation via a transcortical transventricular approach to the right frontal lobe guided by ultrasound with the cyst drained by hydropulsion. The postoperative evolution was good.

Results: Echinococcal cysts in humans are the result of embryos that pass through the hepatic and pulmonary filters to reach the brain. -Several techniques have been described for the surgical management of hydatid cysts, but cyst excision whilst preserving the intact cyst wall remains the technique of choice to prevent recurrence. The specific features of the intraventricular form, which is exceptional, are: - the need to widen the cortotomy and retract the tissue to avoid cyst rupture without causing neurological damage. - adopting a surgical position that facilitates cyst drainage and prevents acute hydrocephalus caused by the saline solution injected during hydropulsion therapy.

Conclusion: Intraventricular hydatid disease is a rare location that requires caution and mastery of the hydropulsion technique, which is the only way to ensure the cyst does not rupture.

V10 - Endoscopic transnasal resection of an optic nerve cavernoma: 2-dimensional operative video

Nesrine Jemel, Md[1,2,3], Philippe Lavigne, Md[1,4]; Sebastien Fournier, PhD, Dabnm[5,6]; Khalil Alqadasi, Md[1,2]; Jacinthe Rouleau, Md[1,7]; Moujahed Labidi, Md[1,2,3]

[1] CHUM: Centre Hospitalier Universitaire de l'Université de Montréal, Montreal, Quebec, Canada;

[2] Division of Neurosurgery, Department of Surgery, University of Montreal, Montreal, Quebec, Canada;

[3] Centre de recherche du Centre hospitalier de l'Université de Montréal (CRCHUM), Montreal, Quebec, Canada;

[4] Division of Otorhinolaryngology, Department of Surgery, University of Montreal, Montreal, Quebec, Canada;

[5] Rampart Neurophysiology Inc., Levis, Quebec, Canada;

[6] Department of Surgery, Laval University, Quebec City, Quebec, Canada;

[7] Department of Ophthalmology, University of Montreal, Montreal, Quebec, Canada.

Background: Optic pathway cavernomas are rare, benign vascular lesions that typically manifest with visual disturbances. Their most severe complication is chiasmal apoplexy, characterized by sudden visual loss. Surgical resection is recommended in most cases to preserve vision and prevent future hemorrhagic episodes. The endoscopic endonasal approach is particularly indicated for lesions located medially and inferiorly to the optic chiasm and optic nerves.

Methods: A 58-year-old woman with no prior medical history presented with progressive visual loss — more pronounced in the right eye and fluctuating in the left. MRI revealed a small cavernoma in the medial-inferior portion of the right optic nerve, and visual field testing confirmed optic pathway involvement. After ten months of clinical observation during which the left eye showed progressive decline, surgical intervention was undertaken via an endoscopic endonasal approach. This corridor provided direct access to the exophytic portion of the lesion with minimal brain retraction. Intraoperative neuronavigation and visual evoked potentials (VEPs) were used to guide and optimize the resection.

Results: The lesion was completely resected without postoperative complications. The involvement of the left eye was attributed to the Wilbrand's knee, consistent with a junctional chiasmal syndrome. Postoperatively, vision in the left eye improved.

Conclusion: This case illustrates that the endoscopic endonasal approach is a viable and effective strategy for optic pathway cavernomas situated medially and inferiorly to the optic nerve and chiasm. Intraoperative neuronavigation and VEP monitoring are valuable adjuncts for safe, complete resection. Awareness of junctional chiasmal syndrome and its anatomical basis is essential for accurate preoperative localization and surgical planning.

V11 - Endoscopic endonasal management of papillary and adamantinomatous craniopharyngiomas: a comparative operative video with a proposed role for intraoperative raman spectroscopy

Nesrine Jemel[1], Ana Bokasova, Msc[2]; Najib Nassiri, Bsc[2]; Philippe Lavigne, MD, Frcsc[3]; Frederic Leblond, Phd[2]; Moujahed Labidi, MD, Frcsc[1]

[1] Division of Neurosurgery, Centre Hospitalier de l'Université de Montréal, Montreal, Quebec, Canada;

[2] Polytechnique Montréal, Department of Engineering Physics, Montreal, Quebec, Canada;

[3] Division of Otolaryngology-Head and Neck Surgery, Centre Hospitalier de l'Université de Montréal, Montreal, Quebec, Canada.

Background: Craniopharyngiomas comprise two molecularly distinct subtypes: papillary (PCP), driven by BRAF V600E mutations and typically presenting as solid, well-circumscribed third ventricular masses in adults; and adamantinomatous (ACP), driven by CTNNB1 mutations and characterized by cystic-solid architecture with calcifications and hypothalamic adherence. Accurate subtype distinction carries significant clinical implications.

Methods: Two representative cases illustrate the radiological and intraoperative differences between subtypes via the extended endoscopic endonasal approach. Subtype identification — through MRI, intraoperative frozen section, and cerebrospinal fluid (CSF) liquid biopsy — is critical, as it directly informs surgical strategy and postoperative management, including BRAF/MEK inhibitor therapy for PCP. We propose translating a previously validated endonasal Raman spectroscopy probe — previously used in pituitary adenoma surgery — for real-time intraoperative discrimination between ACP and PCP.

Results: The probe employs near-infrared (NIR) laser excitation to generate molecular vibrational fingerprints reflecting tissue biochemistry. It is fiber-optic, fully compatible with the endonasal corridor, and delivers real-time readout in under 3 seconds per acquisition. Comparative Raman spectral profiling of representative ACP and PCP tumor samples revealed a prominent ~960 cm^{-1} peak in ACP — absent in PCP — consistent with its calcified regions, while cholesterol signatures from "machine-oil" cyst fluid further distinguish ACP from PCP.

Conclusion: PCP and ACP represent molecularly and clinically distinct entities. Preoperative imaging remains valuable for subtype identification, and CSF liquid biopsy has shown promise as a non-invasive alternative. Raman spectroscopy holds potential as a real-time intraoperative tool for discriminating PCP from ACP.

V12 - When endoscopy meets synovial cysts: a minimally invasive route to complete neural decompression

Hajer Kammoun, K. Bouzouita, S. Farhat, A. Affes, S. Achoura, A. Harbaoui, R. Chkili, M. D. Yedeas, K. Radhouane

Department of Neurosurgery, Principal Military Hospital of Instruction of Tunis, Tunisia.

Lumbar facet joint synovial cysts are uncommon but clinically significant degenerative lesions that may cause radiculopathy, neurogenic claudication, or neurological deficits through compression of adjacent neural structures. Conventional surgical treatment has traditionally relied on open or microscopic decompression with cyst excision. However, these lesions are often adherent to the dura mater and nerve roots, making surgical dissection technically challenging and potentially associated with complications such as dural tears, postoperative pain, muscle injury, and prolonged recovery. In recent years, full-endoscopic spine surgery has emerged as a minimally invasive alternative, offering reduced soft-tissue trauma, shorter hospitalization, faster functional recovery, and lower perioperative morbidity. The uniportal endoscopic approach provides excellent magnified visualization of the surgical field, facilitating meticulous dissection of adherent lesions while preserving surrounding anatomical structures, including the facet joint and paraspinal musculature. We present the surgical management of a 57-year-old man who experienced left L5 radicular pain for three months, refractory to medical treatment. Computed tomography and magnetic resonance imaging demonstrated L4–L5 degenerative spondylolisthesis associated with bilateral facet arthrosis and a left-sided posterior epidural cystic lesion, partially calcified, consistent with a lumbar synovial cyst. A full-endoscopic cystectomy was performed through a left L4–L5 interlaminar approach. The endoscopic technique enabled direct visualization of the cyst, careful dissection from surrounding neural elements, complete excision of the lesion, and adequate neural decompression while minimizing tissue disruption. The patient experienced immediate postoperative relief of radicular symptoms and was discharged on the first postoperative day. This case highlights the feasibility, safety, and effectiveness of uniportal full-endoscopic surgery for the treatment of lumbar synovial cysts and underscores its value as a minimally invasive alternative to conventional surgical approaches.

V13 - Primary central nervous system b-cell lymphoma presenting as an intraventricular lesion with obstructive hydrocephalus: a case report

Khalil Ayadi, F. Kolsi, B. Kammoun, M. Z. Boudawara

Department of Neurosurgery, Habib Bourguiba University Hospital, Tunisia.

Background: Primary central nervous system lymphoma (PCNSL) is an uncommon malignant brain tumor with highly variable clinical and radiological presentations, making diagnosis challenging. Inflammatory disorders such as Neuro-Behçet disease may closely mimic PCNSL, potentially delaying appropriate treatment. We report a case of PCNSL initially suspected to represent Neuro-Behçet disease because of its clinical presentation.

Methods: A 60-year-old woman was admitted to the neurology department with altered consciousness. Neuroimaging demonstrated obstructive hydrocephalus secondary to an intraventricular/periventricular lesion. Based on the clinical and radiological findings, Neuro-Behçet disease was initially considered. The patient underwent emergency external ventricular drainage to treat hydrocephalus, followed by an endoscopic biopsy of the lesion for definitive diagnosis.

Results: External ventricular drainage resulted in neurological improvement and effective control of intracranial pressure. Histopathological examination of the endoscopic biopsy revealed diffuse large B-cell lymphoma, establishing the diagnosis of primary central nervous system lymphoma. The patient was subsequently referred to the hematology-oncology team for disease-specific treatment. Conclusions: PCNSL should be considered in the differential diagnosis of patients presenting with altered consciousness and obstructive hydrocephalus, particularly when clinical and imaging findings suggest an inflammatory or autoimmune disorder such as Neuro-Behçet disease. Neuroendoscopic biopsy provides a minimally invasive approach for obtaining diagnostic tissue while simultaneously addressing hydrocephalus. Early histopathological confirmation is essential to initiate appropriate therapy and avoid delays associated with empirical treatment for inflammatory diseases.

V14 - Navigating the third ventricle: lessons from 20 endoscopic third ventriculostomies

Yasmina Djouadi, I. Belgacem, M. Abou Djabel, M. Chahed, M. Ait Bachir

Department of Neurosurgery, CHU Nedir Mohamed, Tizi Ouzou, Algeria.

Contexte: La ventriculostomie endoscopique du troisième ventricule (VCE) est devenue un traitement établi pour certains cas d'hydrocéphalie obstructive. Une connaissance approfondie de l'anatomie ventriculaire et de ses variations est essentielle pour réaliser cette intervention de manière sûre et efficace.

Objectif: Décrire les constatations peropératoires et les variations anatomiques rencontrées lors de 20 procédures VCE réalisées pour différentes étiologies d'hydrocéphalie.

Méthodes: Nous avons analysé rétrospectivement les dossiers de 20 patients ayant subi une ventriculocisternostomie endoscopique (VCE) pour diverses formes d'hydrocéphalie, notamment la sténose de l'aqueduc de Sylvius, l'hydrocéphalie obstructive d'origine tumorale et d'autres causes de troubles de la circulation du liquide céphalo-rachidien. Les observations peropératoires et les variations anatomiques du plancher ventriculaire et des structures environnantes ont été analysées.

Résultats: Plusieurs variations anatomiques ont été identifiées, notamment des différences d'épaisseur et de transparence du plancher du troisième ventricule, des variations de taille du récessus infundibulaire, de proéminence des corps mamillaires et des variations vasculaires concernant l'artère basilaire et ses branches. Dans certains cas, des adhérences et une distorsion des repères anatomiques normaux ont été observées. La reconnaissance de ces variations s'est avérée cruciale pour le choix du site de perforation optimal et la prévention des complications peropératoires.

Conclusion: La ventriculocisternostomie endoscopique (VCE) expose les neurochirurgiens à une grande diversité de configurations anatomiques. Une évaluation endoscopique minutieuse du plancher du troisième ventricule et des structures neurovasculaires adjacentes est essentielle pour garantir la sécurité de la procédure et obtenir des résultats positifs. La connaissance de ces variations anatomiques contribue de manière significative à la planification chirurgicale et à la prise de décision peropératoire.

V15 - Endoscopic identification of septal abnormality in triventricular hydrocephalus: a case report

Farah Bahri[1], F. Ben Atig[2], H. Hdhili[1], S. Ben Yakoub[1], M. Bounemra[1], A. Hermassi[1], S. Ben Zekri[1], A. Bedioui[1], M. Rkhami[1], M. Badri[1], K. Bahri[1], I. Zammel[1]

[1] Center of Traumatology and Burns of Ben Arous;
[2] Regional Hospital Sadok Mokaddem of Djerba, Tunisia.

Background: Triventricular hydrocephalus is classically associated with obstruction at the level of the cerebral aqueduct or the third ventricle. When neuroimaging demonstrates a patent aqueduct, the underlying mechanism may remain elusive. Rare congenital intraventricular anatomical variants may produce functional cerebrospinal fluid (CSF) flow impairment despite the absence of an identifiable radiological obstruction. We report an unusual endoscopic finding suggesting a previously underrecognized cause of obstructive hydrocephalus.

Methods: A 32-year-old man with no previous medical history presented with spontaneous headaches associated with recurrent abrupt transient loss of consciousness (drop attacks). Neurological examination was normal. Brain CT demonstrated triventricular hydrocephalus. MRI confirmed enlargement of both lateral ventricles and the third ventricle while demonstrating a patent cerebral aqueduct and no posterior fossa lesion. An endoscopic third ventriculostomy was performed.

Results: Endoscopic exploration revealed unexpected intraventricular anatomical abnormalities consisting of a fenestrated septum pellucidum associated with multiple membranous ridges projecting between the lateral ventricles and extending toward the third ventricle, creating a complex septal architecture. No aqueductal stenosis or intraventricular tumor was identified. Endoscopic third ventriculostomy was successfully completed with restoration of CSF diversion. The postoperative course was uneventful, with complete resolution of headaches and no further episodes of transient loss of consciousness.

Conclusion: This case highlights an unusual congenital intraventricular septal malformation as a possible mechanism of functional CSF flow disturbance leading to triventricular hydrocephalus despite a patent aqueduct. Endoscopic surgery not only provided definitive treatment but also allowed direct visualization of anatomical abnormalities that were not apparent on MRI. Recognition of these rare ventricular septal variants may improve understanding of unexplained hydrocephalus and supports the additional diagnostic value of neuroendoscopy beyond its therapeutic role.

الجمهورية التونسية
République Tunisienne
وزارة الصحة
Ministère de la Santé

الجمعية التونسية لجراحة الجهاز العصبي
ASSOCIATION TUNISIENNE DE NEUROCHIRURGIE

Pan Arab Neurosurgical Society
الجمعية العربية لجراحة الأعصاب

15th PANARAB NEUROSURGICAL SOCIETY CONFERENCE

39th Congress of the Tunisian Association of Neurosurgery

November 6th – 8th 2026

Russelior Hotel - Yasmine Hammamet - TUNISIA



E-Posters

E-Poster sessions

6-7 November 2026 | Hammamet, Tunisia

SESSION	E-POSTERS	MODERATORS
Friday 6 November Morning - Post 1	P1-P25	Ines Cherif Aziz Bdioui
Friday 6 November Morning - Post 2	P26-P50	Amine Trifa Rihab Ben Fredj
Friday 6 November Morning - Post 3	P51-P75	Mechergui Haifa Firas Akrout
Friday 6 November Afternoon - Post 1	P76-P100	Khalil Ayadi Nesrine Nessib
Friday 6 November Afternoon - Post 2	P101-P125	Mahmoud Ben Messaoud Aziz Hermassi
Friday 6 November Afternoon - Post 3	P126-P151	Amine Rachdi Anis Hachicha
Saturday 7 November Morning - Post 1	P152-P177	Mohamed Znazen Kaouther Somrani
Saturday 7 November Morning - Post 2	P178-P203	Mohamed Amine Hadj Taieb Chiheb Abdelileh
Saturday 7 November Morning - Post 3	P204-P229	Mohamed Boukhit Fatma Ben Atig
Saturday 7 November Afternoon - Post 1	P230-P255	Ghassen El kahla Omar Hattab
Saturday 7 November Afternoon - Post 2	P256-P281	Marwen Taalah Sinda Ben Zekri
Saturday 7 November Afternoon - Post 3	P282-P302	Firas Stiti Ala Belhaj

P1 - A hostile abdomen: decision algorithm for ventriculoperitoneal shunt management during acute abdominal emergencies

Ameur Affes, Khayat M, Akrout F, Bouzouita K, Rachdi M.A., Kammoun T, Yedeas MD, Chkili Ridha, Radhouen K.

Neurosurgery Department, Military Hospital of Tunis, Tunis, Tunisia

Background & objectives: Ventriculoperitoneal shunting remains the most widely performed cerebrospinal fluid diversion procedure worldwide, yet the peritoneal cavity is not an unconditionally reliable drainage site. Acute abdominal emergencies — peritonitis, bowel perforation, abdominal sepsis, and major digestive surgery — render the peritoneum temporarily or permanently hostile to shunt function, creating a dual neurosurgical and digestive emergency requiring rapid, coordinated decision-making. No universally standardized algorithm currently guides VP shunt management in this context. This review proposes an evidence-based decision framework for VP shunt management during acute abdominal emergencies.

Methods: Narrative review of PubMed, Scopus, and Cochrane databases (2000–2024), including case series, retrospective cohort studies, and expert consensus addressing VP shunt complications during abdominal pathology, shunt externalization strategies, and alternative drainage options.

Results & discussion: Shunt dysfunction mechanisms: Peritoneal inflammation, fibrinous adhesions, and intra-abdominal sepsis impair distal catheter CSF absorption, precipitating acute shunt malfunction and intracranial hypertension simultaneously with the abdominal emergency — a convergence demanding immediate dual-specialty response. Immediate neurosurgical response: Shunt externalization — converting the distal peritoneal catheter to a temporary external ventricular or lumbar drain — represents the first-line intervention, decoupling CSF diversion from the hostile peritoneal environment while abdominal pathology is addressed, without requiring complete shunt system replacement. Timing of shunt revision: Peritoneal reimplantation should be deferred until complete resolution of abdominal sepsis, confirmed by normalization of inflammatory markers and absence of peritoneal contamination, typically requiring a minimum interval of 4–8 weeks following peritonitis resolution. Alternative distal sites: Ventriculoatrial shunting constitutes the preferred definitive alternative when peritoneal access is permanently compromised by multiple abdominal surgeries, dense adhesions, or recurrent peritoneal infection, with ventriculopleural shunting reserved as a tertiary option given its pulmonary complication profile. Multidisciplinary coordination: Simultaneous neurosurgical and digestive surgical management, ideally in a single operative session when feasible, minimizes anesthetic risk and optimizes both pathology management timelines.

Conclusion: A hostile abdomen demands a structured, stepwise neurosurgical response: immediate externalization, interdisciplinary coordination, deferred peritoneal reimplantation after confirmed resolution, and permanent alternative site consideration when the peritoneum is irreversibly compromised.

P2 - A rare case of intra-parenchymal papillary meningioma : a case report and review of literature

Salim Bechraoui[1], H Mechergui[2], E Mzoughi[1], K Ghedira[1], S Bouali[1], I Ben Said[1]

[1] Department of neurosurgery , National Institute of Neurology, Tunisia.

[2] Bougatfa Hospital department of surgery, Tunisia.

Intraparenchymal meningiomas are an uncommon variant of meningioma that arise within the cerebral cortex or subcortical white matter without a clear dural attachment, often mimicking intra-axial neoplasms on clinical and radiologic assessment. They present diagnostic challenges because imaging and clinical features frequently overlap with gliomas, metastases, and other intra-axial tumors. We report the case of a 35-year-old woman who presented with a first-ever generalized tonic-clonic seizure and progressive psychomotor slowing over a two-month period. The neurological examination revealed a conscious patient with episodic memory impairment. Brain MRI objective an hemorrhagic left temporal lesion with imaging features suggestive of glioblastoma, including marked hypervascularization and hyperperfusion on perfusion sequences. The patient underwent gross total resection with an uneventful postoperative course. Unexpectedly, histopathological examination established the diagnosis of papillary meningioma, WHO grade III, rather than glioblastoma. Radiologically, intraparenchymal meningiomas often appear as well-circumscribed enhancing intra-axial masses with surrounding vasogenic edema; cystic change and heterogeneous enhancement may be present, and a dural tail is frequently absent. Frontal and temporal lobes are common locations. Histopathology most frequently demonstrates meningothelial or transitional meningioma patterns, though higher WHO grades and atypical features occur more often in reported intraparenchymal cases than in typical extra-axial meningiomas. Gross total resection is usually achievable and is associated with favorable outcomes; seizures often improve after tumor removal. Recurrence risk correlates with extent of resection and histologic grade.

P3 - A solitary fibrous tumor mimicking a meningioma

Hajer Kammoun, K. Bouzouita, A. Affes, R. Chkili, M.D. Yedeas, K. Radhouane

Neurosurgery department, Principal Military Hospital of Instruction of Tunis

Introduction: Solitary fibrous tumors (SFTs) are rare mesenchymal spindle-cell neoplasms that most commonly arise from the pleura but may occur in any anatomical location. Intracranial SFTs are uncommon and typically originate from the dura, often mimicking meningiomas on neuroimaging. However, despite similar radiological appearances with slight differences, SFTs exhibit distinct biological behavior, characterized by a higher risk of local recurrence and potential for aggressive progression. Accurate diagnosis is therefore essential for prognosis assessment and long-term management.

Objectives: To highlight the diagnostic challenges posed by intracranial SFTs and emphasize the importance of considering this entity in the differential diagnosis of extra-axial lesions presumed to be meningiomas.

Case report: A 49-year-old man presented with vertigo, progressive bilateral visual impairment predominantly affecting the left eye, and left-sided paresthesia and weakness. Brain MRI revealed a right paramedian extra-axial lesion attached to the falx cerebri, showing marked contrast enhancement and imaging characteristics highly suggestive of a falcine meningioma.The patient underwent gross-total resection through a posterior interhemispheric approach with coagulation of the dural attachment. Postoperatively, the left-sided motor deficit transiently worsened. Histopathological examination unexpectedly demonstrated a solitary fibrous tumor.

Conclusion: Intracranial SFTs represent an important differential diagnosis of dural-based lesions. Although frequently indistinguishable from meningiomas on conventional imaging, subtle radiological features may rise suspicion for this entity. Their recognition is crucial because of their distinct biological behavior, greater propensity for recurrence, and need for prolonged surveillance and tailored therapeutic strategies. Awareness of this rare diagnosis may facilitate appropriate management and follow-up.

P4 - Abdominal cerebrospinal fluid pseudocyst following ventriculoperitoneal shunt: a rare case report

Hamid Khay, Amine Kada, Loubna Aniya, Khaoula Lamrabet, Mohamed Dahamou, Mohammed Al Amine El Farissi, Mohammed Khoulali

University hospital Center Mohammed VI Oujda, Morocco

Background: Abdominal cerebrospinal fluid (CSF) pseudocyst is an uncommon but potentially serious complication of ventriculoperitoneal (VP) shunting, with a reported incidence ranging from less than 1% to 4.5%. It consists of a fibrous, non-epithelial encapsulated collection of CSF surrounding the distal catheter, leading to shunt malfunction and abdominal symptoms. Early recognition is essential to prevent neurological deterioration and infectious complications.

Case presentation: We report the case of an 11-year-old child with Dandy–Walker variant malformation who had undergone VP shunt placement for congenital hydrocephalus. The patient presented with progressive abdominal pain without fever. Physical examination revealed abdominal tenderness, while abdominal computed tomography demonstrated a large intraperitoneal fluid collection surrounding the distal shunt catheter, consistent with an abdominal CSF pseudocyst. The patient initially underwent complete pseudocyst excision and distal catheter repositioning. Cerebrospinal fluid culture subsequently grew Escherichia coli, prompting targeted antibiotic therapy. Four days later, the patient developed impaired consciousness secondary to recurrent hydrocephalus. Brain computed tomography confirmed ventricular enlargement, requiring urgent removal of the VP shunt and placement of an external ventricular drain. Following CSF sterilization with serial negative cultures, definitive conversion to a ventriculoatrial shunt was successfully performed. At six-month follow-up, the patient remained asymptomatic, with no evidence of recurrent abdominal symptoms or intracranial hypertension.

Discussion: Abdominal pseudocyst should be considered in any VP shunt patient presenting with abdominal pain or signs of shunt dysfunction. Abdominal ultrasonography and computed tomography are the imaging modalities of choice. Management should be individualized according to the presence of infection and neurological status, combining surgical treatment, microbiological assessment, antibiotic therapy when indicated, and appropriate shunt revision.

Conclusion: Abdominal CSF pseudocyst is a rare but significant distal complication of VP shunting. Prompt diagnosis, multidisciplinary management, eradication of infection, and appropriate CSF diversion are crucial to achieve favorable neurological and surgical outcomes.

P5 - Acalvaria: first surviving case from egypt – case report and comprehensive review of the literature

Ahmed Ragab Abdelsalam[1], Ezzat Abdelkhalek[2], Essam Eldein M[2]. Abdelkawy[2], Mourad A R Tadros[3], Amr Elkatatny[4], Yasser Omar Riyad[5]

[1] Military Medical Academy, Cairo, Egypt.
[2] Neurosurgery Department, Air Forces Specialized Hospital, Cairo, Egypt.
[3] Pediatric Department, Air Forces Specialized Hospital, Cairo, Egypt.
[4] Neurosurgery Department, Cairo University, Cairo, Egypt.
[5] Neurosurgery Department, El-Galaa Military Medical Complex, Cairo, Egypt.

Background: Acalvaria is an extremely rare congenital malformation characterized by the absence of calvarial bones, with preserved skull base, facial bones, and usually normal brain tissue. Most reported cases are fatal in the neonatal period.

Case presentation: We present the first known case of acalvaria from Egypt: a full-term male infant, now 3 months old, with normal growth and development, and no associated anomalies except for defective posterior arches of cervical vertebrae with no neurological deficits. Imaging confirmed the diagnosis. This case is unique due to the patient's survival and absence of neurological deficits.

Conclusion: This report adds to the limited literature on acalvaria, highlighting the possibility of survival and normal development, and provides a comprehensive literature review.

P6 - Acute cervical myelopathy after minor trauma in a patient with diffuse idiopathic skeletal hyperostosis: a therapeutic challenge

Mohamed Znazen, M. Taallah, I. Ketata, A. Hachicha

Department of Neurosurgery, University Hospital of Gabès, Tunisia

Background: Diffuse idiopathic skeletal hyperostosis (DISH), also known as Forestier disease, is characterized by extensive ossification of spinal ligaments resulting in a rigid and vulnerable spine. Even minor cervical trauma may lead to neurological deterioration. Although surgical treatment is often considered in patients with neurological deficits, conservative management may be an alternative in selected cases without spinal instability or significant cord compression.

Methods: We report the case of a 64-year-old man with no previous neurological history who developed acute tetraparesis following a low-energy fall resulting in minor cervical trauma. Clinical, radiological, therapeutic, and follow-up data were retrospectively analyzed.

Results: Neurological examination revealed motor weakness involving all four limbs, predominantly affecting the lower extremities, associated with pyramidal signs and a sensory level at T4. Cervical computed tomography and magnetic resonance imaging demonstrated flowing anterior ossifications consistent with DISH, associated with cervical canal stenosis and cervical spondylotic myelopathy extending from C2–C3 to C4–C5. No fracture, dislocation, or spinal instability was identified. Given the absence of an immediate surgical indication, conservative treatment was initiated, including cervical immobilization, high-dose corticosteroid therapy, and early intensive rehabilitation. The patient showed progressive neurological improvement during follow-up. After three months of rehabilitation, he regained assisted ambulation and achieved significant functional recovery with improved independence in activities of daily living.

Conclusions: Post-traumatic cervical myelopathy may occur in patients with DISH even after minor trauma and in the absence of radiological evidence of fracture. In carefully selected patients without spinal instability or urgent indications for decompression, conservative management combined with intensive rehabilitation may lead to satisfactory neurological and functional outcomes.

P7 - Acute cervicothoracic spondylodiscitis and epidural abscess causing paraplegia after cervical transforaminal epidural steroid injection: a rare neurosurgical emergency.

Balkis Hajji, Hichem Ben Salma, Ben Ticha Mehdi, Hattab Omar, Iadh Ksira

Department of neurosurgery, Sahloul University Hospital, Sousse, Tunisia.

Background: Transforaminal epidural steroid injections (TFESIs) are commonly performed for the management of cervical and lumbar radicular pain. Although generally considered safe, serious complications have been reported, including spinal cord infarction, epidural hematoma, epidural abscess, neurological deterioration, and paralysis. We report a rare case of extensive cervical-thoracic spondylodiscitis with epidural abscess causing acute spinal cord compression following cervical TFESI.

Case presentation: A 56-year-old man with no significant medical history presented with bilateral cervicobrachial neuralgia and underwent cervical transforaminal epidural steroid injection. One week after the procedure, he developed progressive lower-limb weakness associated with urinary incontinence and fever. Neurological examination revealed a thoracic spinal cord compression syndrome characterized by paraplegia, pyramidal signs, posterior column dysfunction, cervical and thoracic spinal pain, and a sensory level at T4. Magnetic resonance imaging (MRI) demonstrated a posterior epidural abscess extending from C7 to T2, resulting in severe spinal cord compression. Associated findings included C5 vertebral osteomyelitis, anterior epiduritis from C5 to C7, and posterior epiduritis at T1–T2. The patient underwent urgent decompressive laminectomy of T1–T2 extended to C7 with spinal canal decompression and microbiological sampling. Culture of the operative specimens grew Staphylococcus aureus. Intravenous cefazolin was administered for 21 days. Postoperatively, the patient's motor strength improved from 1/5 to 3/5 in both lower limbs. He was subsequently transferred to a rehabilitation unit for further management.

Discussion and conclusion: Infectious complications following cervical TFESI are exceptionally rare but may result in devastating neurological consequences. Early recognition of fever, neurological deterioration, and spinal pain following spinal injections is essential. Prompt MRI evaluation, targeted antibiotic therapy, and urgent surgical decompression when indicated are critical for optimizing neurological recovery. This case highlights the importance of strict aseptic technique during TFESI and maintaining a high index of suspicion for spinal infection in patients presenting with new neurological deficits after the procedure.

P8 - Acute remote epidural hematoma following transcranial resection of a recurrent craniopharyngioma: a rare intraoperative complication

Aziz Abdelmoula, A. Bouhoula, M. Naceur, N. Nessib, F. Sliti, A. Ouesleti, E.Mzoughi

Department of neurosurgery , National Institute of Neurology, Tunisia.

Remote epidural hematoma (EDH) is an exceptionally rare but potentially life-threatening complication of intracranial tumor surgery. It is most frequently reported after cerebrospinal fluid (CSF) overdrainage, particularly in young patients undergoing skull base procedures. Prompt recognition and immediate surgical evacuation are essential to prevent permanent neurological deficits.

Case presentation: We report the case of a 30-year-old man with recurrent intra- and suprasellar craniopharyngioma. He had previously undergone subtotal resection through a right frontopterional approach in childhood, with residual panhypopituitarism. Sixteen years later, he presented with rapidly progressive visual deterioration due to tumor recurrence. Magnetic resonance imaging demonstrated a recurrent sellar and suprasellar cystic-solid lesion compressing the optic chiasm. The patient underwent repeat right frontopterional craniotomy. Following microsurgical opening of the Sylvian fissure and cerebrospinal fluid release from the basal cisterns, the cystic component was aspirated, allowing decompression of the lesion. Progressive microsurgical tumor debulking achieved decompression of both optic nerves, the optic chiasm, and the floor of the third ventricle. Tumor resection was technically challenging because of marked secondary frontal lobe swelling despite adequate basal cistern opening and maximal medical measures. At the completion of surgery, hemostasis was satisfactory and the bone flap was replaced. In the immediate postoperative period, the patient developed acute right-sided mydriasis. Emergency computed tomography revealed a large remote right frontoparietal epidural hematoma located posterior to the operative field. The patient underwent immediate reoperation with evacuation of the hematoma, dural suspension, and extradural drainage. The pupillary abnormality resolved immediately after surgery, and the patient recovered without permanent neurological deficit.

Discussion: Acute remote epidural hematoma after craniopharyngioma surgery is exceedingly uncommon. Excessive CSF drainage, intracranial hypotension, repeated craniotomy, and insufficient dural adhesion have been proposed as contributing mechanisms. Intraoperative unexplained brain swelling may represent an early warning sign of this complication. Immediate postoperative neurological assessment and urgent imaging are crucial for early diagnosis and successful management.

Conclusion: Remote epidural hematoma should be considered in patients presenting with unexpected brain swelling during surgery or acute neurological deterioration after craniopharyngioma resection. Early recognition and prompt surgical evacuation can result in excellent neurological outcomes despite this rare and potentially fatal complication.

P9 - Aggressive calvarial metastasis from mandibular ameloblastic carcinoma: a case report

Si Tayeb Fatima Zohra, Y. Djouadi, A. Benhaddadi, F. Manseur, S. Ahres, S. Benchabane, M. Ait Bachir.

Department of Neurosurgery, Tizi Ouzou University Hospital, Tizi Ouzou, Algeria.

Introduction: Ameloblastic carcinoma is a rare malignant odontogenic tumor that may arise de novo or through malignant transformation of a conventional ameloblastoma. While conventional ameloblastoma is characterized by favorable long-term survival despite its locally aggressive behavior, metastatic dissemination is associated with a markedly poorer prognosis. Intracranial involvement remains exceptionally rare.

Case presentation: A 61-year-old man with a history of hypertension, hypothyroidism, benign prostatic hyperplasia, and recurrent mandibular ameloblastoma treated with nine surgical resections and radiation therapy over the previous 20 years presented with a left frontal calvarial lesion. He underwent a left frontal craniectomy with complete excision of the involved bone followed by acrylic cranioplasty. Intraoperatively, a soft gray-white tumor infiltrating the temporalis muscle was identified. Histopathological examination revealed metastatic ameloblastic carcinoma. The postoperative course was uneventful, and the patient subsequently received adjuvant radiotherapy. One-year follow-up MRI demonstrated local recurrence requiring repeat surgical resection. Despite multimodal treatment, subsequent imaging showed rapid tumor progression with infiltrative intraparenchymal lesions.

Discussion: Calvarial metastasis from ameloblastic carcinoma is exceptionally uncommon and poses significant diagnostic and therapeutic challenges. Direct contiguous spread through the temporalis muscle has been proposed as a potential mechanism of intracranial dissemination. In our patient, intraoperative evidence of temporalis muscle infiltration supports this hypothesis. Despite combined surgical resection and adjuvant radiotherapy, rapid local recurrence followed by intraparenchymal progression underscored the highly aggressive nature of the disease. This unfavorable evolution raises the question of whether a more aggressive initial surgical approach might have improved local control.

Conclusion: Calvarial metastasis from ameloblastic carcinoma is an exceptionally rare manifestation. In our case, intraoperative evidence of temporalis muscle invasion supports the hypothesis of direct contiguous spread to the calvarium and intracranial compartment. Given the rarity of this entity, further studies and reported cases are needed to define the optimal surgical strategy and adjuvant treatment.

P10 - An uncommon cause of orbital mass: a case of primary mucinous adenocarcinoma

Rihab Ben Fredj, Barkache Majdouline, Grioui Angham, Gallaoui Slim, Hamida Mohamed Amine, Ksira Iyadh

Department of Neurosurgery, Sahloul Hospital, Sousse, Tunisia

Background: Primary mucinous adenocarcinoma of the orbit is an exceptionally rare malignant tumor with a high risk of local recurrence and metastasis. Only a few cases have been reported in the literature, making diagnosis and management challenging.

Methods: We report the case of a 66-year-old man presented with progressive left-eye proptosis, pain, and severe visual loss. Clinical examination, orbital CT and MRI, histopathological analysis, immunohistochemistry, and a systemic metastatic workup were performed. The patient underwent surgical excision with orbital exenteration followed by adjuvant radiotherapy.

Results: Imaging revealed a large intra- and extra-conal orbital mass with optic nerve involvement. Histopathological examination confirmed mucinous adenocarcinoma with CK7 positivity and no evidence of a primary tumor elsewhere, supporting the diagnosis of primary orbital mucinous adenocarcinoma. Complete surgical resection was achieved; however, locoregional recurrence was detected during follow-up.

Conclusion: Primary orbital mucinous adenocarcinoma is an extremely rare and locally aggressive neoplasm. Accurate diagnosis requires thorough histopathological evaluation and exclusion of metastatic disease. Wide surgical excision remains the cornerstone of treatment, although close long-term surveillance is essential because of the high risk of recurrence.

P11 - An unusual dural-based glioblastoma mimicking extra-axial neoplasm

Mohamed Znazen, M. Taallah, A. Hachicha, H. Belmabrouk,
Department of Neurosurgery, University Hospital of Gabès, Tunisia

Background: Glioblastoma is the most common primary malignant brain tumor in adults. Although its imaging characteristics are usually distinctive, atypical presentations may mimic a variety of intracranial lesions, including meningiomas, lymphoma, abscesses, vascular malformations, and, more rarely, metastases. Such diagnostic overlap may affect preoperative planning and surgical strategy.

Methods: We report a rare case of glioblastoma presenting as a dural-based lesion highly suggestive of dural metastasis.

Results: A 74-year-old man presented with progressive signs of intracranial hypertension and frontal lobe syndrome evolving over three months. Neurological examination revealed cognitive and behavioral disturbances without focal neurological deficits. Brain magnetic resonance imaging demonstrated a left frontal mass measuring 40 × 46 mm with an apparent extra-axial location. The lesion was isointense on T1-weighted sequences and showed heterogeneous contrast enhancement associated with a broad dural attachment and adjacent dural thickening, strongly suggesting a dural metastasis. The patient underwent surgical resection. Intraoperatively, the tumor was found to infiltrate both the underlying cerebral cortex and the adjacent dura mater. Gross total resection was performed, including the infiltrated dura mater. Histopathological examination unexpectedly revealed glioblastoma, WHO grade 4. The postoperative course was uneventful, and the patient was referred for standard adjuvant chemoradiotherapy with temozolomide.

Conclusions: Glioblastoma may rarely present as a dural-based lesion with radiological features closely resembling a dural metastasis. Awareness of this unusual presentation is essential for neurosurgeons and neuroradiologists. Histopathological examination remains the definitive diagnostic tool, while careful interpretation of imaging findings may help avoid preoperative diagnostic pitfalls and optimize management.

P12 - Anterior cervical discectomy and fusion at C2–C3: technical feasibility and clinical outcomes in three cases

Khalil Ayadi, F Kolsi, B Kammoun, MZ Boudawara

Department of Neurosurgery, Habib Bourguiba University Hospital, Sfax, Tunisia

Background: Anterior cervical discectomy and fusion (ACDF) is a well-established procedure for cervical spinal cord and nerve root decompression while providing segmental stabilization through interbody fusion. Although routinely performed at the lower cervical levels (C4–C7), ACDF at C2–C3 is uncommon because of the complex anatomy of the upper cervical region and the technical challenges associated with surgical exposure. We report our recent experience with three patients who underwent ACDF involving the C2–C3 level.

Methods: Three male patients underwent ACDF at the C2–C3 level during the current year. The first two patients, aged 31 and 43 years, presented after cervical trauma resulting from road traffic and domestic accidents, respectively. Both were neurologically intact, and computed tomography demonstrated bilateral C2 pedicle fractures associated with C2–C3 anterolisthesis. Each underwent single-level C2–C3 ACDF. The third patient, a 20-year-old man with Type 1 neurofibromatosis and a previous C1–C2 laminectomy for cervical cord compression, presented with progressive gait impairment and spastic quadriparesis. Imaging revealed instability with anterolisthesis at C2–C3 and C3–C4, and he underwent two-level ACDF from C2 to C4.

Results: Surgery was completed in all three cases without major intraoperative complications. Postoperatively, the two trauma patients achieved stable fixation with satisfactory radiological alignment and remained neurologically intact. The patient with neurofibromatosis experienced significant neurological improvement, particularly in gait and motor function. All patients had favorable clinical and radiological outcomes during follow-up.

Conclusions: ACDF involving the C2–C3 level is a technically demanding but feasible procedure for selected patients with upper cervical instability. Careful preoperative planning, meticulous surgical technique, and thorough knowledge of the regional anatomy allow safe treatment with favorable clinical and radiological outcomes.

P13 - Anterior clinoid meningioma resection: technical nuances and pitfalls in surgical management

Kamel Bouaita, S. Benallag, A. Mati, A. Meliani, T. Selmane

Neurosurgery Departement EHS Cherchell, Blida Faculty of Medecine, Algeria.

Background: Anterior clinoid meningiomas remain among the most challenging skull base tumors due to their intimate relationship with the optic apparatus, internal carotid artery, and cavernous sinus. Surgical management requires balancing maximal safe resection with preservation of neurological and visual function. This study evaluates surgical outcomes and highlights the main operative pitfalls encountered during resection of anterior clinoidal meningiomas.

Methods: A retrospective analysis was performed on 20 consecutive patients with anterior clinoidal meningiomas who underwent microsurgical resection at the Department of Neurosurgery, Cherchell Hospital, between January 2020 and January 2026. All patients underwent surgery through a standard pterional craniotomy approach. Preoperative and postoperative ophthalmological evaluations were systematically performed. Clinical, radiological, surgical, and follow-up data were reviewed. Follow-up ranged from 3 to 42 months.

Results: Gross total resection was achieved in 13 patients (65%). Visual impairment was the most common presenting symptom, and 60% of affected patients experienced significant postoperative visual improvement. Permanent complications occurred in two patients. Tumor recurrence was observed in 15% of cases during follow-up. The principal surgical pitfalls identified included tumor adherence to the internal carotid artery and optic nerve, difficulties related to cavernous sinus extension, and challenges in achieving radical resection while preserving neurovascular structures.

Conclusion: Anterior clinoidal meningiomas remain surgically demanding lesions with substantial anatomical complexity. Careful microsurgical dissection, detailed knowledge of skull base anatomy, and prioritization of neurovascular preservation are essential to optimize outcomes. Although gross total resection may not always be feasible, satisfactory tumor control and visual outcomes can be achieved with an individualized surgical strategy focused on maximal safe resection.

P14 - Anterior clinoid meningiomas: is one strategy suitable for all? lessons from two cases requiring tailored skull base surgery

Farah Bahri, G.Gader, H.Hdhili, S.Ben Yakoub, M. Bounemra, A.Hermassi, S.Ben Zekri, A.Bedioui, M.Rkhami, M.Badri, K.Bahri, I.Zammel

Department of Neurosurgery, Ben Arous Trauma Center, Tunisia

Background: Anterior clinoid meningiomas represent one of the most challenging skull base tumors because of their intimate relationship with the optic apparatus, internal carotid artery (ICA), and cavernous sinus. Surgical management requires balancing maximal tumor removal with preservation of neurological and visual function. We present two cases illustrating how differences in tumor extension necessitate individualized surgical strategies.

Methods: Two women aged 49 and 61 years presented with progressive visual impairment and chronic headaches. MRI demonstrated anterior clinoid meningiomas in both patients; however, the pattern of neurovascular involvement differed considerably. The first patient had a predominantly extradural lesion with optic canal invasion, whereas the second exhibited circumferential ICA encasement and extension toward the cavernous sinus. Both patients underwent microsurgical resection through a pterional skull base approach with anterior clinoidectomy adapted to the individual anatomy. Optic canal decompression and meticulous microsurgical dissection of the ICA and cranial nerves were performed when indicated.

Results: Gross-total resection was achieved in the first patient, while a planned subtotal resection was performed in the second to preserve critical neurovascular structures. Histopathology confirmed WHO grade I meningioma in both cases. Visual function improved in the first patient and remained stable in the second. No permanent new neurological deficits or vascular complications occurred. Residual tumor in the second patient was scheduled for postoperative radiosurgical surveillance.

Conclusion: Anterior clinoid meningiomas should not be approached with a uniform surgical philosophy. The extent of optic canal invasion, ICA encasement, and cavernous sinus involvement should guide the degree of resection rather than the pursuit of radical excision at all costs.These two cases emphasize that individualized skull base strategies combining anterior clinoidectomy, optic nerve decompression, and judicious resection can achieve favorable functional outcomes while minimizing morbidity.

P15 - Assessment of professional practices related to vancomycin use in neurosurgery: prescribing patterns, administration practices, and therapeutic drug monitoring

Ben Azouz Chayma[1], Chayma Ben Azouz[1], Emna Bokri[1], Malek Sellami[1], Nesrine Hasni[1], Jalel Kallel[2]

[1] Pharmacy department, Tunisian institue of Neurology, Mongi Ben Hamida

[2] Neurosurgery Department, Tunisian institue of Neurology, Mongi Ben Hamida

Background: Vancomycin remains a first-line antimicrobial agent for the treatment of severe neurosurgical infections caused or suspected to be caused by resistant Gram-positive pathogens.However, its narrow therapeutic index requires individualized rigorous monitoring. This study aimed to evaluate professional practices related to vancomycin prescribing, administration, and therapeutic monitoring in a tunisian neurosurgical department.

Methods: A prospective observational study was carried out over a four-month period and included patient recieving vancomycin in neurosurgery department . Data were collected on patient demographics, clinical indications, renal function, adherence of prescriptions to established recommendations, administration practices, therapeutic drug monitoring(TDM) and pharmaceutical interventions. All variables were analyzed using descriptive statistical methods.

Results: A total of 43 patients were evaluated, with a male predominance (M/F ratio = 2.91). The mean age was 44 years (7–82 years) and the mean BMI was 24.5 ± 4.6 kg/m². Renal function was normal in 90.7% of cases. Vancomycin prescriptions were compliant with recommendations in 90.7% of patients, and dosage adjustment according to renal function was appropriate in 86.0%. Meningitis was the main indication (72.1%), followed by brain abscesses (11.6%), empyema (9.3%), and valve-related infections (7.0%). The mean treatment duration was 23 ± 7 days. All preparations complied with recommended reconstitution and dilution procedures, and administration was predominantly intermittent. No concomitant nephrotoxic drugs or agents affecting vancomycin pharmacokinetics were identified. TDM was performed in only 21% of patients, resulting in dose adjustment in 16%. A total of thirty-two pharmaceutical interventions were performed, mainly targeting medication administration and prescription practices. However, 75% of interventions were not accepted.

Conclusions: Vancomycin prescribing and administration practices in neurosurgery were generally compliant with current recommendations. Nevertheless, the low rate of therapeutic drug monitoring highlights a major area for improvement. Strengthening interdisciplinary collaboration and implementing systematic TDM may optimize treatment efficacy while minimizing toxicity risks.

P16 - Association between parkinson's disease and meningiomas: a report of two cases

Imen Dammak[1], Jihene Ketata[1], Ines Cherif[2], Hichem Ammar[2]

[1] Department of Neurology, Sfax Military University Hospital, Tunisia

[2] Department of Neurosurgery, Sfax Military University Hospital, Tunisia

Introduction: The association between Parkinson's disease and intracranial meningioma is rare and may raise diagnostic challenges, particularly when focal neurological signs or clinical worsening are mistakenly attributed to the progression of Parkinson's disease. We report two cases illustrating this association.

Case Reports: The first case involved a 46-year-old patient who had been followed since 2022 for a right-sided tremor-akinetic-rigid parkinsonian syndrome. The disease began in 2022 with the onset and progressive worsening of resting tremor, rigidity, and hypokinesia, initially affecting the right hemibody, with secondary bilateral involvement over the past few months. Levodopa responsiveness exceeded 55%, supporting the diagnosis of Parkinson's disease. Brain imaging, performed as part of the etiological workup for headaches, revealed a 2-cm right temporal meningioma. In the absence of any evident direct clinical impact, surgical abstention with regular follow-up was decided. The second case involved a 65-year-old patient with a history of hypertension and dyslipidemia, followed for Parkinson's disease evolving for two years, presenting as an asymmetric akinetic-rigid form predominantly affecting the left side. The disease was well controlled with levodopa at a dose of 125 mg three times daily, combined with Trivastal LP 50 mg, three tablets daily. The recent history dated back three months and was marked by the onset of left hemibody heaviness, associated with dysarthria, frontal syndrome, and visual disturbances. Brain imaging revealed a large, 6-cm, parasagittal extra-axial intracranial mass suggestive of a meningioma. The patient underwent surgical resection of the meningioma, with a favorable postoperative course and improvement of the motor deficit.

Discussion: The first case typically illustrates the incidental discovery of a meningioma whose location did not explain the parkinsonian syndrome.The second case highlights the diagnostic difficulty posed by the association of a parkinsonian syndrome with an ipsilateral extra-axial intracranial lesion. However, the good response to dopaminergic therapy supported the diagnosis of Parkinson's disease. Nevertheless, some studies have reported significant levodopa responsiveness in patients with meningioma.

Conclusion: The association between intracranial meningioma and Parkinson's disease requires careful clinical analysis. Any unusual clinical worsening or the appearance of focal neurological signs in a patient with Parkinson's disease should prompt investigation for an associated intracranial lesion.

P17 - Athetosis: a rare manifestation of vitamin B12 deficiency

Imen Dammak[1], Jihene Ketata[1], Ines Cherif[2], Hichem Ammar[2]

[1] Department of Neurology, Sfax Military University Hospital, Tunisia

[2] Department of Neurosurgery, Sfax Military University Hospital, Tunisia

Introduction: Vitamin B12 deficiency is responsible for various neurological manifestations, mainly peripheral neuropathies and spinal cord involvement. Movement disorders, particularly athetosis, represent a rare presentation.

Case report: We report the case of a female patient presenting with slow, involuntary, writhing movements of athetoid type, with progressive onset and worsening. Neurological examination did not reveal any other associated extrapyramidal, pyramidal, or sensory signs. Laboratory investigations showed vitamin B12 deficiency associated with elevated homocysteine levels. Further etiological workup did not identify any other obvious cause. Brain MRI showed no abnormalities. Vitamin B12 supplementation was initiated, leading to progressive and almost complete improvement of the symptoms.

Discussion: The neurological manifestations of vitamin B12 deficiency are polymorphic and may be inaugural. The neurological spectrum of this deficiency continues to expand. Athetosis remains an unusual presentation, probably related to involvement of the extrapyramidal pathways or to demyelinating mechanisms.

Conclusion: Vitamin B12 deficiency should be considered in patients presenting with unexplained movement disorders of late onset and a negative etiological workup. Early diagnosis allows simple and potentially reversible management through vitamin supplementation.

P18 - Beyond a simple skull lesion: surgical treatment of a progressive calvarial hemangioma

Mohamed Amine Hmida, H.Benselma, R.Benfredj, A.Mribah, O.Hattab, I.Ksira

Department of Neurosurgery, Sahloul Hospital, Sousse, Tunisia

Introduction: Intraosseous hemangioma is a rare benign bone tumor of the skull, often asymptomatic and incidentally discovered. When involving the calvarium, it may pose diagnostic and therapeutic challenges because of its rarity and the broad spectrum of differential diagnoses.

Case presentation: We report the case of a 64-year-old woman with Widal syndrome who presented with a left parietal scalp swelling associated with localized pain. Computed tomography (CT) and magnetic resonance imaging (MRI) revealed a well-circumscribed expansile lesion of the calvarium, highly suggestive of an intraosseous hemangioma. Management and Treatment: Although the lesion exhibited slow growth, a progressive increase in size was observed over time, making conservative management undesirable. The patient underwent surgical resection, achieving complete excision of the lesion. Postoperative recovery was uneventful, and the patient is currently scheduled for cranioplasty.

Discussion: Calvarial intraosseous hemangiomas are uncommon benign tumors that require careful evaluation to exclude more aggressive pathologies. Management strategies depend on lesion size, clinical presentation, cosmetic concerns, and radiological progression. Observation remains appropriate for asymptomatic and stable lesions, whereas surgery is indicated for symptomatic, enlarging, or cosmetically deforming lesions.

Conclusion: This case highlights the importance of thorough clinical and radiological assessment in the diagnosis of calvarial intraosseous hemangiomas. An individualized management strategy and close follow-up allow effective treatment while minimizing unnecessary invasive interventions.

P19 - Beyond degeneration: lumbar spinal stenosis unmasking acromegaly – a two-case experience

Houssem Hdhili, S.Farhat, A.Rachdi, B.Shil, S.Achoura, A.Harbaoui, R.Chkili, M.D.Yedeas, K.Radhouane

Department of Neurosurgery, Military Hospital of Tunis, Tunisia

Background: Musculoskeletal manifestations are common in acromegaly and may significantly impair quality of life. Lumbar spinal stenosis secondary to vertebral and ligamentous overgrowth is an uncommon but potentially revealing manifestation. We report two cases in which symptomatic lumbar canal stenosis led to the diagnosis of previously unrecognized acromegaly.

Methods: Two patients followed at the Military Hospital of Tunis presented with chronic low back pain associated with neurogenic claudication. Lumbar magnetic resonance imaging demonstrated severe degenerative canal stenosis. Clinical examination revealed characteristic acromegalic features, prompting endocrine evaluation and pituitary imaging. Clinical, radiological, endocrine, and therapeutic data were retrospectively reviewed.

Results: Both patients exhibited elevated growth hormone and insulin-like growth factor-1 levels, and pituitary magnetic resonance imaging confirmed the presence of a pituitary adenoma. In one patient, disabling symptoms due to severe lumbar stenosis necessitated decompressive surgery, resulting in significant improvement of radicular pain and walking capacity. The second patient was managed conservatively and referred for endocrinological treatment. In both cases, recognition of acromegalic features enabled the diagnosis of an underlying systemic disease that had remained previously undetected.

Discussion: Spinal involvement in acromegaly results from hypertrophy of vertebral structures, intervertebral discs, and ligamentum flavum, leading to progressive canal narrowing. Because lumbar spinal stenosis may precede the diagnosis of acromegaly, neurosurgeons and spine surgeons should maintain a high index of suspicion when encountering severe or disproportionate degenerative changes associated with suggestive somatic features. Early recognition allows multidisciplinary management and may prevent further systemic complications.

Conclusion: Lumbar spinal stenosis may constitute the presenting feature of acromegaly. Awareness of this rare association is essential for timely diagnosis and appropriate management. Spine surgeons may play a pivotal role in identifying this endocrine disorder.ent Presentation here

P20 - Beyond pulmonary disease: a rare case of cerebral tuberculoma complicated by post-infectious vasculitis

Mohamed Znazen, A. Hachicha, H. Belmabrouk

Department of Neurosurgery, University Hospital of Gabès, Tunisia

Background: Tuberculosis (TB) remains a major public health concern worldwide. Central nervous system (CNS) involvement accounts for approximately 5–10% of extrapulmonary TB cases and is associated with significant morbidity and mortality. Cerebral tuberculomas are uncommon manifestations that may mimic intracranial tumors on neuroimaging, making diagnosis challenging. In addition, TB-associated cerebral vasculitis is a rare but severe complication that can lead to ischemic stroke and permanent neurological deficits.

Methods: We report a rare pediatric case of cerebral tuberculoma complicated by post-infectious cerebral vasculitis. An 13-year-old immunocompetent boy with no significant past medical history was admitted with progressive headaches, recurrent vomiting, seizures, and weight loss. Neurological examination was unremarkable and revealed no focal motor or sensory deficits.

Results: Brain imaging, including computed tomography and magnetic resonance imaging, demonstrated two left frontal ring-enhancing lesion measuring 25 × 15 mm and 10 × 10 mm respectively, with surrounding edema, initially suggestive of a brain tumor. The diagnosis of cerebral tuberculoma was retained in light of the clinical and radiological context, a family history of pulmonary tuberculosis, and positive biological and microbiological test results. Antituberculous therapy was initiated. Tow weeks after treatment onset, the patient developed acute left-sided hemiparesis, predominantly involving the upper limb. Follow-up brain imaging revealed an ischemic stroke secondary to post-infectious cerebral vasculitis. The patient underwent intensive rehabilitation while continuing antituberculous treatment. Progressive neurological improvement was observed during follow-up. After six months of therapy, the patient demonstrated significant clinical recovery with partial resolution of motor deficits and favorable radiological evolution.

Conclusions: Cerebral tuberculoma should be considered in the differential diagnosis of ring-enhancing intracranial lesions, particularly in TB-endemic regions. This case underscores the potential occurrence of post-infectious cerebral vasculitis despite appropriate treatment and highlights the importance of close neurological monitoring. Early diagnosis and prompt management are essential to improve outcomes and minimize long-term neurological sequelae.

P21 - Beyond removal: emerging strategies for managing infected spinal instrumentation without compromising stability

Firas Akrout, Rachdi M.A., Kammoun T, Bouzouita K, Yedeas MD, Achoura S, Chkili Ridha, Radhouen K.

Neurosurgery Department, Military Hospital of Tunis, Tunis, Tunisia

Background & objectives: Surgical site infection following instrumented spinal fusion creates a challenging therapeutic dilemma: hardware removal eradicates the infectious nidus but risks catastrophic mechanical instability before bony fusion is achieved, while retention preserves stability but confronts the formidable antimicrobial resistance of bacterial biofilm. Traditional management defaulted to systematic hardware removal once infection was confirmed; however, emerging evidence increasingly supports selective retention strategies. This review examines current and emerging approaches to managing infected spinal instrumentation while minimizing the stability-sterility trade-off.

Methods: Narrative review of PubMed, Scopus, and Cochrane databases (2010–2024), including cohort studies, microbiological analyses, and consensus guidelines addressing biofilm pathophysiology, debridement protocols, hardware retention outcomes, and emerging anti-biofilm technologies in instrumented spinal infection.

Results & discussion: Biofilm pathophysiology: Bacterial biofilm formation on instrumentation creates a protected extracellular matrix conferring antibiotic resistance up to 1,000-fold compared to planktonic bacteria, explaining persistent infection despite adequate systemic antimicrobial therapy and underscoring the limitations of antibiotics alone.Hardware retention with aggressive debridement: Current evidence supports retention in cases of early infection (within 90 days) or solid partial fusion, combined with thorough surgical debridement, irrigation, and prolonged targeted antibiotic therapy, achieving infection control rates of 70–85% while preserving construct stability.Local antimicrobial delivery: Antibiotic-loaded calcium sulfate beads, vancomycin powder application, and antibiotic-eluting coatings provide sustained local antimicrobial concentrations directly at the biofilm interface, demonstrating reduced reinfection rates in recent cohort series. Emerging anti-biofilm technologies: Bacteriophage therapy, biofilm-disrupting enzymes, ultrasonic debridement, and silver- or antimicrobial peptide-coated implants represent promising investigational strategies specifically targeting biofilm matrix disruption rather than relying solely on systemic antibiotic penetration. Removal indications: Hardware removal remains indicated in late chronic infection, solid fusion achievement, mechanical failure, or treatment failure despite optimized retention strategies.

Conclusion: Management of infected spinal instrumentation is shifting from reflexive removal toward individualized, biofilm-targeted retention strategies. Emerging local antimicrobial and anti-biofilm technologies offer genuine promise in resolving the stability-sterility dilemma without sacrificing construct integrity.

P22 - Beyond the pedicle: anatomical lessons from an S1 screw malposition

Ahmed Amine Daoued, A. Trifa, G.Elkahla, K.Maamri, M.Darmoul
Neurosurgery Departement, Fattouma Bourguiba University Hospital of Monastir

Background: Postoperative radiculopathy after lumbosacral instrumentation is an uncommon but potentially serious complication. At the S1 level, screw trajectory and length are critical because an excessively lateral, anterior, or bicortical direction may place neural structures at risk along the sacral ala. This case highlights the anatomical relevance of S1 screw positioning and the importance of early recognition of implant-related neurological complications.

Methods: We report a single-center case of a patient who underwent posterior decompression and instrumented fusion for multilevel lumbar stenosis, including S1 pedicle screw fixation. In the early postoperative period, the patient developed acute radicular pain associated with motor deficit, including weakness of ankle dorsiflexion and extensor hallucis longus. Computed tomography was performed to assess screw positioning and identify a possible mechanical cause.

Results: Postoperative CT demonstrated an anterolateral trajectory of the S1 pedicle screw with anterior cortical breach, suggesting possible contact with neural structures along the sacral ala. Given the concordance between the clinical deficit and radiological findings, urgent revision surgery was performed. The misplaced screw was removed and replaced using a shorter and more medially directed trajectory, with intraoperative neurophysiological monitoring. Early postoperative management included mobilization and standardized neurological follow-up.

Conclusions: S1 pedicle screw malposition is a preventable cause of postoperative radiculopathy. This case emphasizes the close anatomical relationship between the anterior sacral cortex and adjacent neural structures, particularly when screws are directed too laterally or inserted with excessive length. Prevention relies on careful preoperative planning, appropriate screw length, medialized trajectory, reliable anatomical landmarks, and postoperative vigilance. When new radicular symptoms occur after lumbosacral fixation, early CT assessment and prompt revision may improve neurological outcome.

P23 - Beyond the spine: the impact of associated injuries on mortality following cervical trauma

Mohamed Amine Hmida, K.Maamri, R.Benmhennia, M.Alikhlifa, K.Bouattour, M.Darmoul

Neurosurgery Department, Fattouma Bourguiba University hospital, Monastir, Tunisia.

Introduction: Subaxial cervical spine trauma rarely occurs as an isolated injury. Due to the high-energy mechanisms frequently involved, such as road traffic accidents and falls from height, patients often present with multiple associated injuries. The coexistence of cranial, thoracic, abdominal, or orthopedic trauma creates significant therapeutic challenges, as these injuries may compromise hemodynamic stability and delay definitive spinal management.

Objective: To evaluate the impact of associated systemic injuries on morbidity, mortality, and length of hospital stay in patients sustaining subaxial cervical spine trauma.

Materials and methods: A retrospective study was conducted on 34 patients admitted for subaxial cervical spine trauma. Patients were divided into two groups for comparative analysis: Isolated Trauma Group: cervical spine injury without major associated lesions. Polytrauma Group: cervical spine injury associated with at least one major extra-spinal visceral or musculoskeletal injury. Primary outcome measures included systemic complication rates, length of hospital stay, and 30-day survival.

Results: Associated injuries were identified in 38.2% of patients, highlighting the high prevalence of polytrauma in this population. Polytraumatized patients demonstrated significantly worse outcomes compared with those sustaining isolated cervical injuries. A strong correlation was observed between the presence of associated injuries and increased morbidity and mortality. Notably, 75% of all deaths occurred within the polytrauma group. The leading causes of death were neurogenic shock compounded by internal hemorrhage and severe respiratory failure. In addition, patients with associated injuries experienced significantly longer hospital stays, reflecting the need for prolonged intensive care management and multiple surgical or medical interventions.

Conclusion: Associated injuries represent a major determinant of mortality in patients with subaxial cervical spine trauma. Their presence transforms a specialized spinal emergency into a complex life-threatening condition requiring coordinated multidisciplinary management. Improved outcomes depend on early collaboration among neurosurgeons, trauma surgeons, and critical care specialists, prioritization of life-saving interventions according to damage-control principles, and timely cervical spine management once physiological stabilization has been achieved.

P24 - Beyond the tumor removal: the medical role of the neurosurgeon in pituitary macroadenoma management

Kais Bouzouita, Affes A, Rachdi M.A., Kammoun T, Yedeas MD, Achoura S, Chkili Ridha, Radhouen K.

Neurosurgery Department, Military Hospital of Tunis, Tunis, Tunisia

Background & objectives: Pituitary macroadenoma management is inherently multidisciplinary, yet the neurosurgeon's role is frequently confined to the operative act itself. Pre- and postoperative medical responsibilities — including visual assessment, hormonal evaluation, diabetes insipidus surveillance, adrenal insufficiency prevention, and ophthalmic follow-up — are critical determinants of overall patient outcomes that demand active neurosurgical engagement beyond the operating room. This review defines and advocates for a comprehensive medical role for the neurosurgeon throughout the entire pituitary macroadenoma management continuum.

Methods: Narrative review of PubMed, Scopus, and Cochrane databases (2010–2024), including clinical guidelines, prospective cohort studies, and consensus statements from pituitary societies addressing preoperative assessment, surgical outcomes, and postoperative complication surveillance in pituitary macroadenoma management.

Results & discussion: Preoperative visual assessment: Formal perimetry and visual acuity testing are mandatory before transsphenoidal surgery, establishing baseline deficits, predicting chiasmal decompression potential, and providing medico-legal documentation. The neurosurgeon must directly interpret and integrate these findings into surgical planning and timing decisions. Hormonal evaluation: Comprehensive preoperative pituitary axis assessment — including cortisol, thyroid, gonadal, and growth hormone axes — identifies pre-existing deficiencies requiring hormonal replacement before surgery and stratifies perioperative risk, particularly regarding adrenal reserve adequacy. Adrenal insufficiency prevention: Perioperative glucocorticoid supplementation protocols must be neurosurgeon-initiated, given the risk of acute adrenal crisis following corticotroph adenoma removal or normal corticotroph suppression. Failure to implement timely steroid coverage carries life-threatening consequences directly attributable to inadequate surgical medical planning. Diabetes insipidus surveillance: Postoperative monitoring of urine output, serum sodium, and osmolality within the first 72 hours is essential for early detection of transient or permanent diabetes insipidus, requiring neurosurgeon-directed desmopressin titration and electrolyte management. Ophthalmological follow-up: Serial postoperative visual field and acuity assessments quantify chiasmal decompression outcomes, detect delayed visual deterioration from tumor remnant or scarring, and guide adjuvant therapy decisions.

Conclusion: The neurosurgeon managing pituitary macroadenomas must embrace an active, longitudinal medical role extending from preoperative visual and hormonal assessment to postoperative endocrine and ophthalmic surveillance, ensuring comprehensive patient-centered care beyond technical tumor removal.

P25 - Beyond the tumor: psychological impact of brain surgery on patients and their families — a neglected dimension of neurosurgical care

Ameur Affes, Bouzouita K, Rachdi M.A., Kammoun T, Yedeas MD, Achoura S, Chkili Ridha, Radhouen K.

Neurosurgery Department, Military Hospital of Tunis, Tunis, Tunisia

Background & objectives: Neurosurgical outcomes are traditionally measured in survival, recurrence, and neurological function. Yet brain surgery fundamentally alters identity, cognitive self-perception, emotional regulation, and family dynamics in ways that extend far beyond measurable neurological deficits. The psychological burden borne by patients and caregivers following cranial neurosurgery remains systematically underassessed and underaddressed in routine neurosurgical practice. This review examines the psychological impact of brain surgery on patients and families, and advocates for its integration into comprehensive neurosurgical care.

Methods: Narrative review of PubMed, Scopus, and PsycINFO databases (2000–2024), including prospective cohort studies, qualitative research, and patient-reported outcome analyses addressing psychological morbidity, caregiver burden, and psychosocial recovery following cranial neurosurgical procedures.

Results & discussion: Patient psychological morbidity: Depression and anxiety affect 30–50% of patients following brain tumor surgery, glioma resection, and aneurysmal subarachnoid hemorrhage, persisting beyond neurological recovery and independently predicting functional outcome, rehabilitation compliance, and quality of life. Fear of recurrence, altered body image, and cognitive self-stigma represent underrecognized contributors to long-term psychological disability. Identity and personality changes: Frontal and temporal lobe surgery, even when neurologically successful, produces subtle but profoundly distressing personality changes — emotional dysregulation, impulsivity, apathy — that patients and families attribute to a fundamental loss of self, rarely addressed in standard surgical follow-up consultations. Caregiver burden: Family members of brain surgery patients demonstrate clinically significant rates of anxiety, depression, and burnout, particularly when managing behavioral sequelae or supporting patients through adjuvant oncological treatments, yet remain invisible to neurosurgical care pathways. Integration into care: Systematic preoperative psychological baseline assessment, structured postoperative psychological support referral, and caregiver-inclusive follow-up consultations represent evidence-informed interventions demonstrably improving patient-reported outcomes without increasing healthcare resource consumption disproportionately.

Conclusion: The brain is not merely an anatomical operative field — it is the seat of identity, emotion, and relationship. Neurosurgical care that ignores its psychological dimension provides incomplete treatment. Integrating systematic psychological support for patients and families is both ethically necessary and clinically impactful.

P26 - Beyond the X-ray: artificial intelligence as a predictive tool for pseudarthrosis after lumbar fusion — a systematic review

Majdouline Barkache, Akrout F, Rachdi MA, Hdhili H, Farhat S, Chkili R, Radhouen K

Neurosurgery Department, Military Hospital of Tunis, Tunis, Tunisia

Background & objectives: Pseudarthrosis following lumbar spinal fusion represents a leading cause of failed back surgery syndrome, occurring in up to 15–20% of cases depending on surgical technique, patient profile, and follow-up duration. Its prediction remains notoriously challenging: conventional radiological assessment suffers from poor sensitivity, interobserver variability, and delayed detectability. Artificial intelligence (AI) — encompassing machine learning, deep learning, and radiomics — has emerged as a promising adjunct for early, objective pseudarthrosis risk stratification. This systematic review appraises current evidence on AI-based predictive models for pseudarthrosis after lumbar fusion and evaluates their clinical applicability.

Methods: A systematic review was conducted following PRISMA guidelines across PubMed, Scopus, Embase, and IEEE Xplore databases (2010–2024). Studies reporting AI-based models predicting pseudarthrosis or fusion failure after lumbar arthrodesis were included. Model architecture, input variables, performance metrics, and validation methodology were critically assessed.

Results & discussion: Fourteen studies met inclusion criteria, encompassing machine learning classifiers, convolutional neural networks, and radiomics-based pipelines. Input variables included preoperative clinical factors (BMI, bone mineral density, smoking status, diabetes), intraoperative parameters (cage positioning, lordosis correction, screw density), and postoperative imaging features (CT-based trabecular bridging, DEXA). AI models consistently outperformed conventional radiological assessment, achieving AUC values ranging from 0.78 to 0.94. CT-based deep learning demonstrated superior performance over plain radiograph analysis. However, significant heterogeneity in outcome definition, follow-up duration, and external validation limited cross-study comparability. No prospective multicenter validation study currently exists.

Conclusion: AI-based models represent a genuine paradigm shift in pseudarthrosis prediction after lumbar fusion, offering earlier, more objective, and more accurate risk stratification than conventional imaging alone. Prospective multicenter validation and standardization of fusion outcome definitions are prerequisites before clinical implementation. The question is no longer whether AI can predict pseudarthrosis — but when it will become standard of care.

P27 - Biermer's disease revealed by abducens nerve palsy

Imen Dammak[1], Jihene Ketata[1], Ines Cherif[2], Hichem Ammar[2]

[1] Department of Neurology, Sfax Military University Hospital, Tunisia

[2] Department of Neurosurgery, Sfax Military University Hospital, Tunisia

Introduction: Diplopia caused by isolated abducens nerve palsy is most often of vascular, compressive, or inflammatory origin. Metabolic causes, particularly vitamin B12 deficiency, remain rare but are reversible with early treatment.

Case report: We report the case of a 63-year-old man, followed for benign prostatic hyperplasia, who presented with rapidly progressive horizontal binocular diplopia on left gaze, associated with ipsilateral headache. Clinical examination revealed isolated left convergent strabismus, with no sensorimotor deficit and no fundoscopic abnormalities. The ice pack test and prostigmine test were negative. Brain MRI with MR angiography, as well as lumbar puncture, were normal. Laboratory investigations revealed mild normochromic normocytic anemia, low vitamin B12 level at 167 ng/L, and elevated homocysteine level at 15.7 µmol/L. Initial treatment with methylprednisolone boluses did not result in improvement. Intensive vitamin B12 supplementation was then initiated, with marked improvement from the first week followed by complete recovery. The presence of anti-intrinsic factor antibodies and anti-parietal cell antibodies supported the diagnosis of Biermer's disease.

Discussion: Isolated abducens nerve involvement in the setting of vitamin B12 deficiency is exceptional. In this case, the negative etiological workup and favorable outcome under vitamin supplementation supported a deficiency-related origin.

Conclusion: Vitamin B12 deficiency should be considered in any unexplained isolated diplopia. Early diagnosis allows complete recovery with replacement therapy.

P28 - Bilateral choroid plexus xanthogranulomas: radiological features and diagnostic awareness—a case report and review of the literature

Emna Elouni, Roua Latrach, Nessrine Nessib, Firas Sliti, Slimane Abdelhafidh, Alaa Belhadj, Imed Ben Said, Jalel Kallel

Neurosurgery Departement, National Institute of Neurology, Tunis, Tunisia

Background: Choroid plexus xanthogranulomas are rare, benign intracranial lesions that are usually incidental findings on neuroimaging. Their radiological appearance may mimic other intraventricular pathologies, leading to diagnostic uncertainty. Bilateral involvement is particularly uncommon. Awareness of this entity is essential to avoid misinterpretation and unnecessary investigations.

Methods: We report the case of a 35-year-old female in whom bilateral choroid plexus xanthogranulomas were incidentally discovered on computed tomography (CT) performed after a mild traumatic brain injury. Clinical presentation, neuroimaging findings, and relevant literature were reviewed.

Results: The patient presented with a head injury without neurological deficit. Brain CT revealed bilateral hyperdense lesions within the atria of the lateral ventricles, initially raising concern for intraventricular pathology. Subsequent magnetic resonance imaging demonstrated well-defined bilateral lesions with imaging characteristics consistent with choroid plexus xanthogranulomas, without associated mass effect, hydrocephalus, or abnormal enhancement. The lesions were deemed incidental and unrelated to the trauma. A conservative approach with radiological follow-up was adopted. A review of the literature confirmed the rarity of bilateral involvement and emphasized its benign nature.

Conclusion: Bilateral choroid plexus xanthogranulomas are rare incidental findings that may mimic more serious intraventricular lesions on imaging. Recognition of their typical radiological features is crucial to prevent misdiagnosis and avoid unnecessary interventions. This case highlights the importance of radiological awareness and contributes to the limited literature on bilateral presentation.

P29 - Bilateral chronic subdural hematoma: surgical management and prognostic factors — a retrospective study of 84 cases

Ben Ticha Mehdi, B. Hajji, S. Gallaoui, M. Ben Messaoud, C. Abdelileh, R. Ben Fredj, H. Ben Selma, I. Ksira.

Department of Neurosurgery, Sahloul Hospital, Sousse, Tunisia

Background: Chronic subdural hematoma (CSDH) is one of the most common neurosurgical conditions, particularly among elderly patients receiving antithrombotic therapy. Bilateral CSDH is less frequently reported and raises specific therapeutic considerations regarding the optimal surgical strategy, particularly the choice between unilateral sequential and simultaneous bilateral evacuation, as well as the factors associated with functional outcome and recurrence.

Objective: To evaluate the clinical and radiological characteristics, surgical management strategies, and prognostic factors associated with outcomes in patients with bilateral CSDH.

Methods: We conducted a retrospective, single-center study of 84 consecutive patients who underwent surgical treatment for bilateral CSDH at the Department of Neurosurgery, Sahloul Hospital, between 2018 and 2024. Demographic, clinical, radiological, and therapeutic data were collected, including age, preoperative Markwalder Grade, CT hematoma density (hypodense, isodense, or mixed), hematoma thickness, antiplatelet or anticoagulant therapy, surgical technique (unilateral or bilateral burr-hole evacuation), and use of subdural drainage. Functional outcome was assessed at 3 months using the modified Rankin Scale (mRS).

Results: The mean age was 67.4 ± 12.1 years, with a male-to-female ratio of 2.8:1. A history of head trauma was reported in 61% of patients, while 38% were receiving antithrombotic therapy. Simultaneous bilateral burr-hole evacuation was performed in 72% of cases. The overall recurrence rate was 14.3%. Recurrence was significantly more frequent in patients with mixed-density hematomas ($p = 0.02$) and in those receiving anticoagulant therapy ($p = 0.01$). Favorable functional outcome (mRS ≤ 2) at 3 months was achieved in 81% of patients. Perioperative mortality was 2.4%.

Conclusion: Simultaneous bilateral burr-hole evacuation appears to be a safe and effective surgical strategy for the management of bilateral CSDH. Mixed-density hematoma and anticoagulant therapy were significantly associated with an increased risk of recurrence. Careful perioperative management of antithrombotic therapy may help reduce postoperative morbidity and mortality.

P30 - Bilateral external hydrocephalus in a child with mucopolysaccharidosis type III treated by bilateral ventriculoperitoneal shunting: a rare neurosurgical manifestation

Nader Yahyaoui, Iness Ferchichi, Mohamed Amine Hedj Taieb, Kais Maamri, Mehdi Darmoul

Neurosurgery Department, Fattouma Bourguiba University hospital, Monastir, Tunisia.

Background: External hydrocephalus, also referred to as benign external hydrocephalus of infancy, pseudohydrocephalus, extraventricular hydrocephalus, subdural hygroma, or benign enlargement of the subarachnoid spaces, is characterized by an abnormal accumulation of cerebrospinal fluid (CSF) within the subarachnoid spaces with enlargement of extra-axial fluid compartments. The exact pathophysiology remains uncertain; however, proposed mechanisms include delayed maturation of CSF absorption pathways and developmental imbalance in CSF dynamics , and the condition is typically resolving spontaneously by approximately two years of age. In most infants, the condition is considered benign, although some studies suggest a possible association with neurodevelopmental disorders. Severe symptomatic forms requiring surgical treatment are rare.. Mucopolysaccharidosis type III (MPS III, Sanfilippo syndrome) is a rare lysosomal storage disorder associated with progressive neurodegeneration. Bilateral symptomatic external hydrocephalus has rarely been reported in association with MPS III. We describe the clinical presentation, surgical management, and outcome of this unusual condition.

Methods: An 8-year-old girl with genetically confirmed MPS III, followed at the Pediatric Department of Fattouma Bourguiba University Hospital, Monastir, presented with progressive neurological deterioration characterized by worsening developmental delay, behavioral disturbances, irritability, and altered consciousness. Brain computed tomography (CT) was performed, and postoperative clinical and radiological follow-up was conducted.

Results: Brain CT demonstrated extensive bilateral hemispheric extra-axial CSF collections consistent with bilateral external hydrocephalus. The lesions caused severe compression of the cerebral parenchyma, near-complete collapse of the left lateral ventricle, and a 7-mm midline shift. Given the significant mass effect and neurological decline, the patient underwent bilateral ventriculoperitoneal shunt placement using two proximal catheters connected to a single distal catheter through a Y-connector. Postoperative CT confirmed satisfactory positioning of the shunt system and regression of the mass effect, with complete resolution of the left uncal herniation. Clinical follow-up revealed neurological improvement, including recovery of consciousness and reduction of irritability. Serial imaging demonstrated stabilization of the bilateral extra-axial collections without hemorrhagic or infectious complications.

Conclusions: Bilateral symptomatic external hydrocephalus is an exceptionally rare neurosurgical manifestation. Early diagnosis and prompt management are crucial in patients presenting with neurological deterioration. Bilateral ventriculoperitoneal shunting using a Y-connector appears to be an effective treatment option, providing adequate cerebrospinal fluid diversion and favorable clinical and radiological outcomes.

P31 - Bithalamic fibrillary astrocytoma in an adult: diagnostic challenges of a rare midline glioma

Angham Grioui, Ben Fredj Rihab, Gallaoui Slim, Barkache Majdouline, Ksira Iyadh

Department of Neurosurgery, Sahloul Hospital, Sousse, Tunisia

Background: Bithalamic gliomas are rare tumors in adults and represent a diagnostic and therapeutic challenge due to their deep-seated location, eloquent surrounding structures, and often nonspecific clinical presentation. Histological confirmation is essential for appropriate management, as radiological findings alone may be misleading.

Methods: A 38-year-old woman with a history of tachycardia previously treated with beta-blockers but no longer receiving treatment, presented with transient loss of consciousness and progressive visual impairment. There was no history of fever or head trauma. Neurological examination revealed a Glasgow Coma Scale score of 15/15, cerebellar ataxia, diplopia, and impaired upward gaze of the right eye. The rest of the neurological examination was unremarkable. Routine laboratory investigations were within normal limits. Brain MRI showed a 37 × 47 mm lesion centered on the third ventricle with bilateral thalamic and mesencephalic extension, associated with obstructive hydrocephalus. Owing to the deep location and high surgical risk, a stereotactic biopsy was performed.

Results: Histopathological and immunohistochemical analyses confirmed the diagnosis of a WHO grade 2 fibrillary astrocytoma without evidence of anaplasia.The lesion's unusual bithalamic involvement and associated hydrocephalus accounted for the patient's neurological presentation. Stereotactic biopsy provided a definitive diagnosis while avoiding the morbidity associated with an extensive surgical approach in this eloquent region. The patient was referred to the oncology department for adjuvant radiotherapy and chemotherapy.

Conclusion: Adult bithalamic low-grade astrocytomas are exceptionally uncommon. Clinical manifestations are mainly related to thalamic and brainstem involvement, as well as secondary hydrocephalus. Their radiological appearance often raises a broad differential diagnosis that includes high-grade gliomas, lymphoma, inflammatory disorders, and other diffuse midline lesions. Because extensive surgical resection is generally not feasible, stereotactic biopsy remains the cornerstone of diagnosis and guides subsequent therapeutic decision-making. Early recognition, accurate histopathological diagnosis through stereotactic biopsy, and multidisciplinary management are crucial for optimizing treatment planning and improving patient outcomes.

P32 - Brain metastases from breast cancer: current challenges and management strategies.

Djouadi Yasmina, K.Ait Slamani.F.Z.Si Tayeb.N.Osmani.H.Bourbia .D.Cherfioui.M.Ait Bachir.

Department of Neurosurgery, CHU Nedir Mohamed, Tizi Ouzou, Algeria.

Background: Brain metastases represent one of the most serious complications of breast cancer and are associated with significant morbidity and reduced survival. Their incidence has increased due to improvements in systemic therapies and prolonged patient survival. Certain breast cancer subtypes, particularly HER2-positive and triple-negative tumors, carry a higher risk of central nervous system involvement.

Objective: To provide an overview of the epidemiology, clinical presentation, diagnostic approaches, and current therapeutic strategies for brain metastases arising from breast cancer.

Methods: This presentation reviews the current literature on breast cancer brain metastases, focusing on risk factors, imaging characteristics, and advances in multimodal management.

Results: Patients commonly present with headaches, seizures, focal neurological deficits, or cognitive impairment. Magnetic resonance imaging (MRI) remains the gold standard for diagnosis. Management requires a multidisciplinary approach and may include surgery, stereotactic radiosurgery, whole-brain radiotherapy, and systemic treatments such as targeted therapies and newer agents with central nervous system activity. Prognosis depends on several factors, including performance status, number of brain lesions, extracranial disease control, and molecular subtype of the primary tumor.

Conclusion: Brain metastases from breast cancer remain a major therapeutic challenge. Early detection and individualized multidisciplinary management have significantly improved local disease control and quality of life. Continued advances in targeted therapies and precision medicine offer promising perspectives for improving outcomes in this patient population.

P33 - Brain metastases from rare primary tumors: epidemiological, clinical, radiological and therapeutic features — a monocentric series of 50 cases

Firas Gahbiche[1], F. Kolsi[1], W. Elleuch [2], K. Ayadi[1], B. Essid[1], S. Abdelmoula[1], S. Chaari[1], M. Taallah[1], M. Borni[1], B. Kammoun[1], Boudawara MZ[1].

[1]Neurosurgery department , Habib Bourguiba Hopsital , sfax , Tunisia

[2]Physical Medicine and Rehabilitation , HMUS , sfax , Tunisia

Introduction: Brain metastases (BM) are the most common intracranial tumors in adults, occurring up to ten times more frequently than primary brain malignancies. While lung and breast cancers account for the majority of cases, BM arising from rare primary tumors remain poorly characterized. Few national or international studies have specifically addressed this subgroup. This retrospective study aimed to analyze the epidemiological, clinical, radiological, histological, and therapeutic features of BM from rare origins, and to identify prognostic factors influencing overall survival (OS).

Methods: A retrospective study was conducted in CHU Habib Bourguiba (Sfax)— spanning 2006 to 2024. Patients with BM from primary tumors other than lung or breast cancer were included. Epidemiological, clinical, radiological, histological, therapeutic, and survival data were collected and analyzed. OS and disease-free survival (DFS) were estimated using the Kaplan-Meier method. Statistical significance was set at $p < 0.05$.

Results: Fifty patients were included, with a male predominance (sex ratio 2.87) and a mean age of 54.71 years (range: 10–76). The most frequent presenting symptoms were motor deficits and raised intracranial pressure signs (42% each). Neurological examination was normal in 42% of cases. BM were solitary in 56% of patients and supratentorial in 62%. The most common primary sites were colorectal, bladder, renal, and prostate tumors. Surgery was performed in 26 patients (52%), and 39 received radiotherapy. No stereotactic radiosurgery was available. Complete resection was associated with longer OS. A BM diagnosis preceding that of the primary tumor was identified as a statistically significant poor prognostic factor ($p < 0.05$). Clear cell renal carcinoma was the histological subtype with the best OS. No primary tumor site was independently correlated with significantly better or worse survival.

Conclusion: This series, among the largest focusing exclusively on BM from rare primary tumors in North Africa, highlights the clinical and radiological heterogeneity of this entity. Complete surgical resection and early primary tumor diagnosis remain key prognostic determinants. The absence of stereotactic radiosurgery represents a major therapeutic gap that warrants urgent consideration in resource-limited settings.

P34 - Brainstem lesions in a north african cohort: clinical features, surgical outcomes, and prognostic factors

Balkis Essid, Mehdi Borni, Brahim Kammoun, Souhir Abdelmouleh, Abdelrazek Farikh, Mohamed Zaher Boudawara

Department of Neurosurgery, Hbib Bourguiba University Hospital, Sfax , Tunisia

Background: Expansive brainstem lesions (BSLs) present significant diagnostic and management challenges. This study evaluates the clinical landscape and prognostic factors of BSLs.

Purpose: To report our institutional experience with expansive brainstem lesions in Tunisia, describing their epidemiological, clinical, radiological, therapeutic, and prognostic features, with a comparative analysis of intrinsic versus infiltrating lesions.

Patients and methods: Retrospective study of 48 patients treated over 16 years. Univariate associations were tested using Chi-square, Fisher's exact, and t-tests. Survival was estimated via Kaplan-Meier. Due to the small sample size, multivariable modeling was not feasible.

Results: The cohort (mean age 25 years) showed a 1:1 sex ratio. Common pathologies: gliomas (38%), medulloblastomas (19%), and cavernomas (13%). Complete resection (n=15) was associated with lower recurrence rates (56%) than incomplete resection (71%, p=0.37) or no surgery (75%, p=0.42), though not statistically significant. Postoperative complications occurred in 75%, including meningitis (30%) and cranial neuropathies. Overall mortality was 54%. On univariate analysis, a consultation delay of less than six months (75% mortality vs. 20% for >6 months, p=0.003) and presence of pyramidal syndrome (62% mortality vs. 25%, p=0.021) were associated with higher mortality. Crucially, shorter consultation delay is interpreted as a surrogate marker of aggressive tumor biology rather than a modifiable patient factor.

Conclusion: In our local experience, managing BSLs remains high-risk. While total resection may improve local control, the risk-benefit ratio for high-grade or infiltrating tumors requires careful individualization, including consideration of a primarily diagnostic or palliative role. Our findings may not be generalizable.

P35 - Breast cancer calvarial metastases with dural sinus invasion clinical case and surgical management

Mohammed Al Amine El Farissi, Mohamed Dahamou, Hamid Khay, Khoulali Mohamed

Department of Neurosurgery, Mohammed VI University Hospital, Faculty of Medicine and Pharmacy of Oujda, Mohammed First University, Oujda, Morocco.

Cranial vault metastasis with invasive extension is relatively uncommon but present unique diagnostic and management challenges in the patient with breast cancer. Treatment options are limited, such as local treatment with surgical treatment and radiotherapy. Surgical intervention may be helpful in selected patients for symptomatic relief as well as survival benefit.

P36 - Bullets and the brain: initial management algorithm for penetrating craniocerebral gunshot wounds

Maryem Khayat, Bouzouita K, Rachdi M.A., Kammoun T, Achoura S, Chkili Ridha, Radhouen K

Neurosurgery Department, Military Hospital of Tunis, Tunis, Tunisia

Background & objectives: Penetrating craniocerebral gunshot wounds (PCGW) represent among the most lethal injuries encountered in neurosurgical practice, with prehospital mortality exceeding 50% and significant variability in management protocols across civilian and military settings. Initial decision-making — from prehospital triage to operative intervention — critically determines survival and functional outcome, yet no universally standardized algorithm currently guides early management. This review synthesizes current evidence to propose a structured initial management algorithm for penetrating craniocerebral gunshot wounds.

Methods: Narrative review of PubMed, Scopus, and Cochrane databases (2000–2024), including civilian and military case series, prognostic studies, and major trauma society guidelines (Brain Trauma Foundation, Eastern Association for the Surgery of Trauma) addressing initial assessment, imaging, and surgical decision-making in PCGW.

Results & discussion: Prehospital and resuscitation phase: Standard ATLS principles apply, with particular attention to airway protection in low GCS patients, permissive hypotension avoidance, and rapid transfer to a neurosurgical-capable center given the time-sensitive nature of secondary injury cascades. Initial neurological and radiological assessment: Glasgow Coma Scale at presentation remains the single strongest prognostic indicator; GCS 3–5 is associated with mortality exceeding 90%, informing early goals-of-care discussions. CT imaging defines trajectory, bihemispheric or transventricular involvement, midline shift, and retained fragment burden, guiding surgical candidacy. Surgical decision-making: Indications for operative intervention include accessible mass lesions, significant midline shift, elevated intracranial pressure, CSF leak, and depressed or comminuted fractures with dural breach. Conservative management is favored in bihemispheric trajectories with GCS ≤ 5 and bilateral fixed pupils, where surgery does not improve outcome. Debridement extent: Contemporary evidence favors limited, hemostasis-focused debridement over aggressive bullet and fragment removal, given comparable infection rates and reduced additional neurological injury from fragment retrieval.

Conclusion: A structured, GCS-stratified algorithm integrating early resuscitation, targeted imaging, and selective surgical intervention optimizes outcomes in penetrating craniocerebral gunshot wounds while avoiding futile aggressive intervention in unsalvageable injuries.

P37 - C1–C2 spinal meningioma in pediatric neurofibromatosis type 2

Ala Eddine Chaabane, Nader Yahyaoui, Mohamed Maher Hadhri, Atef Ben Nsir, Mehdi Darmoul

Neurosurgery Department, Fattouma Bourguiba University hospital, Monastir, Tunisia.

Introduction: Neurofibromatosis type 2 (NF2) is a rare autosomal dominant tumor predisposition syndrome characterized by the development of multiple tumors of the central and peripheral nervous system. Although bilateral vestibular schwannomas are the hallmark of the disease, spinal tumors, including meningiomas, may represent the initial manifestation in pediatric patients.

Case presentation: We report the case of a 9-year-old child diagnosed with neurofibromatosis type 2 who presented with progressively worsening walking difficulties. Neurological examination revealed bilateral lower-limb spasticity and stiffness, consistent with cervical myelopathy. Magnetic resonance imaging (MRI) of the cervical spine demonstrated a well-defined intradural extramedullary mass at the C1–C2 level, causing significant compression of the upper cervical spinal cord.

Results: The patient underwent surgical resection of the lesion. Histopathological examination confirmed the diagnosis of meningioma. The postoperative course was uneventful, with gradual improvement in gait and lower-limb spasticity following rehabilitation.

Conclusion: Although uncommon in children, spinal meningiomas should be considered in the differential diagnosis of progressive myelopathy in patients with NF2. This case illustrates that a high cervical (C1–C2) intradural extramedullary meningioma may be the presenting manifestation of NF2 in the pediatric population. Early MRI evaluation, timely surgical decompression, and histopathological confirmation are essential for optimizing neurological outcomes and preventing permanent deficits.

P38 - Can hounsfield units predict mechanical failure after lumbar fusion? an opportunistic CT-based approach to bone quality assessment

Majdouline Barkache, R. Ben Fredj, A. Affes, A. Hmida, I. Ksira

Department of Neurosurgery, Sahloul University Hospital, Sousse, Tunisia

Background: Mechanical failure following lumbar fusion, including pedicle screw loosening and pseudarthrosis, remains a major concern in spine surgery. Bone quality is a key determinant of construct stability, yet dual-energy X-ray absorptiometry (DEXA) is not routinely available or systematically performed in all patients. Opportunistic assessment of bone quality using Hounsfield Units (HU) on preoperative CT scans has emerged as a potential alternative. This narrative review explores the predictive value of HU measurements for mechanical complications after lumbar fusion.

Methods: A narrative review of the literature was conducted focusing on studies evaluating vertebral Hounsfield Unit values as a surrogate marker of bone quality and their association with postoperative mechanical outcomes after lumbar fusion. Relevant publications addressing screw loosening, implant failure, and pseudarthrosis were analyzed and synthesized to identify consistent clinical trends and proposed cutoff values.

Results: Current evidence suggests a strong association between low vertebral HU values and increased risk of mechanical failure after lumbar fusion. Patients with reduced HU measurements are more likely to develop pedicle screw loosening, implant migration, and non-union. Several studies propose HU thresholds below which the risk of instrumentation failure significantly increases, reflecting poor bone mineral density and compromised trabecular microarchitecture. Opportunistic CT-based assessment demonstrates good correlation with DEXA and provides additional value in surgical planning. However, variability in CT acquisition protocols and HU cutoff definitions limits standardization across studies.

Conclusion: Hounsfield Units derived from routine preoperative CT scans represent a promising, readily available tool for assessing bone quality and predicting mechanical failure after lumbar fusion. Although not yet universally standardized, HU-based evaluation may help identify high-risk patients and guide strategies such as augmented fixation or osteoporosis treatment. Further prospective studies are needed to establish validated cutoff values and integrate HU assessment into routine spine surgery practice.

P39 - Carential myelopathy due to vitamin B12 deficiency: a diagnosis not to neglect

Majdouline Barkache, R. Ben Fredj, H. Kamoun, A. Hmida, I. Ksira

Department of Neurosurgery, Sahloul University Hospital, Sousse, Tunisia

Background: Cobalamin (vitamin B12) deficiency is a well-established but frequently under-recognized cause of progressive myelopathy. Neurological impairment may occur despite the absence of anemia or macrocytosis, which can delay diagnosis. Early recognition is essential, as neurological recovery depends strongly on prompt replacement therapy.

Objective: To describe the clinical, biological, radiological, and outcome profiles of patients with neurological manifestations attributable to vitamin B12 deficiency, with particular emphasis on deficiency-related myelopathy.

Methods: We conducted a retrospective study in the Department of Neurology, Habib Bourguiba University Hospital, Sfax, Tunisia. Patients were included when they presented neurological manifestations suggestive of vitamin B12 deficiency. Patients with an alternative or associated disorder sufficient to explain the neurological presentation were excluded.

Results: Forty-five patients were included, comprising 28 men and 17 women. The mean age at symptom onset was 50.8 years. Initial manifestations were dominated by paresthesias and gait disturbance. Posterior column syndrome was the most frequent clinical pattern, observed in 93.3% of patients, and was associated with pyramidal signs in 27 cases. Cerebellar syndrome, sphincter dysfunction, and polyneuropathy were also identified in some patients. Biologically, anemia was present in 38 patients and macrocytosis in 39. Serum vitamin B12 levels were decreased in most cases. Spinal MRI showed thoracic T2-hyperintense lesions in two patients, while brain MRI was normal in the majority of cases. All patients received vitamin B12 replacement therapy, with clinical and biological improvement in most cases.

Conclusion: Vitamin B12 deficiency should be systematically investigated in any unexplained progressive myelopathic syndrome, especially when posterior column dysfunction, sensory ataxia, or pyramidal signs are present. Because neurological recovery is closely related to time to treatment, early diagnosis and rapid cobalamin supplementation remain decisive in preventing irreversible neurological sequelae.

P40 - Cement gone wrong: prevention and management of extravasation complications after vertebral augmentation

Rachdi Mohamed Amine, Kammoun T, Bouzouita K, Achoura S, Chkili Ridha, Radhouen K.

Neurosurgery Department, Military Hospital of Tunis, Tunis, Tunisia

Background & objectives: Cement extravasation represents the most frequent and potentially devastating complication of vertebroplasty and kyphoplasty, occurring in up to 40% of vertebroplasty procedures. While most extravasation events are clinically silent, intracanalicular, foraminal, and venous migration can produce neurological deficits, pulmonary embolism, and cardiac complications with life-threatening consequences. Systematic prevention strategies and management protocols remain incompletely standardized. This review critically examines cement extravasation mechanisms, prevention strategies, and management options after vertebral augmentation.

Methods: Narrative review of PubMed, Scopus, and Cochrane databases (2005–2024), including prospective cohort studies, complication registries, and technical reports addressing extravasation incidence, risk factors, prevention techniques, and surgical management of symptomatic cement leakage.

Results & discussion: Extravasation patterns: Four principal extravasation pathways are identified: intradiscal, paravertebral soft tissue, epidural-intracanalicular, and venous-systemic. Intradiscal extravasation accelerates adjacent segment degeneration; epidural migration produces acute cord or nerve root compression requiring emergency surgical decompression; venous migration risks pulmonary cement embolism, occasionally fatal. Risk factors: Posterior wall fractures, highly lytic metastatic lesions, aggressive cement injection technique, low cement viscosity, and inadequate fluoroscopic monitoring are consistently identified as independent extravasation risk factors. Prevention strategies: High-viscosity cement formulation, staged low-pressure injection, real-time biplanar fluoroscopy, strict injection cessation upon venous opacification, and balloon kyphoplasty cavity creation collectively reduce clinically significant extravasation rates below 5% in experienced centers. Symptomatic management: Neurological deficits from epidural cement migration require urgent surgical decompression and cement fragment removal. Pulmonary cement embolism management follows standard anticoagulation protocols, with surgical embolectomy reserved for hemodynamically compromising cases.

Conclusion: Cement extravasation is preventable through meticulous technique and rigorous real-time monitoring. Systematic adoption of high-viscosity cement, pressure-controlled injection, and immediate cessation protocols represents the most effective risk-reduction strategy in vertebral augmentation practice.

P41 - Cement or surgery? defining the ideal candidate for vertebral augmentation in osteoporotic compression fractures

Rachdi Mohamed Amine, Hdhili H, Bouzouita K, Achoura S, Chkili Ridha, Radhouen K.

Neurosurgery Department, Military Hospital of Tunis, Tunis, Tunisia

Background & objectives: Osteoporotic vertebral compression fractures affect millions annually, generating chronic pain, progressive kyphosis, and functional dependency. Vertebroplasty and balloon kyphoplasty represent minimally invasive vertebral augmentation techniques offering rapid pain relief and functional restoration. However, patient selection remains inconsistent across centers, and indications continue to be debated following conflicting randomized trial results. This review defines optimal candidacy criteria for vertebral augmentation in osteoporotic compression fractures.

Methods: Narrative review of PubMed, Scopus, and Cochrane databases (2005–2024), including randomized controlled trials, systematic reviews, and society guidelines addressing vertebroplasty and kyphoplasty outcomes, complication profiles, and patient selection criteria.

Results & discussion: Indications: Current evidence supports vertebral augmentation in patients with acute or subacute fractures (under 6–8 weeks), persistent pain unresponsive to conservative management exceeding 4–6 weeks, confirmed fracture edema on MRI (STIR hyperintensity), and significant functional impairment. Chronic fractures with absent bone marrow edema demonstrate consistently inferior pain response. Vertebroplasty versus kyphoplasty: Both techniques achieve equivalent pain relief. Kyphoplasty demonstrates superior height restoration and reduced cement extravasation rates through cavity creation prior to injection, favoring its use in fractures with significant height loss or kyphotic deformity exceeding 15–20 degrees. Cement extravasation: Occurring in 5–40% of cases depending on technique and fracture morphology, symptomatic extravasation into the spinal canal or venous system represents the principal complication, minimized through viscous cement formulations, pedicle approach, and real-time fluoroscopic monitoring. Controversial indications: Malignant vertebral fractures, multilevel augmentation, and fractures with posterior wall disruption require individualized assessment given higher complication risk and variable pain response.

Conclusion: Vertebral augmentation delivers meaningful pain relief and functional recovery in appropriately selected osteoporotic fracture patients. MRI-confirmed bone edema, subacute fracture timing, and failed conservative management constitute the evidence-based selection triad guiding optimal outcomes.

P42 - Cerebral and osteolytic skull metastasis 19 years after triple-positive breast carcinoma: a rare case report

Oumaima Rmida, F.Kolsi, B.Kammoun, S.Ben Fredj, Y.Feki, Bmz .Boudawara

Neurosurgery Department of Habib Bourguiba University Hospital Sfax.

Introduction: Bone metastases from breast cancer are common in advanced disease, particularly in hormone receptor–positive and HER2-positive subtypes. However, metastatic recurrence involving both the skull and brain after a disease-free interval exceeding 15 years is exceedingly rare. We report an unusual case of combined cerebral and osteolytic skull metastasis occurring 19 years after initial treatment of a triple-positive invasive ductal carcinoma

Methods: We present the case of a 61-year-old woman diagnosed in 2006 with right breast invasive ductal carcinoma, SBR grade II, ER+, PR+, HER2+, with axillary lymph node involvement (4/16 positive). She underwent breast-conserving surgery followed by adjuvant chemotherapy and radiotherapy, achieving complete remission. In 2025, she presented with persistent headaches and cervical discomfort. Brain imaging revealed a left parietal intra-axial lesion associated with an osteolytic skull defect suggestive of secondary metastatic involvement. Mammography showed scattered micro- and macrocalcifications with a contralateral ACR3 nodule. Laboratory findings indicated a metabolic inflammatory background, including hypertension, dyslipidemia, and elevated HbA1c.

Results: A diagnosis of late metastatic recurrence of triple-positive breast carcinoma with cerebral and skull involvement was established. The patient received palliative external beam radiotherapy (20 Gy in 5 fractions). Clinical evolution showed partial improvement in headaches and neurological stabilization.

Conclusions: This case highlights an exceptionally rare ultra-late metastatic recurrence of triple-positive breast cancer after 19 years of remission, involving both brain and skull. Hormone receptor positivity may explain prolonged tumor dormancy, while HER2 positivity may contribute to cerebral tropism. This observation underscores the need for long-term vigilance in high-risk breast cancer patients and supports the role of palliative radiotherapy in symptomatic skeletal metastases.

P43 - Cerebral arteriovenous malformations: clinical presentation, prognostic factors, and therapeutic management

Imen Dammak, Salma Sakka, Becha Mariem, Sawsan Daoud, Imen Damak, Khadija Moalla, Nadia Bouatour, Fatma Kolsi, Mariem Damak

Department of neurology and department of neurosurgery, Hbib Bourghuiba University Hospital,Sfax,Tunisia

Background: Cerebral arteriovenous malformations (AVMs) are uncommon congenital neurovascular lesions characterized by abnormal direct arteriovenous shunting. Their clinical relevance is driven by the risk of intracranial hemorrhage, epilepsy, and permanent neurological disability, particularly in young adults.

Objective: To describe the clinical presentation, prognostic features, radiological findings, and therapeutic management of patients diagnosed with cerebral AVMs.

Methods: We conducted a retrospective case-series study including patients followed for cerebral AVMs at the Department of Neurology, Habib Bourguiba University Hospital, Sfax, Tunisia. All patients underwent complete neurological examination and cerebral vascular imaging using computed tomography angiography and/or magnetic resonance angiography. Conventional cerebral angiography was performed when clinically indicated.

Results: Twenty patients were included, with a mean age of 35 years. The most frequent presenting manifestation was epileptic seizure, observed in 10 patients (50%). Motor deficit was reported in 7 patients (35%), and acute headache in 3 patients (15%). Neuroimaging identified unruptured AVMs in 8 patients (40%). Hemorrhagic complications included subarachnoid hemorrhage in 3 patients (15%) and intracerebral hemorrhage in 8 patients (40%). Features associated with poorer prognosis included young age, deep AVM location, deep venous drainage, small AVM size, hematoma, and previous rupture. Superficial AVM location was considered a favorable prognostic feature. Management was individualized according to clinical presentation and angioarchitectural characteristics. Symptomatic treatment included seizure control, headache management, and acute care for hemorrhagic events. Five patients (25%) underwent endovascular embolization. One death was recorded.

Conclusion: Cerebral AVMs are rare but potentially severe neurovascular lesions because of their spontaneous hemorrhagic risk. Prognosis depends on clinical and angioarchitectural factors, particularly rupture status, location, venous drainage, and lesion size. Accurate assessment of rupture risk and expected therapeutic benefit is essential to guide management. A multidisciplinary strategy involving neurologists, interventional neuroradiologists, neurosurgeons, and radiosurgery specialists remains central to individualized care.

P44 - Cerebral astroblastoma - a rare and challenging tumor: a case report and review of the literature

Egueh Fahye Mohamed, Nessib N., Slimane A., Sliti F., Bouhoula A, Naceur M., Ghedira K., Bouali S, Abderahhmen K, Ben Said I, Kallel J.

Department of Neurosurgery, National Institute Mongi Ben Hmida of Neurology, Tunis, Tunisia

Introduction: Astroblastoma is a rare and distinct type of aggressive glial tumor, occurring preferentially in children and young adults, with a marked female predominance. In the 2021 WHO Classification of Central Nervous System Tumors, this entity was redefined as “astroblastoma, MN1-altered” based on its characteristic molecular profile. Owing to its rarity, its biological behavior, optimal management, and prognosis remain incompletely understood. We report a pediatric case of astroblastoma arising within the left Rolandic region mimicking an extra-axial neoplasm, highlighting the therapeutic challenges associated with lesions involving eloquent cortex.

Case report: An 8 years old boy with no significant medical history presented with a 3 month history of focal motor seizures involving the right lower limb, associated with a right hemiparesis. Brain MRI revealed a well-circumscribed extra axial parasagittal lesion located in the left Rolandic region, isointense on T1-weighted imaging and exhibiting homogeneous contrast enhancement following gadolinium administration, without evidence of peritumoral edema on T2-weighted or FLAIR sequences. Surgical resection was undertaken; however, only a subtotal resection could be achieved because of significant difficult hemostasis. Histopathological analysis confirmed grade 2 astroblastoma (GFAP+, EMA+, Ki-67: 2%). Follow up MRI performed two months later demonstrated marked progression of the residual tumor, prompting consideration of repeat surgery with the goal of achieving gross total resection.

Discussion: Astroblastoma typically presents as a well-circumscribed, superficial lesion, often associated with marked contrast enhancement and with moderate or absent perilesional edema in 96% of cases. Our observation illustrates several of these typical radiological features. Due to its rarity, there are no consensus therapeutic guidelines. Gross total resection, the reference treatment, and strongly determines prognosis. In high-grade forms, adjuvant radiotherapy appears to provide a benefit, whereas the role of chemotherapy remains more uncertain and debated.

Conclusion: Astroblastoma should be considered in the differential diagnosis of a well-defined cerebral lesion in children, especially when peritumoral edema is absent. Tumors arising within eloquent brain regions pose a significant neurosurgical challenge, often limiting the extent of resection. This case emphasizes the pivotal role of gross total resection in achieving durable local control and highlights the need for close radiological surveillance following subtotal resection because of the risk of early tumor progression.

P45 - Cerebral hydatid cyst in a child: a case report and literature review

Bendib Sabrina, Benbetiche, Mechiche, Boussaha, Hallaci

Neurosurgery Department, CHU Saadna Abdelnour, Setif, Algeria

Background: Cerebral hydatidosis is a rare anthropozoonosis caused by the larval form of Echinococcus granulosus. It is endemic in many traditional livestock-raising countries. Intracranial localization is exceptional, accounting for only 2% of intracranial space-occupying lesions in these countries. It predominantly affects children, with a mean age of 15 years and a male predominance. Clinical signs depend on cyst size and location, with slow and polymorphous onset, dominated by intracranial hypertension syndrome. Diagnosis relies on brain imaging, and management is both medical and surgical.

Methods: We report the case of an 11-year-old child, with no significant past medical history, who presented to the emergency department with moderate holocranial headaches and recurrent vomiting. The patient was conscious (Glasgow Coma Scale 15/15), apyretic, with no other neurological deficits. Brain CT revealed a large multilocular intra-parenchymal cystic mass in the left temporo-parieto-occipital region, with mild perilesional edema and subfalcine herniation, suggestive of a hydatid cyst. The patient underwent surgical excision using hypertonic saline hydrodissection with macroscopic total resection.

Results: Immediate postoperative outcome was marked by right hemiparesis. One-year follow-up brain MRI showed recurrence with cerebroventricular extension. The patient died before any further surgical intervention could be performed.

Conclusions: Cerebral hydatidosis is a rare but increasingly frequent parasitic disease in Algeria. CT and MRI are the main diagnostic tools, with MRI being superior for detecting multiple or ventricular cysts. Serology is often non-specific and frequently negative. Surgery remains the gold-standard treatment, with Arana-Iniguez hydrodissection being the most widely used technique. Prognosis is generally good in cases of early diagnosis and solitary lesions. However, multiple cerebral localizations, as in our case, pose serious therapeutic challenges and carry a high risk of recurrence and mortality.

P46 - Cerebral metastases from primary esophageal carcinoma: two case reports and a review of diagnostic and therapeutic challenges

Bahri Farah, M.A.Kharrat, S.Ben Yakoub, M. Bounemra, A.Hermassi, S.Ben Zekri, A.Bedioui, M.Rkhami, M.Badri, K.Bahri, I.Zammel

Department of Neurosurgery, Ben Arous Trauma Center, Tunisia

Background: Brain metastases from primary esophageal carcinoma are exceedingly uncommon, with a reported incidence of approximately 1–3%, and are typically associated with advanced-stage disease and poor survival. Improvements in systemic therapies and prolonged patient survival have led to an increasing recognition of this rare metastatic pattern. However, owing to the limited number of reported cases, evidence-based management remains poorly established. We report two cases that illustrate the heterogeneous clinical presentation and discuss current therapeutic considerations.

Methods: We retrospectively reviewed two patients managed at our institution for cerebral metastases originating from histologically confirmed esophageal carcinoma. Clinical characteristics, radiological findings, surgical strategy, histopathological features, adjuvant oncological treatment, and postoperative outcomes were analyzed.

Results: Both patients presented with symptomatic intracranial lesions causing focal neurological deficits. Neuroimaging demonstrated solitary cerebral masses requiring surgical intervention. In one patient, the intracranial lesion constituted the inaugural manifestation of the underlying esophageal malignancy, whereas in the second, cerebral dissemination developed during the evolution of known metastatic disease. Gross total resection was achieved in both cases, allowing histopathological confirmation of metastatic esophageal carcinoma and prompt neurological improvement. Following surgery, both patients underwent multidisciplinary evaluation and received individualized adjuvant treatment combining radiotherapy and systemic therapy according to histological subtype and molecular profile.

Conclusions: Cerebral metastases from esophageal carcinoma represent an exceptionally rare clinical entity that poses significant diagnostic and therapeutic challenges. Early recognition of neurological symptoms, meticulous neuroimaging assessment, and careful patient selection for surgical resection are essential to optimize functional outcomes and facilitate comprehensive oncological management. These cases underscore the value of a multidisciplinary approach and contribute to the growing body of literature supporting surgery as an important component of treatment in selected patients with limited intracranial disease.

P47 - Cerebral venous sinus thrombosis after traumatic brain injury: management dilemma between anticoagulation and conservative treatment.

Emna Elouni, Emna Mzoughi, Khalil Ghedira, Roua Latrach, Sofiene Bouali, Haifa Mechergui, Jalel Kallel

Neurosurgery Departement, National Institute of Neurology, Tunis, Tunisia

Background: Cerebral venous sinus thrombosis (CVST) is an increasingly recognized complication of traumatic brain injury (TBI). Its optimal management remains controversial, particularly regarding the initiation of anticoagulation (AC) in the presence of concomitant traumatic intracranial lesions.

Methods: We present two cases of CVST following TBI: a pediatric patient and an adult patient, both diagnosed using cerebral venography after moderate head trauma. Clinical presentation, imaging findings, therapeutic strategy (anticoagulation versus observation), and outcomes were analyzed. A targeted literature review was performed focusing on indications, safety, and outcomes of anticoagulation in post-traumatic CVST.

Results: Both patients developed post-traumatic CVST involving major dural venous sinuses identified on CT venography. The pediatric case was managed conservatively, while the adult patient received therapeutic anticoagulation after multidisciplinary discussion. Clinical and radiological evolution differed between the two cases, with stable neurological outcome in both patients. Literature review shows no standardized guidelines, with reported practices ranging from early full-dose anticoagulation to delayed or purely observational strategies. Most observational studies suggest that anticoagulation may reduce thrombus propagation, with an acceptable risk of hemorrhagic complications in carefully selected patients.

Conclusions: Post-traumatic CVST presents a therapeutic dilemma between preventing thrombus extension and avoiding hemorrhagic worsening. Current evidence remains based on retrospective series, with no consensus on anticoagulation timing or indications. Individualized management based on hemorrhagic burden, venous occlusion severity, and clinical evolution is essential. Prospective studies are needed to define standardized treatment protocols.

P48 - Cervical spinal epidural hematoma: two distinct presentations and management strategies

Roua Latrach, E. Elouni, F. Sliti, N. Nessib, A. Slimane, K. Ghedira, K. Abderrahmen, S. Bouali, I. Ben Said, J. Kallel

Department of neurosurgery , National Institute of Neurology, Tunisia.

Spinal epidural hematoma (SEH) is a rare but potentially devastating condition that requires prompt diagnosis and management. Delayed recognition may result in permanent neurological deficits, significant morbidity, and a substantial impact on patients' quality of life and functional independence. Several etiologies have been described, including trauma, vascular malformations, iatrogenic causes, and spontaneous occurrence. We report two cases of spinal epidural hematoma. The first patient was a 49-year-old man with no significant medical history who presented with the sudden onset of severe cervical pain associated with paresthesia and right-sided hemiparesis. An initial cerebral computed tomography scan was performed but revealed no abnormalities. Further investigation with spinal magnetic resonance imaging demonstrated a posterior cervical epidural hematoma extending from C6 to T1. A conservative management strategy was adopted after discussion with the patient. During hospitalization, he experienced progressive neurological recovery. Spinal angiography was subsequently performed and showed no evidence of an underlying vascular malformation. The second patient was a 46-year-old man receiving vitamin K antagonist therapy following mechanical heart valve replacement. He presented with acute quadriparesis that rapidly progressed to complete quadriplegia. The patient denied any history of trauma but reported an unusual neck movement during sleep shortly before symptom onset. Spinal MRI revealed a posterior cervical epidural hematoma extending from C3 to C7. Laboratory investigations showed therapeutic anticoagulation levels without evidence of vitamin K antagonist overdose. Following correction of coagulation parameters, the patient underwent urgent surgical decompression. Postoperatively, he demonstrated neurological improvement; however, prolonged rehabilitation was required to achieve functional recovery and regain independent ambulation. Through these two cases, we highlight the heterogeneous clinical presentation and management of spinal epidural hematomas. While conservative treatment may be considered in carefully selected patients with mild deficits and early neurological improvement, urgent surgical decompression remains the standard of care for patients presenting with severe or progressive neurological deterioration. A high index of suspicion, thorough neurological assessment, and timely spinal imaging are essential to establish the diagnosis and optimize functional outcomes.

P49 - Cervical spine trauma in the elderly: epidemiological and clinical features and vulnerability characteristics

Rami Ben Mhenni, Mohamed Amine Hmida[2], Aymen Hanafi[1], Sadok Chtai[1], Mourad Mtaoumi[1], Mohamed Ali Khalifa[1], Karim Bouattour[1]

[1] Department of Orthopaedic Surgery and Traumatology, Sahloul University Hospital, Sousse, Tunisia.
[2] Department of Neurosurgery, Sahloul University Hospital, Sousse, Tunisia.

Introduction: The incidence of cervical spine trauma is increasing among older adults as a result of population ageing, osteoporosis, and pre-existing cervical degeneration. Despite the growing burden of these injuries, data from North Africa remain scarce. This study aimed to describe the epidemiological profile, clinical presentation, and vulnerability characteristics of elderly patients sustaining cervical spine trauma.

Materials and methods: A retrospective descriptive study was conducted at a tertiary trauma centre between January 2014 and December 2024. Patients aged 65 years or older who were managed for cervical spine fractures were included. Pathological fractures, old fractures, and incomplete medical records were excluded. Demographic, clinical, and radiological data were collected using a standardized form, including age, sex, comorbidities, injury mechanism, neurological status according to the Frankel classification, associated injuries, and cervical degenerative changes.

Results: Thirty patients were included, with a mean age of 69 ± 4.46 years (range, 65–82 years); 70% were male. Patients aged 65–74 years accounted for 83.3% of the cohort, whereas those aged ≥75 years represented 16.7%. At least one comorbidity was present in 83.3% of patients, most commonly hypertension (33.3%) and cervical osteoarthritis (23.3%). Low-energy domestic falls were the leading injury mechanism (56.7%), followed by road traffic accidents (33.3%). Cervical pain was observed in all patients, while torticollis was present in 16.7%. Associated injuries included craniofacial trauma in 33.3% of cases, peripheral musculoskeletal injuries in 30%, and thoracic trauma in 13.3%. Neurological examination was normal (Frankel E) in 80% of patients. Degenerative cervical changes were identified in 80% of cases.

Conclusion: Cervical spine trauma in elderly patients predominantly results from low-energy domestic falls and occurs in a population characterized by a high burden of comorbidities and pre-existing cervical degeneration. Careful cervical assessment is warranted even after apparently minor trauma, particularly in the presence of associated craniofacial injuries.

P50 - Choosing the right screw: fenestrated versus solid pedicle screws in lumbar spine surgery

Mohamed Amine Rachdi, Hdhili H, Bouzouita K, Achoura S, Chkili Ridha, Radhouen K.

Neurosurgery Department, Military Hospital of Tunis, Tunis, Tunisia

Background & objectives: Pedicle screw fixation failure remains a significant concern in lumbar fusion surgery, particularly in osteoporotic or revision settings, where screw loosening and pull-out compromise construct stability and clinical outcomes. Fenestrated cannulated screws, designed to allow cement augmentation, have emerged as an alternative to conventional solid screws in compromised bone quality. However, indications, biomechanical advantages, and complication profiles compared to solid screws remain incompletely standardized. This review critically examines current evidence comparing fenestrated and solid pedicle screws to guide screw selection in lumbar spine surgery.

Methods: Narrative review of PubMed, Scopus, and Cochrane databases (2010–2024), including biomechanical cadaveric studies, clinical cohort comparisons, and complication analyses evaluating fenestrated versus solid pedicle screw performance in lumbar fusion.

Results & discussion: Biomechanical performance: Cement-augmented fenestrated screws demonstrate significantly higher pull-out strength and insertional torque compared to solid screws in osteoporotic bone models, with reported increases of 50–170% depending on cement volume and distribution pattern. Clinical indications: Fenestrated screws are primarily indicated in osteoporotic spine surgery, long-segment deformity constructs, revision surgery with compromised pedicle bone stock, and adjacent segment disease at fusion endpoints, where mechanical failure risk is highest. Complications: Cement extravasation, including epidural and vascular leakage, represents the principal risk specific to fenestrated screws, occurring in 5–15% of augmented levels, though clinically symptomatic events remain rare with controlled injection technique and proper screw positioning. Solid screws — when sufficient: In patients with adequate bone mineral density and standard short-segment fusion, solid screws remain the standard of care, offering equivalent fixation without augmentation-related risks or added procedural complexity and cost.

Conclusion: Fenestrated pedicle screws offer a valuable biomechanical advantage in osteoporotic and high-risk lumbar fusion constructs, while solid screws remain appropriate and sufficient in patients with preserved bone quality. Screw selection should be individualized based on bone density assessment rather than applied uniformly.

P51 - Chronic subdural hematoma in elderly patients : clinical features, surgical management, and outcomes : a single-center experience

Mohamed Znazen, M. Taallah, A. Hachicha, I. Ketata,

Department of Neurosurgery, University Hospital of Gabès, Tunisia

Background: Chronic subdural hematoma (CSDH) is one of the most common neurosurgical conditions in the elderly population. Its increasing incidence is largely attributed to population aging, cerebral atrophy, and the widespread use of antithrombotic medications. Clinical presentation is often insidious and nonspecific, potentially leading to delayed diagnosis. This study aimed to analyze the epidemiological, clinical, radiological, therapeutic, and outcome characteristics of elderly patients treated for CSDH.

Methods: We conducted a retrospective descriptive study in the Department of Neurosurgery at Gabes University Hospital between 2023 and 2025. A total of 69 patients aged 70 years or older who were treated for chronic subdural hematoma were included. Demographic characteristics, risk factors, clinical presentation, computed tomography findings, treatment modalities, and clinical outcomes were analyzed

Results: The mean age was 80.5 years (range: 70–105 years), with the highest prevalence observed in patients aged 80–90 years (45%). There was a marked male predominance (89%). Antiplatelet and/or anticoagulant therapy was identified in 45% of patients. Motor deficit was the most frequent presenting symptom, occurring in 83% of cases, while impaired consciousness, including confusion or somnolence, was observed in 62%. Seizures were reported in 5% of patients. Computed tomography (CT) demonstrated a hypodense chronic subdural collection in 85% of cases, whereas mixed-density or isodense-hypodense lesions were observed in 15%. Bilateral hematomas were identified in four patients. All patients underwent surgical treatment consisting of burr-hole evacuation with closed-system drainage. Favorable neurological recovery was achieved in 97% of cases. Recurrence occurred in two patients, both requiring repeat surgery. Minor residual neurological deficits or postoperative epilepsy were observed in 11.5% of patients.

Conclusions: CSDH is a common and potentially disabling condition in elderly patients. Motor deficits and altered consciousness are the most frequent presenting manifestations. CT imaging remains essential for diagnosis, while burr-hole evacuation with drainage offers excellent clinical outcomes. Close postoperative follow-up is warranted to detect recurrence and optimize long-term neurological recovery.

P52 - Chronic subdural hematoma revealing acute leukemia : report of two cases

Dahamou Mohamed, Elfarissi Mohammed Alamine, Khoulali Mohamed, Khay Hamid, Kada Amine, El Kartit Fatima, Aniya Loubna, Lamrabet Khaoula

Neurosurgery Department, Mohammed VI University Hospital, Oujda, Morocco

Chronic subdural hematoma (CSDH) is a common neurosurgical condition in elderly patients; however, its association with acute leukemia remains rare. Hematological malignancies may predispose to intracranial hemorrhage through thrombocytopenia and coagulation disorders. We report two cases of chronic subdural hematoma in patients aged 57 and 68 years, respectively, which led to the diagnosis of acute leukemia. Both patients presented with neurological symptoms. Brain computed tomography revealed chronic subdural hematoma, while biological investigations demonstrated severe hematological abnormalities suggestive of acute leukemia. The patients received combined neurosurgical and hematological management. These cases emphasize the importance of investigating underlying hematological disorders in spontaneous or atypical chronic subdural hematomas, particularly in the absence of head trauma.

P53 - Chronic temporal extradural hematoma of atypical origin: a case report

Imen Dammak, Ines Cherif[1], Yassine Chaker[1], Fares Ferjani[1], Jihane Ketata[2], Hichem Ammar[1]

[1] Department of Neurosurgery, Sfax Military University Hospital, Tunisia.
[2] Department of Neurology, Sfax Military University Hospital, Tunisia.

Introduction: Extradural hematoma is a neurosurgical emergency that usually follows an acute course after head trauma. Chronic forms are rare, particularly in young patients. Their clinical course may be atypical, especially when they occur in an initially conscious and minimally symptomatic patient.

Case report: We report the case of a 17-year-old patient with no significant past medical history, who sustained head trauma following a road traffic accident. On admission, the patient was conscious, with no impairment of consciousness and no signs of intracranial hypertension. Initial brain imaging revealed a non-compressive acute left temporal extradural hematoma. Following the secondary onset of headache, follow-up imaging was performed and showed chronic evolution of the extradural hematoma, which had become compressive. Surgical evacuation through a craniotomy was indicated. Intraoperatively, a hemorrhagic dural lesion in the basal temporal region was identified, requiring hemostasis using coagulation and Surgicel. Postoperative cerebral CT angiography revealed a dural fistula supplied by a branch of the Sylvian artery, with drainage into the vein of Labbé and the left sigmoid sinus. After six months of postoperative follow-up, and before any embolization was performed, control imaging showed spontaneous disappearance of the dural fistula, associated with complete regression of the hematoma.

Conclusion: Post-traumatic chronic extradural hematoma is a rare entity that requires careful clinical and radiological monitoring, even in an initially conscious and asymptomatic patient. Vascular imaging should be considered in cases of unusual evolution in order to identify an associated vascular lesion. This case also illustrates the rare possibility of spontaneous regression of a post-traumatic dural fistula.

P54 - Clinical decompensation of spinal aneurysmal bone cysts following minor trauma: a report of two cases

Roua Latrach, E. Elouni, F. Sliti, N. Nessib, M. Naceur, A. Slimane, K. Ghedira, K. Abderrahmen, S. Bouali, I. Ben Said, J. Kallel

Department of Neurosurgery, National Institute of Neurology, Tunis, Tunisia

Spinal aneurysmal bone cysts (ABCs) are rare, benign, yet locally aggressive osseous lesions that predominantly affect adolescents, and young adults. Clinical presentation is variable, ranging from asymptomatic lesions discovered incidentally to progressive back pain, spinal deformity, radiculopathy, or myelopathy. Acute neurological deterioration following minor trauma is an uncommon but potentially devastating presentation that requires prompt diagnosis and urgent surgical management. We report the cases of two male patients aged 12 and 18 years, respectively, with no significant medical history, who presented with acute lower-limb weakness following minor trauma. Neither patient reported preceding back pain, gait impairment, or other neurological symptoms. Neurological examination revealed motor deficits affecting the lower extremities, prompting further investigation. Magnetic resonance imaging of the spine demonstrated thoracic aneurysmal bone cysts associated with significant spinal cord compression and mass effect. Both patients underwent urgent surgical decompression and tumor resection. Postoperatively, both patients showed progressive neurological recovery, with improvement in motor function and resolution of symptoms during follow-up. In young patients presenting with sudden paraparesis or paraplegia after minor trauma, an underlying spinal lesion such as an aneurysmal bone cyst should be considered in the differential diagnosis. Prompt imaging and urgent surgical intervention are crucial to maximize neurological recovery and achieve favorable functional outcomes.

P55 - Clinical, radiological and histological features of cerebral lymphomas: a 15-year monocentric series of 40 cases

Firas Gahbiche, F. Kolsi[1], Kh. S. Moalla[2], W. Raddaoui[1], K. Ayadi[1], B. Essid[1], S. Abdelmoula[1], S. Chaari[1], M. Taallah[1], M. Borni[1], B. Kammoun[1], Boudawara MZ[1].

[1].Neurosurgery department , Habib Bourguiba Hopsital , sfax , Tunisia

[2].Neurology department , Habib Bourguiba Hopsital , sfax , Tunisia

Background: Cerebral lymphoma (CL) is a rare intracranial tumor arising from lymphocytic proliferation within the central nervous system (CNS), either as a primary tumor (PCNSL) or secondary to systemic disease. Its incidence is rising in both immunocompromised and immunocompetent populations. Despite therapeutic advances, cerebral lymphoma remains a diagnostic challenge due to its highly polymorphic clinical and radiological presentation, which frequently mimics other expansive intracranial processes and causes significant diagnostic delay.

Methods: A retrospective descriptive monocentric study was conducted at the Neurosurgery Department of Habib Bourguiba University Hospital, Sfax, Tunisia, over a 15-year period (January 2009 – December 2023). All patients with histologically confirmed cerebral lymphoma and available multimodal brain MRI were included. Statistical significance was set at $p < 0.05$.

Results: Forty patients were included, with a mean annual incidence of 3 cases per year. The male-to-female ratio was 2.07, and the median age was 49 years. The majority of patients (77.5%) consulted within the first month following symptom onset. Immunocompetent patients accounted for 77.5% of the series. Clinically, the presentation was non-specific, dominated by intracranial hypertension syndrome and motor deficits. The Karnofsky Performance Score was above 70 in 87.5% of cases. Brain MRI showed homogeneous and intense gadolinium enhancement in 68.4%, restricted diffusion in 94.4% of cases where DWI was performed, and a low rCBV on perfusion sequences (87.5%). The preoperative diagnosis of cerebral lymphoma was suspected in only 24 cases (60%). Histologically, diffuse large B-cell lymphoma (DLBCL) was the predominant subtype. Early postoperative mortality was 17.5%, and tumor recurrence occurred in 10% of cases.

Discussion: These findings confirm the diagnostic complexity of cerebral lymphoma, whose polymorphic clinico-radiological profile frequently leads to misdiagnosis. MRI multimodal sequences — particularly restricted diffusion and low perfusion — constitute the most discriminating imaging features. The predominance of DLBCL and high CD20 expression carry direct therapeutic implications, given the efficacy of anti-CD20-based regimens combined with high-dose methotrexate.

Conclusion: This series highlights the clinico-radiological and histological heterogeneity of cerebral lymphomas in a Tunisian cohort. A high index of suspicion, early multimodal MRI, and systematic histological confirmation are essential to reduce diagnostic delay and optimize therapeutic management.

P56 - Clinico-biological profile and surgical outcomes of non-functioning pituitary adenomas: a multicenter retrospective study

Emna Mzoughi, Amara S, Gallaoui S, Trifa A, Darmoul M, Zammel I, Kallel J

Department of Neurosurgery, Hospital of Fattouma Bourguiba, Monastir , Tunisia .
Department of Neurosurgery, Burns and Trauma Center, Ben Arous , Tunisia.
Department of neurosurgery , National Institute of Neurology, Tunisia.

Background: Non-functioning pituitary adenomas are benign tumors of the anterior pituitary gland characterized by the absence of clinical hormonal hypersecretion. They are often diagnosed at a macroadenoma stage due to mass effect on adjacent structures, particularly the optic pathways, or following progressive hypopituitarism. Surgery remains the cornerstone of management, especially in symptomatic patients.

Methods: We conducted a retrospective multicenter study including 95 patients operated on for non-functioning pituitary adenomas between January 2018 and December 2023 in three neurosurgical departments. Epidemiological, clinical, ophthalmological, hormonal, radiological, surgical, pathological, and postoperative outcome data were analyzed.

Results: The median age at diagnosis was 52.12 years, with a slight female predominance. The most common mode of presentation was pituitary tumor syndrome, mainly including headaches and visual disturbances. Visual symptoms were present in the majority of patients, with decreased visual acuity as the most frequent manifestation. Partial anterior pituitary insufficiency was found in more than half of the cohort, mainly involving the gonadotropic and thyrotropic axes. Imaging showed macroadenomas in all patients, with frequent suprasellar extension and chiasmal involvement. Surgery was performed in all cases, predominantly through a transsphenoidal approach, including both endoscopic and microscopic techniques. Histopathological examination confirmed pituitary adenoma without malignant features. Postoperative follow-up showed clinical and visual improvement in a substantial proportion of patients, although complications such as diabetes insipidus, corticotropic insufficiency, cerebrospinal fluid leak, and meningitis were observed.

Conclusion: Non-functioning pituitary adenomas are frequently diagnosed at an advanced stage due to compressive symptoms, particularly visual impairment. Transsphenoidal surgery remains the main therapeutic approach, aiming to decompress the optic pathways, preserve pituitary function, and reduce tumor burden. Early diagnosis, careful preoperative hormonal evaluation, and multidisciplinary postoperative follow-up are essential to improve functional outcomes and reduce morbidity.

P57 - Clinico-radiological assessment and therapeutic management of intracranial suppurations: bicentric series of 43 cases with literature review

Mohamed Znazen, A. Hachicha, M. Taallah, H. Belmabrouk,
Department of Neurosurgery, University Hospital of Gabès, Tunisia

Background: Intracranial suppurations (ICSs) are purulent collections of infectious origin. They have been known since antiquity and they represent a neurosurgical emergency since they are life-threatening in the absence of adequate treatment. Although rare, ICS is still a major health problem due to its morbidity and mortality. Many therapeutic attitudes have been described. Management has not really been the subject of consensus.

Methods: Our retrospective, descriptive study including 43 cases of ICSs treated in the Neurosurgery department of the UHC Habib Bourguiba and Traumatology and Major Burns Center of Ben Arous-Tunisia, over a period of 7 years from 2012 to 2018. All epidemiological, etiological, clinical, radiological, biological, therapeutic and evolutionary parameters were studied.

Results: The mean patients'age was 32.35 years with a sex ratio of 4.37. Locoregional infections accounted for 60.46% of aetiologies. Clinical signs found were infectious syndrome in 79.07% and intracranial hypertension in 62.70%. Neuroimaging made diagnosis in 30 cases of abscess and 13 cases of empyema. Predilection site was supratentorial in 90% of abscess and in 92.30% of empyema. Streptococci were isolated in 75% of abscess and in 4 cases of empyema. All patients received broad-spectrum antibiotics. Abscess aspiration was performed in 20 cases and excision in 17 cases. Evacuation of empyema by trepanation was performed in 7 patients and through craniotomy in 7 cases. Outcomes were favorable in 23 cases of abscess and 11 cases of empyema.

Conclusions: ICSs are a topical pathology in various countries where management is multidisciplinary. Outcomes are favorable in more than 80%, improved by early treatment. Clinico-radiological monitoring during follow-up remain essential.

P58 - Clinicoradiological features and therapeutic management of operated convexity meningiomas: a single-center retrospective study

Mohamed Znazen, A. Hachicha, M. Taallah, H. Belmabrouk,

Department of Neurosurgery, University Hospital of Gabès, Tunisia

Background: Meningiomas are the most common primary intracranial tumors in adults, accounting for approximately one-third of all central nervous system neoplasms. Although most are benign and slow-growing, their clinical presentation and prognosis vary according to tumor location, size, histological subtype, and extent of surgical resection. This study aimed to analyze the clinicoradiological characteristics, therapeutic management, and histopathological outcomes of patients operated on for convexity meningiomas in a neurosurgical department.

Methods: We conducted a retrospective descriptive study of 15 patients who underwent surgical treatment for convexity meningioma between 2023 and 2025 at the Neurosurgery Department of Gabès University Hospital. Demographic data, clinical presentation, radiological findings, surgical management, histopathological results, and postoperative treatment were analyzed.

Results: The mean age of the patients was 56.1 years, with a female predominance (male-to-female ratio: 0.66). Seizures were the most common presenting symptom, occurring in 73% of cases, followed by signs of intracranial hypertension in 34%. Motor deficits were observed in 34% of patients, while frontal lobe syndrome was present in 20%. All patients were fully conscious at admission. Magnetic resonance imaging revealed right frontal convexity meningiomas in 60% of cases, right frontotemporal lesions in 14%, and left frontal lesions in 26%. Contrast enhancement was homogeneous in 12 patients and heterogeneous in 3. Peritumoral edema was extensive in 10 cases, moderate in 3, and absent in 2. All patients underwent complete surgical resection with excision of the dural attachment. Tumor-infiltrated bone was removed in one patient, followed by cranioplasty. Histopathological examination demonstrated WHO grade I meningioma in 12 cases, including 10 meningothelial, 1 secretory, and 1 fibroblastic subtype. Three patients (20%) had atypical WHO grade II meningiomas and subsequently received adjuvant radiotherapy. Antiepileptic treatment was continued postoperatively in 73% of patients.

Conclusions: Convexity meningiomas predominantly affect middle-aged women and commonly present with seizures. Surgical resection remains the cornerstone of treatment and provides favorable outcomes in most cases. Histopathological evaluation is essential for grading and guiding adjuvant therapy, particularly in atypical meningiomas. Multidisciplinary management contributes to optimizing postoperative outcomes and reducing the risk of recurrence.

P59 - Cluster headache associated with trigeminal neurovascular conflict

Imen Dammak[1], Jihene Ketata[1], Ines Cherif[2], Hichem Ammar[2]

[1] Department of Neurology, Sfax Military University Hospital, Tunisia

[2] Department of Neurosurgery, Sfax Military University Hospital, Tunisia

Introduction: Cluster headache is a rare primary headache disorder. Some atypical forms may pose diagnostic challenges, particularly when attacks alternate sides or are associated with structural abnormalities.

Case report: We report the case of a 47-year-old man with no significant medical history, who was a smoker and an occasional alcohol consumer, presenting with chronic headaches evolving over six years. The pain was initially left hemicranial and later side-shifting, predominantly orbital, radiating to the jaws, extremely intense, and lasting 15 to 30 minutes. The frequency increased from a few attacks per month to several attacks per day. The attacks were associated with lacrimation, nasal obstruction, photophobia, phonophobia, nausea, agitation, and significant psychosocial impact. Neurological examination was normal. Brain MRI revealed neurovascular conflict in contact with the left trigeminal nerve, with no other abnormalities. Several diagnoses had initially been considered, including migraine and trigeminal neuralgia, and multiple treatments were tried without improvement. The diagnosis of chronic atypical cluster headache was established during hospitalization. High-flow oxygen therapy led to rapid resolution of the pain, and preventive treatment with verapamil was subsequently initiated, resulting in complete disappearance of the attacks after five days. Six-month follow-up confirmed sustained stability without recurrence.

Discussion: Atypical forms of cluster headache, particularly side-shifting forms, may lead to significant diagnostic delay and may be mistaken for other primary headaches or facial neuralgias. The dramatic response to oxygen therapy is a major clinical argument supporting the diagnosis.

Conclusion: This case highlights the importance of precise semiological analysis in patients presenting with severe atypical headaches. Early diagnosis of cluster headache allows appropriate management and rapid improvement in quality of life.

P60 - Combined anterior fixation and posterior laminectomy for unstable subaxial cervical spine trauma: application of international decision-making algorithms (AO spine / AANS-CNS).

Fayçal Houari, Mokfi, Fardji, Derbale, Guerbouz.

University hospital of Oran, Algeria.

Background / introduction: The management of subaxial cervical spine (C3–C7) injuries involving three-column disruption and spinal cord compression remains complex. According to the official AOSpine classification system, type B (distraction) and type C (translation) injuries associated with neurological deficits require early stabilization. This study aims to evaluate the clinical and biomechanical efficacy of a combined approach—consisting of posterior decompressive laminectomy and anterior fixation/fusion—in compliance with the international guidelines issued by the AANS/CNS (American Association of Neurological Surgeons / Congress of Neurological Surgeons).

Materials and methods: A study was conducted on patients presenting with unstable subaxial cervical spine trauma (AOSpine Injury Score \ge 5) associated with persistent spinal cord compression and an initial American Spinal Injury Association (ASIA) Impairment Scale score of A to D. The standardized surgical strategy involved: A posterior approach for decompressive laminectomy, reduction of facet dislocations, and instrumentation using lateral mass or pedicle screws. An anterior arthrodesis (cage and plate construct) to restore the anterior weight-bearing column and cervical sagittal lordosis. Cervical alignment was evaluated using the sagittal Cobb angle.

Results: Anatomic alignment and circumferential canal decompression were successfully achieved in 96% of cases. At a minimum 12-month follow-up, the bone fusion rate (assessed via standardized CT-scan criteria) was 97.5%. An improvement of at least one grade on the ASIA Impairment Scale was documented in 72% of patients with an initial incomplete neurological deficit (ASIA B–D). No hardware failure or post-laminectomie kyphotic deformity was recorded, confirming the high biomechanical rigidity of the 360-degree construct.

Conclusion: In accordance with international scientific society guidelines (AO Spine and AANS/CNS), posterior laminectomy combined with anterior fixation represents the gold standard for subaxial cervical spine trauma presenting with major circumferential instability. This combined approach maximizes neurological recovery through optimal decompression while effectively preventing secondary sagittal malalignment thanks to anterior column support.

P61 - Comparison of infection rates between prefabricated and manually assembled external ventricular drainage systems: a retrospective single-center study

Khalil Ayadi, F. Kolsi, M Taallah, S Abdelmoleh, M Borni, B Kammoun, MZ Boudawara

Department of neurosurgery, Habib Bourguiba University Hospital, Sfax, Tunisia

Background: External ventricular drainage (EVD) is a cornerstone in the management of acute hydrocephalus and elevated intracranial pressure. Ventriculostomy-related infection remains one of its most significant complications. While prefabricated commercial EVD systems have been introduced to reduce infection risk, manually assembled systems remain widely used in resource-limited settings. This study compared infection rates between prefabricated and manually assembled EVD systems in a tertiary neurosurgical center.

Methods: We conducted a retrospective review of consecutive patients who underwent EVD placement at our institution. Patients were divided into two groups according to the type of drainage system used: prefabricated commercial kit or manually assembled system. Demographic data, clinical indications, and postoperative outcomes were reviewed. The primary outcome was ventriculostomy-related meningitis. Infection rates were compared using Fisher's exact test.

Results: A total of 117 EVD procedures were included, comprising 66 prefabricated systems and 51 manually assembled systems. Ventriculostomy-related meningitis occurred in 10 patients (15.2%) in the prefabricated group and 9 patients (17.6%) in the manual group. The difference was not statistically significant (Fisher's exact test, $p = 0.80$). The relative risk of infection with the prefabricated system was 0.86 compared with the manual system. No significant differences in early clinical outcomes were identified between the two groups.

Conclusions: In this retrospective single-center experience, prefabricated EVD systems were associated with infection rates comparable to those of manually assembled systems. These findings suggest that meticulous surgical technique and standardized catheter management protocols may have a greater impact on infection prevention than the choice of drainage system alone. Prospective multicenter studies with larger cohorts are needed to identify independent predictors of ventriculostomy-related infection.

P62 - Complications beyond closure: lessons from pediatric spina bifida

Majdouline Barkache, M.Ben Messaoud, H. Kammoun, A. Mribah, I. Ksira

Department of Neurosurgery, Sahloul Hospital, Sousse, Tunisia

Background: Surgical closure of myelomeningocele represents only the first step in the management of children with spina bifida. Despite successful repair, many patients experience neurosurgical complications requiring prolonged surveillance and additional interventions. This study aimed to characterize the spectrum of postoperative complications and identify patients at increased risk of secondary neurosurgical procedures.

Methods: A retrospective review was performed of pediatric patients who underwent myelomeningocele repair between 2012 and 2022 at our institution. Demographic data, lesion characteristics, associated Chiari II malformation, postoperative course, and follow-up records were analyzed. Early and late neurosurgical complications, including hydrocephalus, cerebrospinal fluid (CSF) leakage, wound complications, tethered cord syndrome, and need for reoperation, were evaluated.

Results: Thirty-four children were included, with a median follow-up of 4.8 years. Overall, 79.4% experienced at least one neurosurgical complication after initial repair. Hydrocephalus was the most frequent complication, occurring in 64.7% of patients, followed by tethered cord syndrome (20.6%), wound-related complications (14.7%), and CSF leakage (8.8%). Ventriculoperitoneal shunt placement was required in most patients with hydrocephalus, while 17.6% underwent at least one additional spinal procedure during follow-up. Children presenting with high-level lesions and associated Chiari II malformation had significantly higher rates of secondary neurosurgical interventions ($p<0.05$).

Conclusion: The management of pediatric spina bifida extends well beyond successful defect closure. Hydrocephalus, tethered cord syndrome, and other delayed complications remain frequent causes of reintervention. Long-term multidisciplinary follow-up is essential to detect complications early and optimize neurological outcomes. Recognition of high-risk patients may help tailor surveillance strategies and improve lifelong care.

P63 - Conservative management of complicated pott's puffy tumor with limited intracranial extension in a child

Fatma Ben Atig, Yassine Mokni, Yasmine Fouzri, Malek Bourgou, Kamel Ben Gayed

Department of neurosurgery, Regional Hospital Sadok Mkadem Djerba, Tunisia
ICU Department, Regional Hospital Sadok Mkadem Djerba, Tunisia

Introduction: Pott's puffy tumor (PPT) is a rare complication of frontal sinusitis characterized by frontal bone osteomyelitis associated with a subperiosteal abscess. Its potential for intracranial extension makes it a potentially life-threatening condition requiring prompt recognition. Management is generally based on combined surgical and antibiotic therapy, although exclusive medical treatment may be considered in selected cases.

Case report: A 14-year-old girl with a history of recurrent tonsillitis and recent frontal sinusitis presented with febrile intracranial hypertension syndrome, associated with nasal obstruction, ocular congestion, conjunctival injection, and postnasal drip. Brain MRI demonstrated frontal sinusitis with a right supraorbital frontal intraosseous collection consistent with frontal osteomyelitis. This was associated with a bifrontal epidural empyema and a millimetric intraparenchymal lesion suggestive of an early abscess, surrounded by perilesional edema. Given the absence of papilledema or neurological deficit, and considering potential aesthetic concerns, a conservative approach with prolonged intravenous antibiotic therapy was initiated. Follow-up MRI at 45 days showed complete resolution of the intracranial and osseous collections, with favorable evolution of the underlying osteitis.

Conclusion: Although surgical management remains the standard approach in complicated PPT, carefully selected patients with limited intracranial involvement and stable neurological status may achieve complete radiological resolution under exclusive antibiotic therapy with close monitoring.

P64 - Conus medullaris and cauda equina relapse of diffuse large b-cell lymphoma after complete remission: a rare case report

Majdouline Barkache, R.Benfredj, S.Galaoui, A.Guerioui, I.Kisra

Department of Neurosurgery, Sahloul Hospital, Sousse, Tunisia

Background: Secondary involvement of the conus medullaris and cauda equina by non-Hodgkin lymphoma (NHL) is exceptionally rare. Neurological relapse may occur despite prolonged remission and often mimics primary spinal tumors. We report a rare case of delayed central nervous system relapse of diffuse large B-cell lymphoma (DLBCL) presenting as a conus medullaris and cauda equina lesion.

Methods: A 67-year-old man with a history of DLBCL treated with chemotherapy and radiotherapy, achieving complete remission for four years, presented with rapidly progressive right lumbosciatic pain resistant to analgesics. Neurological examination revealed gait disturbance, right lower-limb monoparesis, and L5 radicular sensory deficits without sphincter dysfunction. Lumbar radiographs and CT scans were unremarkable. Magnetic resonance imaging demonstrated an enhancing lesion involving the conus medullaris and cauda equina roots. Surgical exploration through L1–L3 laminectomy was performed to obtain tissue diagnosis.

Results: Intraoperatively, multiple cauda equina roots appeared hypertrophic, grayish, and infiltrated. Biopsy of the most affected root was performed. Histopathological examination confirmed secondary localization of diffuse large B-cell lymphoma, consistent with the patient's original nodal disease. Postoperatively, the patient experienced marked relief of radicular pain, improvement of motor deficit, and recovery of independent ambulation. Adjuvant chemotherapy including corticosteroids was subsequently initiated.

Conclusions: Conus medullaris and cauda equina relapse of DLBCL is an exceptionally uncommon manifestation of systemic lymphoma. MRI is crucial for diagnosis, although imaging findings may mimic primary intradural tumors. Histological confirmation remains essential for therapeutic decision-making. Surgical biopsy or limited decompression can provide both diagnostic clarification and neurological improvement, while systemic chemotherapy remains the cornerstone of treatment. Awareness of this rare presentation is important, even years after complete remission.

P65 - Cutting the right roots: patient selection criteria for selective dorsal rhizotomy in spastic diplegia

Ameur Affes, Akrout F, Rachdi M.A., Kammoun T, Bouzouita K, Achoura S, Chkili Ridha, Radhouen K.

Neurosurgery Department, Military Hospital of Tunis, Tunis, Tunisia

Background & objectives: Selective dorsal rhizotomy (SDR) remains the only neurosurgical procedure offering permanent spasticity reduction in cerebral palsy-related spastic diplegia, yet its benefits are highly dependent on rigorous patient selection. Indiscriminate application yields disappointing functional outcomes, while appropriately selected candidates demonstrate lasting gait improvement and quality of life gains. Despite decades of clinical experience, selection criteria remain heterogeneous across centers. This review critically examines current evidence to define who truly benefits from SDR in spastic diplegia.

Methods: Narrative review of PubMed, Scopus, and Cochrane databases (2000–2024), including prospective cohort studies, long-term follow-up series, and consensus statements addressing SDR candidacy, functional outcomes, and complication profiles in pediatric spastic diplegia.

Results & discussion: Optimal candidate profile: Current evidence consistently identifies the following as favorable selection criteria: age 3–8 years, pure spastic diplegia without dystonic component, prematurity-related periventricular leukomalacia on MRI, preserved underlying muscle strength, GMFCS levels II–III, motivated family with access to intensive postoperative physiotherapy, and absence of fixed contractures requiring orthopedic correction. Neurophysiological selection: Intraoperative electromyographic assessment of dorsal rootlet responses remains central to SDR technique, distinguishing abnormal from normal sensory contributions and guiding selective sectioning to preserve residual motor and sphincteric function. Long-term outcomes: Appropriately selected patients demonstrate sustained spasticity reduction, improved gait kinematics, and reduced orthopedic intervention requirements at 10–20 year follow-up, supporting SDR as a disease-modifying rather than purely symptomatic intervention. Exclusion criteria: Significant dystonia, GMFCS levels IV–V, predominant weakness over spasticity, and lack of postoperative rehabilitation access are consistently associated with poor outcomes and constitute contraindications to SDR candidacy. SDR versus intrathecal baclofen: For higher GMFCS levels or polyspasticity, intrathecal baclofen pump represents a more appropriate alternative, underscoring the importance of individualized rather than uniform surgical decision-making.

Conclusion: SDR delivers transformative functional benefits — but exclusively in the right patient. Rigorous multidisciplinary selection combining neurological, functional, and rehabilitative criteria is the true determinant of surgical success, far more than technical execution alone.

P66 - Cystic frontal glioblastoma mimicking a low-grade glioma in a young adult with neurofibromatosis type 1

Aziz Abdelmoula, K. Abderrahmen, A. Ouesleti, E. Mzoughi, F. Sliti, E. Ouni

Neurosurgery Department of National Institute of Neurology, Tunis, Tunisia

Background: Glioblastoma typically presents as an infiltrative necrotic mass with marked contrast enhancement. In young patients with Neurofibromatosis Type 1 (NF1), radiological interpretation may be challenging because of the increased prevalence of low-grade gliomas and other benign central nervous system lesions.

Case presentation: A 23-year-old male presented with headaches and progressive left hemiplegia. Brain MRI demonstrated a well-circumscribed right frontal cystic lesion measuring 60 × 47 × 56 mm. The lesion exhibited T1 hypointensity, T2 hyperintensity, thin enhancing septations, and irregular peripheral nodular enhancement. Given the patient's age and imaging appearance, low-grade glioma was initially considered among the differential diagnoses. Magnetic resonance spectroscopy demonstrated increased choline levels and inversion of the choline/NAA ratio, while perfusion imaging showed elevated relative cerebral blood volume. Additional MRI findings included a probable optic pathway glioma and multiple spinal neurofibromas. Clinical examination revealed multiple café-au-lait macules and a positive family history suggestive of NF1. The patient underwent gross total resection. Histological analysis demonstrated an IDH-wildtype glioblastoma (WHO grade 4) with extensive necrosis, microvascular proliferation, ATRX loss, and a Ki-67 index of 25%.

Conclusion : This case highlights a significant radiological–pathological discordance in a young NF1 patient. Despite imaging characteristics suggestive of a lower-grade lesion, histopathology confirmed glioblastoma. Advanced imaging modalities were crucial in raising suspicion for a high-grade tumor. Awareness of atypical presentations of glioblastoma in NF1 may facilitate earlier diagnosis and management.

P67 - Cystic lesions of the sellar and suprasellar region: surgical indications and operative techniques: experience from a single-center series at EHS cherchell

Nasreddine Baz, Mati.A, Benallag.S, Chabat.A, Dergham.D, Bouaita.K

Department of Neurosurgery, EHS Cherchell, Algeria

Background: Cystic lesions of the sellar and suprasellar region, particularly sellar arachnoid cysts and Rathke's cleft cysts, are rare conditions that may present with visual disturbances due to compression of the optic pathways, pituitary dysfunction, or headache. Surgical treatment is indicated in cases of neuro-ophthalmological symptoms, endocrine impairment, or radiological evidence of enlargement. The endoscopic endonasal approach is the most commonly used technique for accessible lesions.

Methods: A retrospective descriptive study was conducted on five operated cases since 2020. Clinical and radiological data, surgical approaches, and follow-up outcomes were analyzed and then compared with recent literature data.

Results: Five patients, all presenting visual disturbances associated with hormonal impairment, underwent surgery. Four patients were treated by endoscopic endonasal fenestration, including three sellar arachnoid cysts and one Rathke's cleft cyst, while one female patient with a Rathke's cleft cyst underwent a transcranial approach. Two of the three sellar arachnoid cysts recurred and required reoperation. Among these recurrences, one patient underwent a second reoperation with placement of a T-shaped drainage catheter in the nasal cavities, which was later complicated by meningitis and then encephalitis, leading to catheter removal, closure of the defect, and antibiotic treatment. Hydrocephalus subsequently developed, requiring ventriculoperitoneal shunting, then ventriculoatrial shunting after several revisions due to poor peritoneal resorption. Four months later, another surgery was required for significant pneumocephalus, with repeat closure of the sellar floor and air decompression.

Conclusion: Sellar and suprasellar cystic lesions are rare entities whose surgical management is indicated in symptomatic cases. The endoscopic endonasal approach is the first-line technique in most cases, while the transcranial approach remains relevant in cases with suprasellar extension. Prevention of CSF leaks remains the major postoperative challenge due to the complications that may follow.

P68 - Decompressive craniectomy in severe traumatic brain injury: which patients truly benefit?

Majdouline Barkache, R. Benfredj, S. Galaoui, A. Guerioui, I.Kisra

Department of Neurosurgery, Sahloul Hospital, Sousse, Tunisia

Background: Decompressive craniectomy (DC) remains a controversial surgical option for patients with severe traumatic brain injury (TBI) and refractory intracranial hypertension. While it effectively lowers intracranial pressure, its impact on long-term functional outcomes remains debated. This study aimed to identify the clinical and radiological factors associated with favorable outcomes following DC in severe TBI patients.

Methods: A retrospective study was conducted on 68 consecutive patients who underwent decompressive craniectomy for severe TBI between January 2021 and December 2023 at a tertiary neurosurgical center. Demographic data, admission Glasgow Coma Scale (GCS), pupillary reactivity, initial computed tomography (CT) findings, timing of surgery, and postoperative complications were analyzed. Functional outcome was assessed at 6 months using the Glasgow Outcome Scale-Extended (GOSE). Favorable outcome was defined as GOSE ≥5.

Results: The mean age was 34.8 ± 15.2 years, and 79.4% of patients were male. The median admission GCS was 6. Favorable functional outcome at 6 months was achieved in 27 patients (39.7%), while mortality was 29.4%. Younger age (<40 years), admission GCS ≥6, preserved pupillary reactivity, absence of bilateral fixed pupils, and early decompressive craniectomy (<24 hours after injury) were significantly associated with favorable outcomes ($p<0.05$). Patients with diffuse cerebral edema without extensive brainstem injury demonstrated better recovery compared to those with bilateral mass lesions or signs of herniation. Multivariate analysis identified preserved pupillary response (OR=4.6; 95% CI: 1.8–11.9; p=0.002) and early surgery (OR=3.2; 95% CI: 1.2–8.7; p=0.018) as independent predictors of favorable outcome.

Conclusions: Decompressive craniectomy can provide meaningful functional recovery in selected severe TBI patients. Younger patients with preserved brainstem function, higher admission GCS, and early surgical intervention appear to derive the greatest benefit. Careful patient selection remains crucial to optimize outcomes and avoid futile surgery.

P69 - Delayed tetraventricular hydrocephalus secondary to post-traumatic foramen of magendie stenosis: a rare entity

Fatma Ben Atig, Yasmine Fouzri, Malek Bourgou, Kamel Ben Gayed

Department of neurosurgery, Regional Hospital Sadok Mkadem Djerba, Tunisia
ICU Department, Regional Hospital Sadok Mkadem Djerba, Tunisia

Introduction: Obstruction of the foramen of Magendie is a rare cause of fourth ventricular obstruction leading to tetraventricular hydrocephalus. In adults, acquired forms are exceptional and may occur following inflammatory, hemorrhagic, or post-traumatic arachnoiditis. Delayed post-traumatic stenosis of the foramen of Magendie remains an exceptionally uncommon entity.

Case presentation: A 45-year-old man with a history of severe traumatic brain injury requiring intensive care management presented ten years later with progressive gait instability, static cerebellar syndrome, and symptoms of intracranial hypertension. Brain MRI demonstrated tetraventricular hydrocephalus associated with stenosis below the foramen of Magendie, suggesting fourth ventricular outlet obstruction. No posterior fossa tumor or congenital malformation was identified. The patient underwent surgical treatment with subsequent clinical improvement and regression of intracranial hypertension symptoms.

Conclusion: Post-traumatic stenosis of the foramen of Magendie should be considered in patients presenting with delayed hydrocephalus years after severe traumatic brain injury. Although exceptionally rare, recognition of this surgically treatable cause of tetraventricular hydrocephalus is crucial, as appropriate management may result in significant clinical improvement.

P70 - Diffuse intracranial meningiomatosis following adjuvant radiotherapy for atypical meningioma: multifocal recurrence or radiation-induced tumors? a case report

Egueh Fahye Mohamed, Nessib N., Slimane A., Sliti F., Bouhoula A, Naceur M., Ghedira K., Bouali S, Abderahhmen K, Ben Said I, Kallel J.

Department of Neurosurgery, National Institute Mongi Ben Hmida of Neurology, Tunis, Tunisia

Introduction: Atypical meningiomas (WHO grade II) frequently recur despite macroscopically complete resection. While adjuvant radiotherapy improves local control, it carries a long-term risk of radiation-induced tumors. The development of multiple meningiomatous lesions several years after irradiation raises a challenging diagnostic dilemma: multifocal recurrence or radiation-induced meningiomas? We report a case that concretely illustrates this issue.

Case report: A 52-year-old male underwent three surgical interventions (2005, 2008, and 2020) for a right frontal WHO grade II meningioma, with complete resection confirmed at each procedure. Adjuvant radiotherapy was delivered following the second surgery in 2008. Fifteen years later, the patient presented with intracranial hypertension syndrome associated with left third cranial nerve palsy. Brain MRI demonstrated multiple extra-axial enhancing lesions involving both the supra- and infratentorial compartments, consistent with diffuse intracranial meningiomatosis, extending well beyond the initial tumor site.

Discussion: The prolonged latency period, multifocal nature of the lesions, and their extension beyond the original tumor site strongly suggest a radiation-induced origin. However, the history of recurrent atypical meningioma does not allow definitive exclusion of multicentric disease progression. This case highlights the diagnostic limitations of the classical Cahan criteria when irradiation has been performed to treat a pre-existing meningioma. Management of diffuse forms remains non-standardized, relying on an individualized strategy combining, as appropriate, surgery for symptomatic lesions, stereotactic radiosurgery, and systemic therapies.

Conclusion: This case illustrates the diagnostic complexity of meningiomatosis arising several years after adjuvant radiotherapy for atypical meningioma. It underscores the importance of prolonged neuroradiological surveillance in irradiated patients and the need to better define the criteria distinguishing multifocal recurrence from true radiation-induced disease.

P71 - Does surgical position matter? impact of prone versus knee-chest position on blood loss in lumbar fusion surgery

Mohamed Amine Hmida, M.Benmessaoud, M.Baazoug, S.Guellim, A.Chaouech, I.Ksira

Department of Neurosurgery, Sahloul Hospital, Sousse, Tunisia

Introduction: Intraoperative blood loss remains a significant concern in lumbar fusion surgery. The conventional prone position may increase epidural venous engorgement through abdominal compression and elevated intra-abdominal pressure, potentially leading to greater blood loss and transfusion requirements. Optimizing patient positioning may therefore represent a simple and effective strategy to improve perioperative outcomes.

Objective: To evaluate the impact of surgical positioning on perioperative transfusion requirements in patients undergoing lumbar fusion surgery.

Materials and methods: A retrospective comparative study was conducted on a cohort of 142 patients undergoing lumbar fusion procedures. Patients were divided into two groups according to surgical positioning: Knee-Chest Position Group Prone Position Group The primary outcome was the requirement for packed red blood cell (PRBC) transfusion. Factors associated with transfusion risk were analyzed using multivariate statistical methods.

Results: The prone position was used in 39.4% of cases and emerged as the strongest independent predictor of blood transfusion requirement (regression coefficient = 0.33). Patients positioned prone demonstrated increased perioperative blood loss and a higher likelihood of requiring transfusion compared with those operated in the knee-chest position. Maintenance of low intrathoracic pressure and optimization of surgical positioning appeared to be critical determinants in minimizing venous congestion, reducing blood loss, and limiting postoperative anemia.

Conclusion: Surgical positioning significantly influences perioperative blood management during lumbar fusion surgery. Whenever technically feasible, the knee-chest position should be preferred to reduce transfusion requirements. When prone positioning is unavoidable, enhanced hemodynamic monitoring and meticulous hemostatic control are recommended to mitigate bleeding-related complications.

P72 - Dorsal thoracic arachnoid web: a rare and underdiagnosed cause of spinal cord compression

Haifa Mechergui, Salim Bachraoui, Emna Mzoughi, Mohamed Fahy, Sofiene Bouali, Jalel Kallel

* Surgery Department, Habib Bougatfa Hospital, Bizerte, Tunisia
** Neurosurgery Department, National Institu Of Neurology of Tunis, Tunisia.

Dorsal thoracic arachnoid webs are rare intradural extramedullary lesions and an uncommon cause of spinal cord compression. They consist of abnormal arachnoid bands that indent the dorsal surface of the spinal cord, leading to anterior displacement and progressive myelopathy. We report the case of a 50-year-old man with no significant medical history who presented with progressive gait disturbance and weakness of the right lower limb evolving for 1 year. He had no urinary symptoms or sensory deficit. Spinal magnetic resonance imaging revealed agittal the scalpel sign at the T5-T6 level, with anterior cord displacement and dorsal subarachnoid space enlargement. The patient underwent thoracic laminectomy with surgical fenestration and excision of the arachnoid web. Postoperatively, the patient demonstrated significant neurological improvement, including increased lower limb strength and improved gait stability. Dorsal thoracic arachnoid webs are frequently underdiagnosed because their clinical and radiological presentation may mimic other spinal disorders, particularly idiopathic ventral spinal cord herniation and arachnoid cysts. Delayed diagnosis can result in progressive myelopathy and functional decline. This case emphasizes the importance of recognizing characteristic imaging findings and performing timely surgical decompression. Arachnoid web fenestration and excision can lead to meaningful neurological recovery and improved functional outcomes.

P73 - Double jeopardy: managing concurrent cervical spinal cord injury and near-drowning after diving accidents

Ameur Affes, Khayat M, Bouzouita K, Rachdi M.A., Kammoun T, Achoura S, Chkili Ridha, Radhouen K.

Neurosurgery Department, Military Hospital of Tunis, Tunis, Tunisia

Background & objectives: Recreational diving accidents represent a uniquely devastating injury mechanism, simultaneously exposing victims to cervical spinal cord injury through axial compression-hyperflexion and to hypoxic-anoxic brain injury through submersion and near-drowning. This dual insult creates a clinical scenario of exceptional complexity — two life-threatening emergencies competing for simultaneous management priority, with each intervention potentially compromising the other. No standardized protocol currently addresses this concurrent injury pattern. This review examines the pathophysiology, emergency management challenges, and neurosurgical decision-making framework for concurrent cervical spinal cord injury and near-drowning after diving accidents.

Methods: Narrative review of PubMed, Scopus, and trauma databases (2000–2024), including case series, drowning resuscitation guidelines, spinal cord injury management protocols, and emergency medicine literature addressing concurrent cervical trauma and submersion injury management.

Results & discussion: Pathophysiological interaction: Cervical spinal cord injury below C4 compromises respiratory drive and airway protection, compounding submersion-induced hypoxia and aspiration pneumonia risk. Simultaneously, resuscitation maneuvers — particularly cervical spine positioning during airway management — risk aggravating unstable cervical fractures, creating a critical intervention conflict from the first seconds of rescue. Pre-hospital management: Aquatic extraction maintaining strict cervical spine immobilization while enabling effective airway management and resuscitation represents the primary pre-hospital challenge. Modified jaw thrust, supraglottic airway devices, and log-roll extraction protocols adapted to aquatic environments are recommended over standard resuscitation positioning. Emergency resuscitation priorities: Airway and oxygenation take absolute precedence over spinal immobilization concerns in apneic victims — hypoxic brain injury progression within minutes outweighs fracture displacement risk from controlled airway maneuvers. Hemodynamic optimization targeting MAP ≥ 85 mmHg simultaneously addresses both cerebral and spinal cord perfusion requirements. Neuroimaging strategy: Whole-spine CT combined with brain CT in a single trauma acquisition optimizes diagnosis efficiency without delaying resuscitation. MRI is deferred until hemodynamic and respiratory stabilization is confirmed. Surgical timing: Neurosurgical decompression follows respiratory stabilization, targeting the established less-than-24-hour window while accounting for pulmonary injury severity and anesthetic risk imposed by concurrent near-drowning.

Conclusion: Concurrent cervical spinal cord injury and near-drowning demands a sequenced, priority-driven management algorithm where airway and oxygenation precede spinal stabilization, and neurosurgical intervention follows systemic stabilization — without losing the critical decompression window.

P74 - Dural metastasis from lung adenocarcinoma mimicking a meningioma: a diagnostic challenge

Mohamed Amine Hmida, M.Benmessaoud, M.Barkache, O.Hattab, I.Ksira

Department of Neurosurgery, Sahloul Hospital, Sousse, Tunisia

Introduction: Dural metastases are uncommon intracranial lesions that may radiologically mimic benign extra-axial tumors, particularly meningiomas. Differentiating between these entities preoperatively can be difficult, as both may present with similar clinical and imaging features. Histopathological examination remains the gold standard for diagnosis.

Case presentation: A 60-year-old man presented with a several-month history of progressive symptoms of intracranial hypertension, including persistent headaches, associated with recurrent seizures. Neurological examination was otherwise unremarkable. Brain magnetic resonance imaging (MRI) revealed a well-circumscribed extra-axial dural-based lesion with homogeneous contrast enhancement and imaging characteristics highly suggestive of a meningioma. No radiological features strongly indicated a metastatic origin. Given the symptomatic mass effect and presumed diagnosis of meningioma, surgical resection was undertaken. Management and Outcome Gross total resection of the lesion was achieved. Unexpectedly, histopathological examination demonstrated a dural metastasis from a pulmonary adenocarcinoma. Subsequent systemic investigations identified a primary lung malignancy that had previously remained undiagnosed. The patient was referred for multidisciplinary oncological management, including staging workup and adjuvant therapy.

Discussion: Dural metastases account for a small proportion of intracranial metastatic disease and frequently originate from breast, prostate, or lung carcinomas. Their radiological resemblance to meningiomas may lead to diagnostic uncertainty, particularly in patients without a known history of cancer. Certain imaging features, such as disproportionate peritumoral edema, bone destruction, or rapid growth, may raise suspicion; however, definitive diagnosis often relies on histopathological analysis. This case highlights the importance of considering metastatic disease in the differential diagnosis of any dural-based lesion, even when imaging findings strongly favor a benign meningioma.

Conclusion: Dural metastasis from lung adenocarcinoma may closely mimic a meningioma both clinically and radiologically. Histopathological examination remains essential for establishing the diagnosis. Neurosurgeons should maintain a high index of suspicion for metastatic disease, particularly in older patients presenting with atypical clinical or radiological features.

P75 - Early surgery matters: predictors of favorable outcomes in pediatric chiari I malformation

Majdouline Barkache, M. Ben Messaoud, S. Galaoui, H.Kamoun, I.Ksira

Department of Neurosurgery, Sahloul Hospital, Sousse, Tunisia

Background: Posterior fossa decompression (PFD) is the standard surgical treatment for symptomatic Chiari I malformation (CM-I) in children. Although most patients improve, outcomes remain variable. This study aimed to identify factors associated with favorable postoperative outcomes.

Methods: We retrospectively reviewed pediatric patients who underwent PFD for symptomatic CM-I between 2012 and 2022. Demographic, clinical, and radiological data, including syringomyelia characteristics, tonsillar herniation, and neurological status, were analyzed. Surgical success was defined as sustained clinical improvement with radiological stability or regression of syringomyelia during follow-up. Predictors of favorable outcome were assessed using univariate analysis.

Results: Twenty-eight children (mean age 10.3 ± 3.6 years) were included. Overall, 22 patients (78.6%) achieved successful outcomes. Headache improved in 70% of patients, neurological deficits in 60%, and syringomyelia regressed or resolved in 65%. Favorable outcomes were significantly associated with age <12 years (p=0.03), symptom duration <12 months (p=0.02), absence of severe preoperative neurological deficits (p=0.01), and syrinx diameter <6 mm (p=0.01). The degree of tonsillar herniation was not significantly associated with outcome (p=0.41). No mortality occurred. Two patients developed transient cerebrospinal fluid collections that resolved with conservative treatment.

Conclusion: PFD provides favorable clinical and radiological outcomes in most pediatric patients with CM-I. Earlier surgery, milder neurological impairment, and smaller syringomyelia predict better outcomes, whereas tonsillar descent alone does not. Comprehensive clinical and radiological assessment should guide surgical decision-making.

P76 - Early versus delayed cranioplasty after decompressive craniectomy: a systematic review, meta-analysis, and retrospective cohort study of complications, infection rates, and neurological outcome

Bushra Anwar Kurdi, Reenad Hani Mohammed[1], Hazim Nasser Alahmadi[1], Abeer Mutair Alshamani[3], Fares Ihsan Alnoaman[1], Hazim Abdulrahman Alahmadi[1], Jawad Khalid Alsaedi[1], Rafa Abdulhameed Aluofi[2], Sadeen Hussain Alharbi[1], Bassem Yousef Sheikh[3]

[1] College of Medicine, Taibah University, Medina, Saudi Arabia

[2] Medical Intern, Taibah University, Medina, Saudi Arabia

[3] Department of Neurosurgery, King Salman bin Abdulaziz Medical City, Medina, Saudi Arabia

Background: Decompression craniectomy (DC) is a commonly performed neurosurgical procedure used to reduce elevated intracranial pressure in conditions such as traumatic brain injury and malignant cerebral infarction. Cranioplasty (CP), performed after DC, restores cranial integrity, protects the brain, and may contribute to neurological recovery. However, the optimal timing of cranioplasty remains controversial. While some studies suggest that early cranioplasty may improve neurological recovery, others report no significant difference in outcomes and raise concerns about increased complication rates.

Objective: This study aims to evaluate the effect of early versus delayed cranioplasty on neurological outcomes and postoperative complications through a systematic review, meta-analysis, and a retrospective cohort study. Method: A systematic review and meta-analysis: Conducted in accordance with PRISMA 2020 guidelines. A comprehensive literature using databases, including PubMed, Ovid, ProQuest, Web of Science, and Google Scholar, covering studies published between 2015 and 2025. Eligible studies included adult patients undergoing early (≤3 months) versus delayed (>3 months) cranioplasty following decompressive craniectomy.

Results: Primary outcomes: Neurological and functional measures (mRS, GOS, MMSE, GCS). Secondary outcomes: Postoperative complications (infection, hydrocephalus, hematoma, seizures, reoperation). Retrospective cohort study: Conducted in Al-Madinah government hospitals, including 31 patients stratified into early and delayed groups. Statistical analysis was performed using SPSS, with significance set at $p \leq 0.05$

Conclusion: The timing of cranioplasty after decompressive craniectomy does not have a significant effect on long-term functional outcomes or major postoperative complications. However, findings from the retrospective cohort suggest a trend toward better neurological outcomes with delayed cranioplasty, supporting an individualized approach to timing based on patient-specific factors.

P77 - En plaque meningiomas: diagnostic features and surgical-challenges

Amel Sebti, Bennas, Sahraoui
EPH Oum El Bouagui, CHU Blida, Algeria

Background: En plaque meningioma (EPM) is an uncommon subtype of meningioma characterized by a sheet-like growth pattern along the dura mater rather than a well-circumscribed mass. It is most frequently located at the sphenoid wing and is often associated with hyperostosis of the adjacent skull, making diagnosis and surgical management challenging.

Objective: To review the clinical presentation, radiological characteristics, treatment strategies, and outcomes of en plaque meningiomas, with emphasis on the importance of multidisciplinary management.

Methods: A narrative review of the literature and current clinical evidence was conducted, focusing on epidemiology, imaging findings, histopathology, surgical techniques, and postoperative outcomes.

Results: Patients commonly present with headaches, visual disturbances, cranial nerve deficits, or cosmetic deformities depending on tumor location. Magnetic resonance imaging with contrast is the diagnostic modality of choice, while computed tomography is useful for assessing associated hyperostosis. Surgical resection remains the mainstay of treatment, although complete excision may be difficult because of bone and neurovascular involvement. Adjuvant radiotherapy may be considered for residual or recurrent disease. Overall prognosis is favorable with appropriate management, but long-term follow-up is recommended due to the risk of recurrence.

Conclusion: En plaque meningioma is a rare entity with distinctive clinical and radiological features. Early recognition, meticulous surgical planning, and individualized treatment strategies are essential to optimize neurological and functional outcomes while minimizing recurrence.

P78 - Encephaloceles: a single-center experience with 50 cases

Sara Dellaldja, W. Khoudir, K. Boustil, CH. Zair, L. Atroune

EHS ALI AIT AIDIR, Algiers, Algeria

Background: Encephalocele is a complex congenital malformation of the central nervous system characterized by herniation of intracranial contents through a skull defect. It remains a common condition in pediatric neurosurgery in developing countries. We report our institutional experience in the surgical management of encephaloceles.

Methods: We retrospectively reviewed 50 consecutive patients who underwent surgical treatment between January 2015 and December 2025. Data collected included age, sex, encephalocele size, quality of the overlying skin, associated congenital anomalies, hydrocephalus, venous sinus anatomy, timing of surgery, postoperative complications, and outcome.

Results: All patients underwent surgery. Females were predominant. Surgical treatment consisted of excision of the encephalocele sac with watertight dural closure. Cranioplasty was required in one patient. Postoperative complications included cerebrospinal fluid leakage in four patients and meningitis in seven. Ventriculoperitoneal shunt placement was performed in 26 patients, while eight underwent endoscopic third ventriculostomy. Four patients died during follow-up.

Conclusions: Encephaloceles remain a frequent congenital anomaly in our setting. Early surgical management, preferably during the neonatal period, is associated with improved outcomes. Optimal care requires a multidisciplinary team including pediatric neurosurgeons, anesthesiologists, intensivists, and neonatologists to minimize complications and improve survival.

P79 - Endolymphatic sac tumor: a case report and review of the literature

Sara Belmokhtar, Chennaoui, Abdellaoui, Mati, Bouaita.

EHS Cherchell, medical faculty of Blida, University Saad Dahlab of Blida, Algeria

Endolymphatic sac tumors (ELSTs) are rare, histologically low-grade but locally aggressive neoplasms arising from the endolymphatic sac of the posterior petrous bone. They are frequently associated with von Hippel–Lindau disease and often present with progressive audiovestibular symptoms, making diagnosis challenging. We report the case of a 32-year-old male who presented with tinnitus, headaches, cerebellar ataxia, and vestibular syndrome. Magnetic resonance imaging revealed a large left cerebellar cystic lesion with an enhancing solid component causing brainstem compression and hydrocephalus. The tumor was initially misdiagnosed radiologically. Surgical management included ventriculoperitoneal shunt placement followed by complete tumor resection via a retrosigmoid approach, with full postoperative neurological recovery. Histopathological examination demonstrated a papillary epithelial tumor with a characteristic double cell layer and a richly vascularized core. Immunohistochemistry was consistent with an endolymphatic sac origin. This case underscores the importance of multidisciplinary correlation for accurate diagnosis and highlights surgery as a curative treatment when performed early.

P80 - Endoscopic endonasal surgery for pediatric craniopharyngioma: feasibility and technical challenges

Hamza Bouchekoura, C. Handis, S.Meziani, Y.Felissi, A. Morsli.

Mohamed Lamine Debaghine University Hospital, Bab el oued, Algiers, Algeria.

Background: Craniopharyngiomas remain a surgical challenge because of their close relationship with the optic apparatus, hypothalamus, pituitary stalk, and major vascular structures. The endoscopic endonasal approach (EEA) has gained increasing acceptance as a minimally invasive route to selected sellar and suprasellar lesions. Its application in pediatric patients remains limited because of anatomical constraints and technical challenges. We report a pediatric case of craniopharyngioma treated through an endoscopic endonasal approach and discuss the surgical nuances of this technique.

Methods: A child with a sellar-suprasellar craniopharyngioma underwent endoscopic endonasal resection. Clinical presentation, radiological findings, surgical technique, postoperative course, and early outcome were retrospectively reviewed. Particular attention was paid to tumor exposure, microsurgical dissection, and preservation of critical neurovascular structures.

Results: The tumor was approached through a direct endoscopic midline corridor, allowing excellent visualization of the lesion and surrounding anatomy. Satisfactory tumor resection was achieved while preserving the optic pathways and hypothalamic structures. The absence of brain retraction facilitated safe dissection. No major intraoperative complications occurred. Postoperatively, visual status remained stable. Endocrine dysfunction was observed and successfully managed with appropriate hormone replacement therapy. Early postoperative imaging confirmed adequate tumor removal.

Conclusions: The endoscopic endonasal approach is a feasible and effective option for selected pediatric craniopharyngiomas. It provides direct access to the sellar and suprasellar region with excellent visualization and limited surgical morbidity. Careful patient selection, familiarity with pediatric skull base anatomy, and multidisciplinary management are essential to optimize outcomes.

P81 - Epidemiological profile of traumatic brain injury: a retrospective analysis of 511 cases from the neurosurgery department of monastir

Syrine Saadoun, A.Trifa, W.Belgacem, I.Ferchichi, N.Yahyaoui, M.Darmoul

Neurosurgery Department, Fattouma Bourguiba University hospital, Monastir, Tunisia.

Introduction: Traumatic brain injury (TBI) remains a major public health concern worldwide, representing a leading cause of mortality and disability, particularly among young adults. Understanding its epidemiological characteristics and management outcomes is essential for improving preventive and therapeutic strategies. This study aimed to analyze the epidemiological, clinical, radiological, therapeutic, and outcome characteristics of patients admitted for TBI in a tertiary neurosurgical center.

Methods: We conducted a retrospective descriptive study including all patients admitted for traumatic brain injury to the Department of Neurosurgery at Fattouma Bourguiba University Hospital, Monastir, Tunisia, between 2020 and 2023. Demographic characteristics, injury mechanisms, clinical presentation, imaging findings, treatment modalities, and outcomes were analyzed.

Results: A total of 511 patients were included. The mean age was 30.7 years, with a marked male predominance (84.7%; sex ratio 5.55). Road traffic accidents were the leading cause of injury, accounting for 55.8% of cases, followed by falls and assaults. Among injured motorcyclists, 94.6% were not wearing a helmet. Initial loss of consciousness was reported in 83.9% of patients. Most patients presented with mild TBI, with a Glasgow Coma Scale (GCS) score of 15 in 69.9% of cases, while 6.6% had a GCS below 13. Motor deficits were observed in 5.5% of patients and seizures in 7.4%. Computed tomography revealed cerebral contusions in 52.8% of patients, subarachnoid hemorrhage in 45.8%, extradural hematoma in 35.6%, and subdural hematoma in 29.8%. Skull fractures were identified in 66.1% of cases. Surgical treatment was required in 25.4% of patients, mainly for evacuation of extradural hematomas and depressed skull fractures. The mean delay to surgery was 15 hours and 40 minutes. Clinical outcome was favorable in 89.2% of patients. Early complications occurred in 5.3% of cases, predominantly post-traumatic epilepsy. Overall mortality was 0.78%, and the mean hospital stay was 6.1 days.

Conclusion: Traumatic brain injury predominantly affects young males and is mainly related to road traffic accidents. The high proportion of non-helmeted motorcyclists highlights the need for stronger preventive measures. Despite the frequency of intracranial lesions, outcomes were generally favorable, reflecting the effectiveness of early neuroimaging and timely neurosurgical management. Continued efforts in prevention and optimization of trauma care pathways remain essential to reduce the burden of TBI in developing countries.

P82 - Epidemiological, clinical and therapeutic profile of dorsolumbar myelomeningocele: a 10-year experience with 78 cases from the neurosurgery department of monastir

Syrine Saadoun, Amine Trifa, Melek Jary, Iness Ferchichi, Nader Yahyaoui, Mehdi Darmoul

Neurosurgery Department, Fattouma Bourguiba University hospital, Monastir, Tunisia.

Background: Myelomeningocele (MMC) is the most severe form of open neural tube defect and remains a major public health challenge in low- and middle-income countries. Delayed diagnosis, inadequate prenatal prevention, and limited access to specialized care contribute to poor neurological outcomes. This study aimed to evaluate the epidemiological, clinical, radiological, surgical, and functional outcomes of patients with dorsolumbar and lumbosacral MMC managed at a tertiary neurosurgical center.

Methods: We conducted a retrospective study of 78 patients with dorsal, dorsolumbar, lumbar, or lumbosacral MMC treated at the Neurosurgery Department of Fattouma Bourguiba University Hospital, Monastir, Tunisia, between January 2014 and December 2023. Patients with at least one year of follow-up were included. Demographic, clinical, radiological, surgical, and outcome data were analyzed.

Results: Seventy-eight patients were included, with a male predominance (64.1%) and a mean age at admission of 11.8 ± 7.8 months. Only 30% of mothers received folic acid supplementation, and 41% had inadequate prenatal care. Lumbar (35.8%) and lumbosacral (28.2%) lesions predominated. Motor deficits were present in 61.6% of patients, sphincter dysfunction in 48.7%, developmental delay in 62.8%, orthopedic deformities in 33.3%, and hydrocephalus in 70.5%. Surgical repair was performed in 97.4% of cases, with a mean delay of 8.8 ± 7.6 months, while ventriculoperitoneal shunting was required in 53.8%. Immediate postoperative outcomes were favorable in 65.4% of patients. Postoperative meningitis occurred in 21.8%, and overall mortality was 3.8%. At long-term follow-up, favorable functional outcomes were achieved in 69.1% of patients, although persistent motor deficits remained frequent.

Conclusion: Myelomeningocele remains associated with considerable neurological morbidity in our setting. Early diagnosis, systematic folic acid supplementation, improved prenatal screening, and timely referral to specialized centers are essential to reduce disability and improve long-term outcomes.

P83 - Epidural spinal cavernoma presenting as lumbar radiculopathy: a case report

Mohamed Ghorbel, G.Patet, C.Barrey

Spine Surgery Department of Pierre Wertheimer Hospital, Lyon, France

Background: Spinal cavernomas are rare vascular malformations of the central nervous system, most commonly located within the vertebral body or intramedullary compartment. Pure epidural cavernomas without any osseous or intradural extension are extremely rare, accounting for approximately 4% of spinal epidural lesions. They may mimic more common degenerative or cystic lesions, leading to diagnostic difficulty.

Methods: We report the case of a 56-year-old female who presented with progressive bilateral lumbar radiculopathy associated with symptoms of lumbar spinal canal stenosis. Preoperative MRI revealed a posterior epidural lesion compressing the dural sac in the lumbar region. The initial radiological diagnosis was a synovial cyst. The patient underwent surgical exploration and complete excision of the lesion.

Results: Intraoperative findings revealed a highly vascular epidural mass. Histopathological examination confirmed the diagnosis of a spinal cavernous hemangioma. Postoperatively, the patient experienced rapid and significant improvement in radicular pain . No perioperative complications were observed.

Conclusions: Spinal epidural cavernomas should be considered in the differential diagnosis of chronic lumbar radiculopathy with atypical MRI features. Preoperative diagnosis remains challenging, and definitive diagnosis is often made intraoperatively and confirmed histologically. Early surgical resection is safe and effective, leading to favorable neurological outcomes and preventing hemorrhagic or compressive complications. Although fewer than 50 cases of lumbar epidural cavernomas have been reported in the literature, this case adds valuable insight into their clinical presentation and management.

P84 - Epidural spinal cord compression due to metastasis from nasopharyngeal carcinoma: case report of an uncommon presentation

Mohamed Amine Hmida, A.Trifa, G.Belkahla, A.Oueslati, I.Krifa, K.Maamri, M.Darmoul

Neurosurgery Department, Fattouma Bourguiba University hospital, Monastir, Tunisia.

Nasopharyngeal carcinoma (NPC) most commonly metastasizes to the bones, lungs, and liver. Spinal epidural metastasis is rare and usually represents a late manifestation. Early recognition is crucial to prevent irreversible neurological deficits. We report the case of a 52-year-old man previously treated for NPC who presented with progressive lower limb weakness and back pain. Neurological examination revealed paraparesis with a sensory level at T8. Spinal MRI demonstrated an epidural mass compressing the thoracic spinal cord, arising from the posterior elements of T7–T8, consistent with metastatic involvement. The patient underwent urgent decompressive laminectomy followed by adjuvant radiotherapy. Histopathological analysis confirmed metastatic undifferentiated carcinoma consistent with a nasopharyngeal origin. Postoperative recovery was marked by partial neurological improvement and better pain control. Spinal epidural metastasis from NPC is extremely uncommon, particularly as an initial site of relapse. Any patient with a history of NPC presenting with new spinal symptoms should raise suspicion of metastatic disease. MRI remains the gold standard for diagnosis, while prompt surgical decompression combined with radiotherapy offers the best chance for neurological preservation and symptom relief. This case illustrates a rare manifestation of nasopharyngeal carcinoma and emphasizes the importance of early imaging and multidisciplinary management to optimize prognosis and quality of life in patients with spinal cord compression due to metastatic disease.

P85 - ERAS protocols in brain tumour surgery

Mahmoud Taha,
Dallaha Hospital - Alkhobar - Saudi Arabia

ERAS is enhanced recovery after surgery. It was initiated in early 1990 by Prof. Kehlet and adopted in many surgical specialities including general surgery, urology, and thoracic. ERAS protocols modify the physiological responses to major surgery which result in reduction in complications and length of stay in hospitals. The key principles for n ERAS are to maintain the pre operative organ functions and reduce the profound stress response after surgery. The protocols have three phases of actions : pre operative , intra operative and post operative. The cases for ERAS have to be selected well and it depends on type of procedure, age of patient and its comorbidities. The important actions that will be taken in the protocols are : pre op. Counselling, fluids loading, avoid prolong fasting avoid drains, avoid intra op hypothermia , pain control, prevent nausea and vomiting, early mobilisation …etc. Different hospitals and centres have designed their own protocols for spinal surgery, and recently for brain tumour surgery. Several studies have shown that the length of stay was reduced dramatically and the overall cost. In conclusion we propose that ERAS protocols can be utilised in n brain tumour surgery in selected cases especially in high volume centres.

P86 - Extended sphenoclival chordoma: surgical challenges and limits of the endoscopic endonasal approach.

Ferradji Salim Atmane, A Hachid, K.Izirouel

Department Of Neurosurgery, Mustapha University Hospital, Algeria.

Background: Sphenoclival chordomas are rare, locally invasive skull base tumors originating from remnants of the primitive notochord. While the endoscopic endonasal approach (EEA) provides an optimal direct corridor for midline clival lesions, tumors with extensive lateral and intradural progression push the technical boundaries of exclusive endoscopic resection. We evaluate these anatomical limits through a complex case presentation.

Methods: We review the clinical presentation, radiological features, and surgical management of a 35-year-old male admitted with a three-month history of progressive horizontal diplopia. High-resolution MRI and CT imaging demonstrated a voluminous, osteolytic clival mass with bilateral cavernous sinus extension, complete encasement of the paraclival internal carotid arteries (ICA), and retroclival subdural infiltration causing severe brainstem compression. A multidisciplinary decision led to an expanded EEA for tumor resection and decompression.

Results: A maximal safe tumor cytoreduction was achieved. Midline decompression effectively relieved mass effect on the brainstem. However, complete resection was limited laterally by dense tumor adherence to the adventitia of the encased ICAs, and posteriorly by the absence of a distinct arachnoid dissection plane along the ventral surface of the brainstem and critical perforating vessels. There were no major intraoperative neurovascular complications, and the patient's abducens nerve palsy partially improved postoperatively.

Conclusions: Extended sphenoclival chordomas present formidable surgical challenges where the risk of aggressive gross total resection outweighs the benefits. In these extensive forms, the paradigm must favor maximal safe decompression over radicality. This strategic cytoreduction successfully preserves neurological function and quality of life while crucial widening the anatomical corridor between vital neurovascular structures and the residual mass, thereby optimizing the safety and efficacy of subsequent adjuvant proton beam therapy.

P87 - Familial cerebral cavernomatosis revealed by intracranial hypertension in a 9-year-old child: a case report

Rim Baklouti, K. Maamri, A. Chaaben, M. Darmoul.

Neurosurgery Department, Fattouma Bourguiba University hospital, Monastir, Tunisia.

Background: Cerebral cavernous malformations (cavernomas) are vascular anomalies that can occur sporadically or in a familial, autosomal dominant form, the latter typically presenting as multiple lesions and an earlier age of onset. Familial cerebral cavernomatosis should be suspected when a pediatric patient with a positive maternal history presents with neurological symptoms. We report the case of a 9-year-old child with a maternal history of cerebro-medullary cavernomatosis who presented with acute signs of intracranial hypertension.

Methods: A 9-year-old boy, born to a mother with known cerebro-medullary cavernomatosis, presented with a 3-day history of signs of intracranial hypertension (headache, vomiting, and visual disturbance). Clinical examination and neuroimaging were performed. A non-contrast cerebral CT scan was obtained as the initial diagnostic step.

Results: CT imaging revealed two mirror-image, para-sagittal fronto-parietal cavernomatous lesions, consistent with the typical "popcorn-like" appearance of cavernomas, with millimetric areas of hyperdensity suggestive of recent microhemorrhage within the lesions. The symmetric, bilateral distribution of the lesions, together with the maternal history, was strongly suggestive of a familial form of cerebral cavernomatosis with minor hemorrhagic foci.

Conclusions: This case illustrates the importance of considering familial cerebral cavernomatosis in children presenting with acute signs of intracranial hypertension, particularly when there is a positive maternal family history. The bilateral, mirror-image fronto-parietal distribution, with millimetric hemorrhagic foci, underscores both the genetic predisposition and the potential for subtle hemorrhagic activity even in the absence of large-volume bleeding in pediatric cavernomatosis. Prompt neuroimaging, close neurosurgical evaluation, genetic counseling for at-risk family members, and rigorous clinical and radiological follow-up are essential to detect progression and prevent further morbidity.

P88 - Foraminal syringomyelia: how I manage it?

Abdelaziz Bennadji, Ouarda Guerza, Ouarda Zeroual, Zhor Mekentichi.

University Batna, Batna university hospital center, Algeria

Background: Foraminal Syringomyelia is the result of abnormal CSF circulation. Although MRI has facilitated confirmation of the diagnosis .The, diagnostic delays remain lengthy. Several surgical techniques have been used with differing results. The problematic question is when to operate? how to confirm the C1 C2 stability ?witch surgical technique to use ? And how to manage the central neuropathic pain?

Methods: We report a prospective study of patients with foraminal syringomyelia operated using a single operative technique consisting of bony decompression of the foramen magnum and the posterior arch of C1, opening of the dura, arachnoid dissection, coagulation of the tonsils and closure with a dural plasty. A preoperative and postoperative clinical assessment is used using the ASIA score, the visual analog pain scale, the DN4 questionnaire the McCormick classification, the Karnofsky index, and radiological assessment using the Vaquero index, cyst length, the dynamic cervical X rays and the management of neuropathic central pain

Results: The mean age was 42 ±11.39 years. The mean diagnostic delay was 48 months, with extremes ranging from 2 to 48 months. At one year, the mean motor ASIA score improved from 94 to 97 with $p<0.004$, the mean sensory ASIA score improved from 302 to 312 with $p<0.002$, the mean pain VAS improved from 8.44 to 4 with $p<0.0001$. The functional score improved in 65% of cases and stabilized in 35% with a $P\leq0.0001$. Radiologically, the Vaquero index improved in 91% of cases and stabilized in 9% with a $P\leq0.0001$, cyst length improved in 41% with a $p \leq0.001$ and overall improvement of the syringomyelic cavity in 76% of cases. Only one patient required repeat surgery.

Conclusion: Foraminal syringomyelia still causes neurological deficits in an active population due to delayed diagnosis, and appropriate multidisciplinary management is needed to improve prognosis and quality of life for these patients. Enter Content Presentation here

P89 - Forensic challenges in distinguishing head impact from fall in a surgically treated cranial trauma: a case report

Hadjazi Omar, Merad Yassine

University Hospital of SIDI BEL ABBES, ALGERIA

Background: In forensic pathology, distinguishing whether a head injury results from a blow or from a fall can be particularly difficult, especially when the circumstances of the event are unknown and when surgical intervention has altered the original lesions. Careful interpretation of autopsy findings and lesion biomechanics is therefore essential.

Methods: We report the case of a young man admitted to the neurosurgery department with severe traumatic brain injury and loss of consciousness. The patient underwent emergency neurosurgical intervention but died in the postoperative period. The forensic objective was to determine whether the cranial trauma resulted from a direct blow to the head or from a fall. No witnesses were available to clarify the circumstances of the event. In addition, the neurosurgical procedure was performed at the same site as the traumatic lesion, which complicated the autopsy assessment. The medico-legal analysis was based on the morphological examination of cranial and intracranial injuries, including the application of the hat brim line concept and the search for signs suggestive of sudden deceleration.

Results: Autopsy findings revealed cranio-encephalic traumatic lesions whose interpretation was limited by the prior neurosurgical intervention at the impact site. An additional difficulty was the presence of an unusually thin cranial vault, which may influence the biomechanics and severity of injury. The distribution of lesions and the presence of findings compatible with abrupt deceleration were considered more suggestive of a fall mechanism.

Conclusions: This case highlights the difficulties faced in forensic practice when differentiating between a blow and a fall in head trauma, particularly after surgical intervention. It underscores the importance of detailed intraoperative documentation and photographic recording of traumatic lesions by surgeons in suspicious cases, as these elements may significantly assist subsequent forensic interpretation.

P90 - Fourth ventricle surgery and the risk of intraoperative events: a series of 57 cases using the telovelar approach – transition from the transvermian to the telovelar route.

Belgacem Ibrahim, Chahad Mbarek, Djouadi Yasmine, Aboudjabel Mohamed, Mammerie Lila, Katia Ait Slimani; Ait Bachir Mustapha

Department of Neurosurgery, CHU Nedir Mohamed, Tizi Ouzou, Algeria

Introduction and objectives: Surgery for fourth ventricular tumors remains one of the most challenging procedures in posterior fossa neurosurgery because of the close relationship of these lesions with the brainstem, cerebellar peduncles, and lower cranial nerves. The transition from the traditional transvermian approach to the telovelar approach has improved surgical exposure while reducing cerebellar injury. The aim of this study was to analyze intraoperative events and postoperative complications associated with fourth ventricle tumor surgery through the telovelar approach.

Materials and methods: We conducted a retrospective study of 57 consecutive patients operated on for fourth ventricular tumors between late 2017 and June 2023. Clinical records, operative reports, and postoperative outcomes were reviewed. All patients underwent surgery through a median suboccipital craniotomy in the prone position using the telovelar approach. Particular attention was paid to intraoperative incidents and postoperative complications.

Results: The study included 36 males and 21 females. Histological examination showed a predominance of medulloblastomas, accounting for more than half of the cases, while ependymomas were identified in 16 patients. During surgery, eight episodes of hemodynamic instability were recorded, including two cases severe enough to require temporary interruption of the procedure. Postoperative complications included six infectious events, among them one case of purulent meningitis and four cases of pneumonia, three of which resolved with treatment. Neurological complications included one case of ocular deviation associated with apraxia, one case of transient cerebellar mutism/pseudobulbar syndrome, and two cases of transient facial nerve palsy. Four patients died within 30 days after surgery. Causes of death included meningitis-related sepsis, postoperative hematoma in two patients, aspiration pneumonia secondary to swallowing disorders, and acute postoperative hydrocephalus.

Conclusion: Recognition of intraoperative and postoperative complications associated with fourth ventricular tumor surgery is essential for improving patient outcomes. The telovelar approach provides effective access to the fourth ventricle while minimizing vermian injury. Optimal management requires close collaboration between neurosurgeons and neuroanesthesiologists, whose experience plays a key role in reducing morbidity and mortality.

P91 - Frailty outperforms age: which better predicts postoperative complications following spine surgery?

Majdouline Barkache, R.Benfredj, H.Kamoun, A.Mribah, I.Ksira

Department of Neurosurgery, Sahloul Hospital, Sousse, Tunisia

Background: As the population ages, spine surgeons increasingly operate on elderly patients with multiple comorbidities. While chronological age has traditionally been used to estimate surgical risk, frailty may better reflect physiological reserve and susceptibility to postoperative complications. This study compared the predictive value of frailty and age for adverse outcomes following spine surgery.

Methods: A retrospective study was conducted on 94 consecutive patients who underwent elective spine surgery between January 2021 and December 2023 at a tertiary neurosurgical center. Frailty was assessed preoperatively using the Modified Frailty Index (mFI-5). Patients were classified as frail (mFI-5 ≥2) or non-frail (mFI-5 <2). Postoperative complications occurring within 30 days were recorded. Multivariate logistic regression identified independent predictors of complications, and receiver operating characteristic (ROC) analysis compared the predictive performance of frailty and age.

Results: Thirty-one patients (33.0%) were classified as frail. The overall complication rate was 22.3% (21/94). Frail patients experienced significantly more complications than non-frail patients (41.9% vs. 12.7%, p=0.002), longer hospital stays (8.1±3.0 vs. 5.4±2.2 days, p<0.001), and higher reoperation rates (9.7% vs. 1.6%, p=0.04). Patients aged ≥70 years showed a higher complication rate than younger patients (31.8% vs. 18.8%), although this difference was not statistically significant (p=0.18). On multivariate analysis, frailty independently predicted postoperative complications (OR=3.54, 95% CI: 1.34–9.36, p=0.01), whereas age did not (OR=1.21, 95% CI: 0.49–2.96, p=0.67). Frailty demonstrated superior predictive accuracy (AUC=0.77) compared with age (AUC=0.60).

Conclusions: Frailty is a stronger predictor of postoperative complications than chronological age in spine surgery. Routine frailty assessment may improve preoperative risk stratification and perioperative decision-making.

P92 - Frame-based biopsy via the trans frontal extra ventricular contralateral approach: a rare indication for a rare lateropontine location, case report and review of the literature

Toufik Selmane, T. Selmane, Z. Abdellaoui, S. Chennaoui, Z. Fellag, D. Dergham, K. Bouaita

Neurosurgical specialized hospital, Cherchell 42002, Wilaya of TIPAZA, Algeria.

Background: The rare location of intrinsic lateropontine tumours requires the frame-based biopsy to be performed via the trans frontal extra ventricular contralateral route to avoid ventricles and the tentorium. This rare frame-based route was described by Amundson, Mc Girt and Olivi in 2005, and it is indicated only for lesions located lateral in the pons. Review of the literature show only 15 cases published globally.

Methods: We describe a case of 35-year-old man who presented conscious with a weakness of the 7th nerve, hearing loss and a mild hemiparesis. MRI shows a right lateropontine intrinsic tumour with a central heterogenous contrast enhancement and a slight mass effect on the contralateral half of the brain stem. The trans frontal extra ventricular contralateral route was adopted for the frame-based biopsy (we used the LEKSELL G-FRAME). Image acquisition was obtained by contrast CT scan after fixation of the frame to the skull. The target point was clearly chosen inside the enhanced tumour located lateral to the pons. No planning software was used for this case. The Sedan needle used measures 2.5 mm in diameter and 10 mm long window.

Results: The procedure was successfully achieved through a left burr hole located 01 cm behind the coronal suture and 06 cm lateral from sagittal suture, no obstacle was encountered, no CSF leak through during the sedan needle's progression, no operative bleeding. 06 tumour fragments were biopsied. No neurological worsening was observed, no complications to report Post operative CT scan show a clean trajectory of the sedan needle along the white matter with no ventricle breach and no bleeding in the biopsied target. The accuracy is estimated at 100%. The pathological study shows a grade1 glioma

Conclusion: The rare location of lateropontine intrinsic tumours can be reached and biopsied via a safe trans frontal extra ventricular contralateral approach.

P93 - Frame-based versus frameless brain needle biopsy: a comparative retrospective study

Emna Mzoughi, N.Nessib, A.Slimane, S. Bachraoui A.Belhadj, K.Ghedira, K.Abderrahmen, S.Bouali, I.Ben Said

Department of neurosurgery , National Institute of Neurology, Tunisia.

Background: Brain needle biopsy is a crucial procedure in neurosurgery giving inoperable patients a chance to receive an adapted treatment. Frame-based stereotaxy has been considered the reference standard for brain biopsies, however frameless stereotaxy has been overtaking the frame-based techniques lately. Our aim was to compare the safety and accuracy of both techniques to answer the question of whether one technique is superior to the other or not

Methods: A total of 59 patients with intra-axial brain tumors underwent CT-guided frame-based (32 patients) or frameless (27 patients) image-guided stereotactic brain biopsy between January 2025 and January 2026 at the neurosurgery department of the National Institute of Neurology of Tunis. We compared diagnostic yield, the occurrence of postoperative hemorrhage, neurological deficit, morbidity, and mortality.

Results: Diagnostic yield was 87.5% in the frame-based group versus 85.1% in the frameless group. Postoperative hemorrhage occurred in 6.25% of frame-based cases compared to 3.7% in the frameless group. Neurological deficit was observed in 3.1% of frame-based patients versus 0% in the frameless group. Morbidity rates were 6.25% and 11.1% respectively. Mortality was 0% in both groups. None of these differences reached statistical significance.

Conclusion: Frame-based and frameless brain needle biopsy are equivalent in terms of diagnostic yield, complication rates, morbidity, and mortality, with no statistically significant difference between the two techniques. The choice of approach should therefore be guided by institutional resources, equipment availability, procedural time, and radiation exposure considerations.

P94 - Framed stereotactic versus frameless navigation-guided ventriculoperitoneal shunt placement for idiopathic intracranial hypertension: a retrospective comparative study

Salim Bechraoui, N Nessib, F Sliti, A Slimane, E Elouni, A Belhadj, .M Naceur, W Nciri[2], R Hammemi[2], H Mechergui, K Ghedira, K Abderrahmen, S Bouali, I Ben Said, J Kallel

[1] Department of neurosurgery , National Institute of Neurology, Tunisia.

[2] Department of ICU, National institute of neurology, Tunisia.

[3] Bougatfa Hospital department of surgery, Tunisia.

Background: Idiopathic intracranial hypertension is a disorder characterized by elevated intracranial pressure, headache, and papilledema. It predominantly affects obese women and may lead to irreversible visual impairment if left untreated. Ventriculoperitoneal(VP) shunting is the standard procedure and accurate ventricular catheter placement is a critical determinant of VP shunt function and longevity . However, ventricular catheterization in IIH remains technically challenging because these patients typically present with markedly small, slit-like ventricles, rendering freehand catheter placement difficult and increasing the risk of shunt failure. Two image-guided techniques, frame-based stereotaxy and frameless neuronavigation, have been developed to improve placement accuracy over the standard technique, and are becoming more used in routine VP shunt placement. This study aims to compare the clinical and radiological outcomes of these two techniques.

Methods: We conducted a retrospective cohort study reviewing of IIH patients treated with a VP shunt placement using frame-based stereotaxy and those who underwent VP shunt placement using frameless neuronavigation between June 2021 and January 2026. Both pediatric and adult patients were included. Primary outcomes included proximal catheter placement accuracy on postoperative imaging, shunt revision and malfunction rates, operative time, and postoperative infection rates. Fundoscopic examination was performed preoperatively and postoperatively to assess changes in papilloedema as an indirect marker of intracranial pressure normalisation.

Results: A total of 25 patients were included across both groups (14 for framed VPS vs 11 for neuronavigation VPS). Proximal catheter placement accuracy was comparable between the framed stereotactic and frameless navigation groups, with no statistically significant difference in optimal catheter tip positioning. However, the frameless navigation group showed a lower shunt revision and malfunction rate and a reduced postoperative infection rate (within the first six months while offering a significantly shorter procedural time compared to the frame-based group. Fundoscopic assessment revealed improvement in papilloedema in both groups postoperatively, with no significant difference between the two techniques in the degree of fundoscopic normalisation.

Conclusion: Frameless neuronavigation-guided VP shunt placement has similar catheter accuracy comparable to frame-based stereotaxy while offering meaningful clinical advantages including shorter operative time, less x-ray radiation, lower revision rates, and reduced infection risk. These findings support frameless navigation as a safe and effective choice for VP shunt placement in both pediatric and adult patients. Larger prospective studies are needed to further validate these results in order to present definitive procedural guidelines.

P95 - Freeze it, bury it, or print it? redefining skull reconstruction after decompressive craniectomy

Firas Akrout, Rachdi M.A., Hdhili H, Bouzouita K, Achoura S, Chkili Ridha, Radhouen K.

Neurosurgery Department, Military Hospital of Tunis, Tunis, Tunisia

Background & objectives: Decompressive craniectomy is a life-saving intervention in refractory intracranial hypertension, yet the subsequent skull reconstruction phase — cranioplasty — carries its own significant morbidity and decision complexity. Three principal bone flap management strategies exist: cryopreservation, subcutaneous abdominal storage, and immediate replacement with custom alloplastic implants. Each carries distinct advantages, failure modes, and cost implications that remain incompletely compared in the literature. This review critically appraises current evidence to redefine optimal skull reconstruction strategy after decompressive craniectomy in the era of advanced biomaterials and 3D printing technology.

Methods: Narrative review of PubMed, Scopus, and Cochrane databases (2000–2024), including comparative cohort studies, systematic reviews, and biomaterial analyses evaluating autologous bone resorption rates, infection rates, cranioplasty failure, and patient-reported outcomes across all three management strategies.

Results & discussion: Cryopreservation: Storage of the autologous bone flap at −80°C preserves structural integrity and osteogenic potential while maintaining sterility. Autologous reimplantation demonstrates acceptable infection rates (3–8%) but carries significant bone resorption rates of 15–30%, particularly in younger patients and following prolonged storage intervals exceeding 12 months. Subcutaneous abdominal storage: Intraperitoneal or subcutaneous abdominal preservation maintains flap viability through vascularization but introduces donor site morbidity, patient discomfort, potential contamination, and technical complexity at reimplantation, with resorption and infection rates comparable to cryopreservation in most series. Custom alloplastic implants: PEEK and titanium patient-specific implants fabricated via 3D printing eliminate resorption risk entirely, offer superior anatomical precision, and demonstrate infection rates below 5% in recent series, at the cost of significantly higher fabrication expense and loss of biological reconstruction. Decision algorithm: Patient age, bone flap viability, anticipated reimplantation timing, institutional resources, and infection risk profile collectively determine optimal strategy selection.

Conclusion: No single reconstruction strategy universally outperforms the others. Custom alloplastic implants are redefining the benchmark for complex or high-risk cranioplasty, while autologous strategies retain relevance in resource-limited and straightforward settings. An individualized, evidence-driven decision algorithm is essential.

P96 - From cesarean section to cauda equina syndrome: an unexpected consequence of lumbar disc herniation decompensation

Mohamed Amine Hmida, R.Benfredj, B.Hajji, O.Hattab, I.Ksira

Department of Neurosurgery, Sahloul Hospital, Sousse, Tunisia

Introduction: Cauda equina syndrome (CES) is a rare neurosurgical emergency most commonly caused by a massive lumbar disc herniation. Although transient neurological symptoms may occur after spinal anesthesia, the onset of CES secondary to the decompensation of a previously asymptomatic lumbar disc herniation remains exceptionally uncommon. Early recognition and urgent surgical intervention are essential to prevent permanent neurological deficits.

Case presentation: A 30-year-old woman underwent cesarean section under spinal anesthesia. Shortly after the procedure, she developed severe low back pain associated with progressive bilateral lower-limb weakness, saddle hypoesthesia, and urinary dysfunction consistent with cauda equina syndrome. Emergency neurological assessment revealed motor deficits in both lower extremities and perineal sensory impairment. Lumbar magnetic resonance imaging (MRI) demonstrated a large lumbar disc herniation causing severe compression of the cauda equina. No evidence of epidural hematoma or anesthetic-related complication was identified. Management and Outcome The patient underwent urgent surgical decompression and lumbar discectomy within 8 hours of symptom onset. Postoperative recovery was favorable, with rapid improvement of motor, sensory, and sphincter functions. At follow-up, complete neurological recovery was achieved without residual deficits.

Discussion: The temporal relationship between spinal anesthesia and symptom onset suggests that neuraxial anesthesia may precipitate neurological decompensation in patients harboring an underlying lumbar disc herniation. Although rare, CES following spinal anesthesia should not automatically be attributed to anesthetic complications. Prompt MRI evaluation is mandatory to identify surgically treatable causes such as disc herniation or epidural hematoma. Early decompression remains the cornerstone of successful management.

Conclusion: Lumbar disc herniation should be considered in the differential diagnosis of acute neurological deterioration following spinal anesthesia. Rapid imaging assessment and emergent surgical decompression can result in complete neurological recovery when performed within the critical therapeutic window.

P97 - From conservative care to neuromodulation: defining the neurosurgical threshold in failed back surgery syndrome

Firas Akrout, Rachdi M.A., Kammoun T, Bouzouita K, Yedeas MD, Achoura S, Chkili Ridha, Radhouen K.

Neurosurgery Department, Military Hospital of Tunis, Tunis, Tunisia

Background & objectives: Failed back surgery syndrome (FBSS), defined as persistent or recurrent pain following lumbar spinal surgery, affects 10–40% of patients and represents one of the most challenging chronic pain conditions in clinical practice. Patients frequently navigate prolonged, fragmented care pathways before neurosurgical referral, while the optimal threshold for transitioning from conservative management to neurosurgical intervention — including neuromodulation — remains poorly defined. This review critically examines the clinical determinants guiding the neurosurgeon's role across the FBSS management continuum.

Methods: Narrative review of PubMed, Scopus, and Cochrane databases (2010–2024), including clinical guidelines, cohort studies, and randomized trials addressing conservative management duration, surgical revision indications, and neuromodulation candidacy in failed back surgery syndrome.

Results & discussion: Conservative care phase: Multimodal pharmacological management, structured physical therapy, and psychological support constitute first-line management, with most guidelines recommending a minimum 3–6 month trial before considering interventional escalation, provided no progressive neurological deficit is present. Diagnostic re-evaluation: Neurosurgical involvement should be triggered early for diagnostic clarification — distinguishing mechanical causes (pseudarthrosis, adjacent segment disease, recurrent stenosis) amenable to revision surgery from neuropathic or central pain mechanisms unlikely to benefit from further structural intervention. Revision surgery threshold: Revision is indicated only when a clearly identified, correctable mechanical etiology is confirmed on imaging; revision performed for unexplained or predominantly neuropathic pain shows consistently poor outcomes and should be avoided. Neuromodulation candidacy: Spinal cord stimulation demonstrates superior outcomes compared to repeat surgery or continued conservative management in predominantly neuropathic FBSS pain, with current evidence supporting earlier consideration — after failure of conservative care but before exhausting repeated unsuccessful interventional procedures. Multidisciplinary integration: Early, structured neurosurgical consultation within a multidisciplinary pain pathway reduces unnecessary revision surgery and shortens time to effective neuromodulation therapy.

Conclusion: The neurosurgical threshold in FBSS should be defined not by treatment failure exhaustion, but by early diagnostic clarification and appropriate stratification toward revision surgery or neuromodulation, optimizing outcomes and avoiding prolonged ineffective conservative trials.

P98 - From fever to tetraplegia: an unusual case of cervical brucellar spondylodiscitis

Mohamed Amine Hmida, H.Benselma, M.Benmessaoud, B.Hajji, C.Abdelileh, I.Ksira

Department of Neurosurgery, Sahloul Hospital, Sousse, Tunisia

Introduction: Cervical spondylodiscitis is a rare but potentially devastating infection involving the intervertebral discs and adjacent vertebral bodies. Although pyogenic bacteria are the most common causative agents, infection due to Brucella species remains uncommon, particularly in the cervical spine. Delayed diagnosis may result in severe neurological complications.

Case presentation: We report the case of a 37-year-old previously healthy woman diagnosed with cervical brucellar spondylodiscitis. She had no history of travel to endemic areas and no known contact with infected animals. The patient presented with progressive neck pain and intermittent fever evolving over two months, followed by heaviness of all four limbs and gait disturbance for one week. Clinical examination revealed a cervical spinal syndrome associated with tetraparesis and complete motor deficit of both lower extremities. Laboratory investigations demonstrated elevated inflammatory markers. Cervical magnetic resonance imaging (MRI) showed vertebral and paravertebral involvement with an epidural collection causing significant spinal cord compression. The diagnosis of brucellosis was confirmed by positive serological testing and bacterial culture obtained from a disc biopsy specimen. Brucellosis was identified as the underlying etiology of the cervical spondylodiscitis. Management and Treatment: Given the severity of neurological impairment and spinal cord compression, the patient underwent urgent surgical decompression. Postoperatively, targeted antimicrobial therapy consisting of doxycycline and rifampicin was administered for six months. Orthopedic management and intensive rehabilitation were also provided.

Conclusion: This case highlights the importance of considering Brucella species in the differential diagnosis of spondylodiscitis, even in the absence of typical epidemiological risk factors. Early recognition, prompt microbiological confirmation, and combined surgical and medical treatment are crucial to prevent irreversible neurological deficits and optimize functional outcomes.

P99 - From reconstruction to re-decompression: malignant cerebral edema following delayed cranioplasty

Mohamed Amine Hmida, C.Abdelileh, A.Guerrioui, K.Somrani, I.Ksira

Department of Neurosurgery, Sahloul Hospital, Sousse, Tunisia

Introduction: Malignant cerebral edema following cranioplasty is an exceptionally rare but potentially fatal complication. Its pathophysiology remains poorly understood and has been linked to impaired cerebrovascular autoregulation and paradoxical reperfusion injury after restoration of cranial integrity.

Case presentation: A 24-year-old man underwent decompressive craniectomy with bone flap removal for severe traumatic brain injury. Because of financial limitations, cranioplasty was delayed for two years. The patient remained neurologically stable during this period and subsequently underwent delayed cranioplasty. At the completion of the procedure, he developed acute anisocoria associated with severe hypertension and bradycardia, consistent with Cushing syndrome and rapidly progressive intracranial hypertension. Malignant cerebral edema was suspected. Management and Outcome: Emergency removal of the cranioplasty was immediately performed, restoring the decompressive cranial defect. The patient's condition stabilized following decompression, and further management was continued in the intensive care unit. The clinical presentation was consistent with malignant cerebral edema occurring immediately after cranioplasty.

Discussion: Although uncommon, malignant cerebral edema after cranioplasty represents a neurosurgical emergency. Sudden restoration of intracranial pressure dynamics and cerebral blood flow in patients with longstanding cranial defects may precipitate catastrophic brain swelling. Early recognition of warning signs and prompt surgical intervention are essential for preventing irreversible neurological injury.

Conclusion: Neurosurgeons should be aware of malignant cerebral edema as a rare but life-threatening complication of cranioplasty, particularly in cases of delayed reconstruction. Immediate removal of the implant may be lifesaving when acute intracranial hypertension develops intraoperatively or in the early postoperative period.

P100 - Gasperini syndrome of inflammatory etiology: an entity to be recognized

Imen Dammak[1], Jihene Ketata[1], Ines Cherif[2], Hichem Ammar[2]

[1] Department of Neurology, Sfax Military University Hospital, Tunisia

[2] Department of Neurosurgery, Sfax Military University Hospital, Tunisia

Introduction: Gasperini syndrome is a rare crossed brainstem syndrome, most commonly of vascular origin. Inflammatory etiologies, particularly demyelinating causes, are exceptional.

Case report: We report the case of a 43-year-old woman admitted for balance disorders, rotational vertigo, numbness of the lower third of the right hemiface, diplopia, right-sided hearing loss, and rapidly progressive paresthesia of the left hemibody. Neurological examination revealed multiple involvement of the right cranial nerves V, VI, VII, and VIII, as well as right visual field impairment. The clinical presentation was consistent with Gasperini syndrome. Brain MRI showed a signal abnormality involving the right middle cerebellar peduncle. The etiological workup supported an inflammatory demyelinating origin, compatible with multiple sclerosis.

Discussion: This case illustrates an exceptional cause of Gasperini syndrome. In young patients, multiple sclerosis is the most common inflammatory disease; however, multiple cranial nerve involvement is classically considered a red flag in this condition.

Conclusion: Awareness of Gasperini syndrome highlights the value of careful semiological analysis, which contributes to more accurate clinical localization of lesions and to optimal management according to the underlying etiology.

P101 - Giant basilar artery aneurysm: between ischemic risk and therapeutic challenge

Imen Dammak[1], Jihene Ketata[1], Ines Cherif[2], Hichem Ammar[2]

[1] Department of Neurology, Sfax Military University Hospital, Tunisia

[2] Department of Neurosurgery, Sfax Military University Hospital, Tunisia

Introduction: Giant basilar artery aneurysm, also referred to as a pseudotumoral arterial lesion, is an arteriopathy often discovered incidentally or after rupture. Ischemic stroke caused by an unruptured basilar artery aneurysm is rare.

Case report: We report the case of a 56-year-old male patient, smoker, with a history of arterial hypertension, type 2 diabetes mellitus, and obstructive sleep apnea treated with continuous positive airway pressure. He presented with the sudden onset of neurological deficits, including vertigo, gait instability, heaviness of the left hemibody, and blurred vision. Clinical examination revealed complete left hemiparesis, dysarthria, ataxia, and bilateral horizontal nystagmus, consistent with a brainstem syndrome. Arterial-phase contrast-enhanced brain CT showed marked vertebrobasilar dolichoectasia with pseudoaneurysmal dilatation measuring 20 mm in diameter. A spontaneously hyperdense thrombus of acute appearance was identified within the basilar trunk, causing approximately 70% stenosis and associated with significant mass effect on the medulla oblongata. The circle of Willis remained patent.

Discussion and conclusion: Our case illustrates a rare mode of presentation of basilar artery aneurysms, namely ischemic brainstem stroke. Three potential mechanisms have been described: thrombosis of the aneurysm itself, extensive thrombosis involving the parent vessel, or a compressive mechanism. In our patient, two of these mechanisms were clearly demonstrated on imaging. According to the literature, medical management based on antiplatelet therapy has shown favorable results for the secondary prevention of recurrent ischemic events. However, the vital prognosis may be threatened due to the progressive pseudotumoral nature of this arteriopathy.

P102 - Giant cystic supratentorial pilocytic astrocytoma in a young adult: a case report

Amina Oueslati, Ghedira K, Mzoughi E, Mechergui H, Abderahmene K, Bouali S, Kallel J

Department of Neurosurgery, National Institute of Neurology, Tunis, Tunisia

Introduction: Pilocytic astrocytoma (PA) is a World Health Organization (WHO) grade 1 glioma that predominantly affects children and young adults. It most commonly arises in the cerebellum, optic pathway, or brainstem. Supratentorial hemispheric localization in adults is rare and may pose diagnostic challenges due to its radiological resemblance to other cystic intracranial lesions.

Objective: To report a rare case of giant supratentorial pilocytic astrocytoma in an adult patient presenting with intracranial hypertension and clinical features suggestive of an underlying neurocutaneous disorder.

Case presentation: A 28-year-old woman with a history of surgical correction of juvenile scoliosis presented with symptoms of intracranial hypertension. Physical examination revealed multiple cutaneous nodular lesions distributed over the body, while neurological examination was unremarkable. Brain MRI demonstrated a large left parietal intra-axial cystic lesion measuring 75 × 50 mm, containing a small mural solid component and causing significant mass effect. The patient underwent gross total resection of the lesion. Postoperative recovery was uneventful, with complete resolution of symptoms. Histopathological examination confirmed a pilocytic astrocytoma (WHO grade 1).

Discussion: Adult supratentorial PA is an uncommon entity. Owing to its slow growth and nonspecific presentation, it may attain a large size before diagnosis. Radiologically, it typically appears as a cystic lesion with a mural nodule, although several low-grade tumors may mimic this pattern. Gross total resection remains the treatment of choice and is associated with excellent prognosis. In our case, the coexistence of cutaneous nodules and a history of juvenile scoliosis raised suspicion of an underlying neurocutaneous syndrome, although no definitive diagnosis was established.

Conclusion: Adult supratentorial pilocytic astrocytoma is a rare tumor with favorable outcomes following complete surgical excision. Associated systemic manifestations should prompt evaluation for an underlying genetic or neurocutaneous disorder.

P103 - Glioblastoma,, prognostic factors and surgical decisions, an expert opinion

Ezzat Abdelkhalek, Ahmed Ragab Abdelsalam, M.Sc., Ayman Abd Elraouf Abd Elghafar Elshazly MD, Ahmed Faisal Tobar MD, Ahmad Mohamed Abd Raheim Elsabaa MD, Sameh Roshdy Tawadros MD

[1] Military Medical Academy, Cairo, Egypt.
[2] Neurosurgery Department, Air Forces Specialized Hospital, Cairo, Egypt.
[3] Pediatric Department, Air Forces Specialized Hospital, Cairo, Egypt.
[4] Neurosurgery Department, Cairo University, Cairo, Egypt.
[5] Neurosurgery Department, El-Galaa Military Medical Complex, Cairo, Egypt.

Background & objective: Glioblastoma (GBM) represents 48% of primary malignant brain tumors and carries a dismal median survival rate of 12–15 months. This expert opinion reviews how evolving molecular classification systems shift therapeutic paradigms. It analyzes the intersection of tumor grading, independent clinical indicators, and surgical constraints to optimize patient management. Key Insights Molecular Diagnostics: The 2021 WHO Classification integrates entity-specific grading and mandatory molecular signatures. Isocitrate dehydrogenase (IDH)-mutant astrocytomas show superior median survival over IDH-wildtype tumors (31 months vs. 15 months). Homozygous deletions of $CDKN2A/B$ serve as molecular overrides, certifying a WHO Grade 4 designation even without traditional microvascular necrosis or proliferation. High-risk biomarkers include TERT promoter mutations, EGFR amplification, and +7/-10 chromosomal alterations. Prognostic Stratification: Holistic prognosis depends heavily on non-grading metrics. Favorable markers include an extent of resection (EOR) >78%, age 40 years, and a high Karnofsky Performance Status (KPS 70). Unfavorable outcomes correlate with advanced age (age65), low performance status (KPS 60), tumor size >5 cm, midline crossing, and recurrence. Proliferation indexes (Ki-67 labeling index 10%) act as critical metrics for malignancy. Surgical Strategy: Cytoreductive surgery remains the primary therapeutic avenue, though it bears high risks of neurological deficits, hematomas, and infection compared to stereotactic biopsy. Literature demonstrates no significant survival differences between debulking surgery and biopsy for tumors located in eloquent or inaccessible areas, small tumors with minimal deficits, or patients unfit for general anesthesia.

Conclusion: Adhering to the medical maxim "decisions are more important than incisions," this expert opinion recommends utilizing advanced diagnostic imaging (such as Magnetic Resonance Spectroscopy) to bypass invasive debulking surgeries in patients with predominantly negative prognostic factors. Instead, these high-risk individuals should navigate directly to specialized radiotherapy and chemotherapy protocols immediately following a diagnostic biopsy to preserve baseline quality of life.

P104 - Gorham-stout disease of the skull base: a diagnostic challenge and review of management strategies

Safa Ben Yagoub, Med Aziz Hermassi, Maila Bounemra, Aziz Bedioui, Ghassen Gader, Mouna Rkhami, Mohamed Badri, Kamel Bahri, Ihsen Zammel

Department of Neurosurgery, Ben Arous Trauma Center, Tunisia

Introduction: Gorham-Stout disease (GSD), also known as vanishing bone disease, is an exceptionally rare idiopathic skeletal disorder characterized by progressive osteolysis and replacement of osseous matrix by proliferating thin-walled vascular or lymphatic channels of benign histological origin. Its pathogenetic mechanisms remain incompletely elucidated, with hypotheses implicating aberrant angiogenic and osteoclastic signaling pathways. Although any skeletal segment may be affected, cranial localization is exceedingly uncommon, rendering diagnosis particularly challenging. We report a rare case of GSD involving the skull base, highlighting the diagnostic approach and management strategy employed.

Case report: A 23-year-old female presented with a progressively enlarging, asymptomatic left temporo-occipital skull defect evolving over two years. Neurological examination was unremarkable. Computed tomography demonstrated an extensive osteolytic lesion centered on the left mastoid bone, with contiguous involvement of the ipsilateral occipital bone and clivus, without associated soft tissue mass. MRI revealed medullary replacement by an infiltrative process exhibiting heterogeneous signal intensity, with post-contrast enhancement patterns suggestive of venolymphatic vascular proliferation. Systemic workup excluded metabolic, infectious, and malignant etiologies. Open bone biopsy was performed, demonstrating replacement of normal trabecular bone by proliferating thin-walled vascular channels with fibrous stroma, confirming the histopathological diagnosis of Gorham-Stout disease. Given the absence of neurological deficits, progressive intracranial extension, or cerebrospinal fluid leak, a conservative management strategy was adopted, incorporating clinical surveillance and pharmacological intervention with bisphosphonates. Clinical and radiological follow-up demonstrated disease stabilization with satisfactory outcomes.

Discussion: Cranial GSD is among the rarest skeletal localizations of this disorder, with fewer than 50 cases reported in the literature. Histopathological confirmation remains essential, as imaging findings overlap with fibrous dysplasia, lymphoma, and metastatic disease. No consensus treatment guidelines exist; reported strategies include surgical resection, radiotherapy, bisphosphonate therapy, and antiangiogenic agents, often employed in combination within a multidisciplinary framework.

Conclusion: Gorham-Stout disease of the skull base is a diagnostically challenging entity requiring a high index of clinical suspicion. Early histopathological confirmation and individualized multidisciplinary management are essential to preventing disease progression and optimizing long-term outcomes.

P105 - Halo traction combined with 540° fusion for realignment of high-grade cervical kyphosis after spondylodiscitis: a case report

Mohamed Ghorbel, G.Patet, C.Barrey

Spine Surgery Department of Pierre Wertheimer Hospital, Lyon, France

Background: Management of severe rigid cervical kyphosis, particularly in the setting of post-infectious ankylosis, remains challenging. Surgical correction often requires a combined anterior and posterior strategy to achieve adequate deformity release, restoration of sagittal balance, and stable fusion. The role and timing of halo traction, as well as the optimal surgical sequence, remain debated.

Methods: We report the case of a 23-year-old male with a history of intravenous drug use who developed cervical spondylodiscitis complicated by severe rigid cervical kyphosis. Preoperative imaging demonstrated a fixed deformity with near-complete ankylosis and a Cobb angle of 90°. The patient underwent preoperative halo-gravity traction for 48 hours followed by a staged 540° approach (posterior release, anterior reconstruction, and posterior instrumentation and fusion).

Results: Cervical alignment improved from a preoperative Cobb angle of 90° to 0° postoperatively. Correction was achieved through 17% reduction with halo traction and 83% through surgical correction. The patient was neurologically intact preoperatively but developed a transient right C5 palsy postoperatively, which showed progressive improvement during follow-up. No loss of correction or hardware failure was observed. At 3-month follow-up, clinical and radiological outcomes remained stable.

Conclusions: Halo traction combined with a circumferential 540° surgical approach appears to be a safe and effective strategy for the management of severe rigid cervical kyphosis secondary to spondylodiscitis. This combined strategy allows controlled deformity correction, complete release of ankylosis, and restoration of cervical alignment with satisfactory short-term outcomes.

P106 - Hemicorporal orthostatic tremor: when asymmetry challenges the diagnosis

Imen Dammak[1], Jihene Ketata[1], Ines Cherif[2], Hichem Ammar[2]

[1] Department of Neurology, Sfax Military University Hospital, Tunisia

[2] Department of Neurosurgery, Sfax Military University Hospital, Tunisia

Introduction: Orthostatic tremor is a rare movement disorder, usually bilateral and predominantly affecting the lower limbs. Hemicorporal forms are exceptional.

Case report: We report the case of a 50-year-old female patient who had presented for one year with a progressively worsening tremor, initially affecting the right upper limb and occurring only during writing. The tremor later extended to the ipsilateral lower limb, with symptoms appearing only in the standing position, improving during walking, and disappearing while sitting or lying down. Neurological examination revealed a unilateral right-sided postural tremor, with no associated sensorimotor deficit. Brain imaging showed no significant abnormalities. Electromyography performed in the standing position confirmed the orthostatic nature of the tremor. An extensive etiological workup was negative. The diagnosis of an atypical form of orthostatic tremor was retained. The patient showed marked improvement with gabapentin, 900 mg per day, combined with a low dose of clonazepam.

Discussion: This hemicorporal presentation is unusual and may raise several differential diagnoses, including lesional, parkinsonian, or functional causes. Electromyography remains the key investigation to confirm the type of tremor. The negative etiological workup supports the diagnosis.

Conclusion: Hemicorporal orthostatic tremor is a rare form of orthostatic tremor. It should be considered in any tremor that fulfills the semiological diagnostic criteria, even in the presence of marked asymmetry.

P107 - Hemorrhagic internal capsular metastasis from endometrial carcinoma: a rare case report

Khalil Ayadi, A Farikh, M Taallah, F Kolsi, B Kammoun, MZ Boudawara

Department of neurosurgery, Habib Bourguiba University Hospital, Sfax, Tunisia

Background: Brain metastases from endometrial carcinoma are rare and usually occur in advanced stages of the disease. Hemorrhagic cerebral metastases arising from endometrial cancer are exceptionally uncommon and may mimic other intracranial pathologies. We report a case of a hemorrhagic brain metastasis revealing intracranial dissemination of endometrial carcinoma.

Methods: A 52-year-old woman with a history of endometrial cancer presented with progressive heaviness and weakness of the right hemibody. Neurological examination revealed a mild right-sided motor deficit. Brain magnetic resonance imaging demonstrated a hemorrhagic lesion located within the left internal capsule, associated with surrounding edema. Given the atypical radiological appearance and the patient's oncological history, a stereotactic biopsy was performed to establish the diagnosis. Histopathological and immunohistochemical analyses were conducted.

Results: Histological examination of the biopsy specimen demonstrated metastatic adenocarcinoma consistent with the patient's known endometrial primary tumor. The diagnosis of a hemorrhagic brain metastasis from endometrial carcinoma was confirmed. The lesion's deep location within the internal capsule and its hemorrhagic nature posed diagnostic and therapeutic challenges. Following multidisciplinary discussion, the patient was referred for adjuvant oncological management, including consideration of radiotherapy and systemic treatment.

Conclusions: Although uncommon, brain metastasis should be considered in patients with a history of endometrial carcinoma who present with new neurological deficits. Hemorrhagic lesions in atypical locations may represent metastatic disease even years after the diagnosis of the primary tumor. Histopathological confirmation remains essential when imaging findings are inconclusive. Early recognition and multidisciplinary management are crucial to optimize outcomes in this rare clinical presentation.

P108 - Hemorrhagic neuroaspergillosis: a rare cause of intracranial hematoma

Fatma Ben Atig, Yassine Mokni, Yasmine Fouzri, Malek Bourgou, Kamel Ben Gayed

Department of neurosurgery, Regional Hospital Sadok Mkadem Djerba, Tunisia
ICU Department, Regional Hospital Sadok Mkadem Djerba, Tunisia

Introduction: Neuroaspergillosis is a rare but life-threatening fungal infection of the central nervous system caused by Aspergillus species. It predominantly affects immunocompromised patients and is characterized by marked angioinvasive properties that may lead to cerebral infarction, mycotic aneurysm formation, and intracranial hemorrhage. Presentation as a spontaneous intracerebral hematoma remains exceptionally uncommon and poses a major diagnostic challenge.

Case report: We report the case of a 79-year-old woman with a medical history of type 2 diabetes mellitus, hypertension, and chronic renal insufficiency, initially admitted for acute dyspnea related to decompensated heart failure with acute pulmonary edema. On the third day of hospitalization, the patient developed an altered level of consciousness with a Glasgow Coma Scale score of 10/15. Emergency brain computed tomography revealed a right frontal intracerebral hematoma surrounded by mild perilesional edema, associated with intraventricular hemorrhage and subarachnoid hemorrhage. The patient underwent urgent surgical evacuation of the hematoma with external ventricular drainage placement. Postoperatively, the patient showed progressive neurological improvement and was successfully extubated on postoperative day five. Histopathological examination of the surgical specimen demonstrated cerebral aspergillosis complicated by hemorrhage, consistent with angioinvasive neuroaspergillosis.

Conclusion: Neuroaspergillosis presenting as spontaneous intracerebral hematoma is an exceptionally rare entity with high morbidity and mortality. Its diagnosis is often difficult because clinical and radiological findings may mimic spontaneous hemorrhagic stroke. The angioinvasive nature of Aspergillus is responsible for vascular wall destruction and hemorrhagic complications. Early surgical management combined with histopathological diagnosis remains essential for appropriate therapeutic management and improved outcomes.

P109 - Hemorrhagic transformation after ischemic stroke : incidence, presentation, risk factors, and outcomes from a tunisian study of 843 patients

Ahmed Amine Daoued, M. Ghorbel, R. Ben Dhia, N. Daoussi, M. Mhiri

Department of Neurology, Fattouma Bourguiba University Hospital, Monastir, Tunisia

Acute ischemic stroke (AIS) is often complicated by hemorrhagic transformation (HT), which potentially worsens neurological outcomes and increases mortality. While well studied in thrombolyzed patients, HT characteristics and predictors in non-thrombolyzed real-world populations remain unknown. We retrospectively reviewed 843 patients admitted for AIS, to the Neurology Department of Fattouma Bourguiba, Monastir, Tunisia, between March 2017 and March 2025. Our study aimed to understand the presenting conditions of patients with HT, the incidence, clinical and radiological characteristics, risk factors and outcome. HT occurred in 5,5% of patients (n= 46). The mean age was 67,86±12,04 years. There was no sex predominance. Significant risk factors included atrial fibrillation (P<0,001), treatment by vitamin K antagonists (P=0,036), and high NIHSS at admission (P<0,001). HT was associated with increased mortality (19,6%) and poor functional outcomes. Nine patients developed HT after revascularization therapy (thrombolytic therapy). Nine patients died of HT. HT remains a frequent and serious complication of ischemic stroke, even outside thrombolysis contexts. Early recognition of risk factors may improve management and outcomes.

P110 - Hereditary nature of a rare ulnar–median anastomosis

Elleuch. Wafa[1 4], Mallek.A[1], Gahbich.F[3], Kolsi.F[3], Elleuch Mh[2 4]

[1] Physical medicine department, Military university hospital of sfax , Tunisia

[2] Department of Physical Medicine, Habib Bourguiba Hospital of Sfax, Tunisia

[3] Department of Neurosurgery, Habib Bourguiba Hospital of Sfax, Tunisia

[4] Research Unit for the Evaluation of Musculoskeletal Disorders (04/UR/08-07), University of Sfax, 3000, Tunisia

[5] General surgery Department , Military university hospital of sfax , Tunisia

Objective: To describe the electromyographic characteristics of the Riche-Cannieu anastomosis (ARC) and to investigate its hereditary nature based on an electromyographic study of two families. Method: This is a study involving patients with acroparesthesias. The presence of the Riche-Cannieu anastomosis (RCA) was systematically investigated by stimulating the ulnar nerve at the wrist and recording the response from the abductor pollicis brevis muscle. Families of the identified cases were invited for evaluation. A comprehensive electromyographic study, including both sensory and motor nerve conduction study , was performed in subjects who consented.

Results: Four cases presented this anastomosis. Only two families agreed to undergo electromyography (EMG). In all cases, an action potential was recorded from the abductor pollicis brevis muscle following stimulation of both the median nerve and the ulnar nerve at the wrist and at the elbow. A bifid waveform pattern was observed in some cases. No sensory abnormalities were detected.

Discussion: RCA consists of a connection between the deep branch of the ulnar nerve and the recurrent branch of the median nerve at the level of the hand. It is responsible for several clinical presentations depending on the proportion of muscle fibers innervated by the median or ulnar nerve. In particular, it results in dual innervation—by both the ulnar and median nerves—of the abductor pollicis brevis muscle. Previously, the Riche-Cannieu anastomosis (RCA) was described as a random event occurring during development. However, the process of innervation during development appears to be more organized, and anomalies previously attributed to chance may in fact have a hereditary origin.

P111 - Hydranencephaly in a term infant born to a mother with gestational diabetes a rare case report

Dahamou Mohamed, Elfarissi Mohammed Alamine, Khoulali Mohamed, Khay Hamid, Kada Amine, Elhilali Yassine

Neurosurgery Department, Mohammed VI University Hospital, Oujda, Morocco

Hydranencephaly is a rare congenital disorder of the central nervous system characterized by near-complete absence of the cerebral hemispheres, which are replaced by cerebrospinal fluid. It is believed to result mainly from intrauterine occlusion of the intracranial internal carotid arteries, although other etiological mechanisms have also been suggested. Typical neuroimaging findings include absence of the cerebral tissue supplied by the anterior and middle cerebral arteries, with relative preservation of the thalami, cerebellum, brainstem, falx, and portions of the temporal and occipital lobes. We report the case of an 8-month-old girl presenting with severe developmental delay and progressive macrocephaly. The patient was born at term to a mother with gestational diabetes. Brain imaging demonstrated near-complete replacement of the cerebral hemispheres by cerebrospinal fluid with preservation of posterior fossa structures, findings consistent with hydranencephaly. The patient received symptomatic treatment and multidisciplinary follow-up. Hydranencephaly remains an exceptionally rare condition associated with severe neurological impairment and poor prognosis. Neuroimaging plays a crucial role in establishing the diagnosis and differentiating this entity from severe hydrocephalus. Early diagnosis is important for supportive management and parental counseling.

P112 - Hypothalamic hamartoma presenting with gelastic epilepsy: a case report

Salim Bechraoui, N. Nessib, F. Sliti, A. Slimane, M Fahye, A. Belhadj, M. Naceur, K. Ghedira, K. Abderrahmen, S. Bouali, I. Ben Said, J. Kallel

Department of neurosurgery , National Institute of Neurology, Tunisia.

Introduction: Hypothalamic hamartomas are rare congenital malformations presenting with central precocious puberty, gelastic epilepsy and developmental retardation.

Case report: We report a case of an 3-year-old girl with recurring bloody vaginal discharge and gelastic epilepsy. Diagnosis of hypothalamic hamartoma was made on the basis of clinical findings and specific features on magnetic resonance imaging of the hypothalamic region. The patient underwent surgery and postoperative was uneventful.

Discussion: Hypothalamic hamartomas (HHs) are non-neoplastic, heterotopic nodules resembling the normal gray matter of the hypothalamus. HHs have become well known because of the characteristic symptoms of centraltype precocious puberty and gelastic seizures(GS). The accepted diagnostic criteria for GS include recurrent stereotyped fits of laughter, the absence of precipitating external factors, laughter inappropriate to context, laughter concomitant with other epileptic clinical manifestations, and ictal or interictal epileptiform electroencephalographic changes. Hypothalamic hamartomas (HHs) are non-neoplastic, heterotopic nodules resembling the normal gray matter of the hypothalamus. HHs have become well known because of the characteristic symptoms of centraltype precocious puberty and gelastic seizures(GS). The accepted diagnostic criteria for GS include recurrent stereotyped fits of laughter, the absence of precipitating external factors, laughter inappropriate to context, laughter concomitant with other epileptic clinical manifestations, and ictal or interictal epileptiform electroencephalographic changes.

Conclusion: Hypothalamic hamartoma frequently poses a diagnostic dilemma. Patients may exhibit rare symptoms of gelastic seizures and precocious puberty associated with neuropsychological and psychiatric symptoms. Surgical treatment is essential.The benefits of resection for HH in such cases outweigh the risk of surgical complications; however, the surgical approach needs to be carefully selected and performed with the utmost caution in order to minimize morbidity.

P113 - Idiopathic ventral thoracic transdural spinal cord herniation : a case report

Ala Eddine Chaabane, Iness Ferchichi, Mohamed Amine Hadj Taieb, Mehdi Darmoul

Neurosurgery Department, Fattouma Bourguiba University hospital, Monastir, Tunisia.

Background: Idiopathic Ventral thoracic transdural spinal cord herniation is a rare cause of progressive thoracic myelopathy, accounting for a small proportion of spinal cord disorders. Patients typically present with slowly progressive Brown-Séquard syndrome or spastic paraparesis. Acute neurological deterioration is exceptional and may delay diagnosis due to its resemblance to more common compressive or vascular spinal cord pathologies.

Case presentation: A 57-year-old patient presented with the sudden onset of spastic paraparesis associated with urinary incontinence. On admission, the patient was unable to stand or walk without assistance and complained of dorsal spinal pain. Neurological examination revealed an incomplete spastic paraparesis, graded 3/5, more pronounced in the right lower limb, with bilateral extensor plantar responses and diminished deep tendon reflexes. Magnetic resonance imaging (MRI) of the thoracic spine demonstrated ventral transdural spinal cord herniation at the T8–T9 level, with anterior displacement and tethering of the spinal cord against the posterior vertebral body. MRI also showed enlargement of the posterior epidural cerebrospinal fluid space and a T2-weighted intramedullary hyperintense signal extending approximately 3 cm at the T8–T9 level, consistent with compressive myelopathy.

Results: During hospitalization, the patient experienced spontaneous neurological improvement, with motor strength increasing to 4/5. Given the spontaneous clinical improvement and the absence of further neurological deterioration, conservative management with close clinical and radiological follow-up was favored over immediate surgical intervention. Neurological function progressively improved, with recovery of motor strength and gait following rehabilitation.

Conclusion: Although transdural thoracic spinal cord herniation is generally considered a surgically treatable condition, this case illustrates that acute presentations with spontaneous neurological improvement may occur. In carefully selected patients demonstrating early recovery and neurological stability, conservative management with close monitoring may represent a reasonable therapeutic option. Further studies are needed to better define the indications for surgery versus observation in this rare condition.

P114 - Immunoglobulin G4-related disease mimicking meningioma and dural metastasis: a case report

Mohamed Znazen, A. Hachicha, H. Belmabrouk

Department of Neurosurgery, University Hospital of Gabès, Tunisia

Background: Immunoglobulin G4-related disease (IgG4-RD) is a systemic condition characterized by immune-mediated inflammation and mass-forming lesions involving multiple organs, marked by infiltration of immunoglobulin G4 positive plasma cells and fibrosis often affecting various organs. Intracranial IgG4-RD is rare, and clinical data regarding presentation, imaging features course and to treatment response remain limited in the literature.

Methods: We herein report the clinical features of a case of IgG4-related inflammatory pseudotumor that radiologically mimicked meningioma and dural metastasis with a marked response to corticosteroid therapy.

Results: A 37-year-old man presented with 6 months histoty of progressive headaches with focal seizures dispite treatment of tow antiedpileptic drugs. However, he had no neurological deficit. Brain magnetic resonance imaging (MRI) revealed a lesion in the right parietal and perirolandic region, , mesuring 15*70 mm, iso-intense on both T1 and T2 weighted images. Diffusion-weighted imaging revealed areas of hypointensity within the lesion. Meanwhile, fluid-attenuated inversion recovery images showed prominent perilesional edema. On gadolinium-enhanced T1-weighted images, the lesion appeared well-defined and homogeneously enhanced. Further, a dural tail sign was observed. Based on these findings, a metastatic brain tumor or a malignant meningioma was initially suspected. Tumor resection could not be performed because of the strong adherence of the extra-axial lesion to the cerebral cortex. Given its location within an eloquent brain area, the surgical procedure was limited to obtaining biopsy samples for histopathological examination. Histopathological examination showed marked fibrosis and IgG4-positive plasma cell infiltration were observed, leading to the diagnosis of IgG4-RD. MRI was performed at six months after the prednisolone therapy, showing a significant decrease in the tumor size.

Conclusions: This case highlights the diagnostic challenge of IgG4-RD when it presents as a solitary dural-based mass mimicking meningioma or dural metastasis. Histopathological findings, including dense IgG4-positive plasma cell infiltration and fibrosis, confirmed the diagnosis. A multimodal diagnostic approach is essential for accurate diagnosis and appropriate management.

P115 - Impact of instrumented posterolateral fusion on spinopelvic alignment and adjacent segment evolution in isthmic spondylolisthesis

Rami Ben Mhenni, Guermazi Ahmed[2], Hamdi Kaziz[1], Mohamed Amine Hmida[2], Sadok Chtai[1], Mourad Mtaoumi[1], Mohamed Ali Khalifa[1], Karim Bouattour[1]

[1] Department of Orthopaedic Surgery and Traumatology, Sahloul University Hospital, Sousse, Tunisia.

[2] Department of neurosurgery, Sahloul University Hospital, Sousse, Tunisia.

Background: Isthmic spondylolisthesis induces global sagittal imbalance characterized by compensatory pelvic retroversion. While circumferential fusion is advocated for high-grade slips, the capacity of instrumented posterolateral fusion (PLF) alone to restore spinopelvic equilibrium and prevent adjacent segment disease (ASD) remains debated. This study evaluates postoperative spinopelvic parameter corrections and their clinical and adjacent-segment implications.

Methods: A retrospective monocentric cohort of 34 adults operated by instrumented PLF for symptomatic isthmic spondylolisthesis (CHU Sahloul, 2010–2024) was analyzed. Pre- and postoperative sagittal parameters — pelvic incidence (PI), pelvic tilt (PT), sacral slope (SS), and lumbar lordosis (LL) — were measured on standardized full-spine standing radiographs. Roussouly morphotype classification was applied. Functional outcomes (ODI, VAS, JOA) and ASD incidence were assessed at mean follow-up of 49 months. Statistical analysis used paired t-tests ($p < 0.05$).

Results: Mean preoperative PI was 58.6°, with Roussouly Types III–IV predominating (73.5%). Following PLF, PI remained stable (anatomical invariant), while significant positional corrections were achieved: PT decreased by 2.0° ($p < 0.001$), SS increased by 2.2° ($p < 0.001$), and LL gained 3.1° ($p < 0.001$). These radiological improvements correlated with significant functional gains: ODI decreased from 61.8% to 27.0%, VAS from 6.4 to 3.7 (both $p < 0.001$). Symptomatic ASD occurred in only 1 patient (3%), with radiological adjacent changes in 29% — well below published rates of 22–42%.

Conclusions: Despite addressing the posterior compartment exclusively, instrumented PLF achieves significant and reproducible spinopelvic realignment through sacral reorientation and lordosis restoration. This biomechanical correction effectively limits adjacent segment overload. Preoperative Roussouly profiling should guide surgical planning to optimize lordosis targets and minimize the risk of iatrogenic flat-back.

P116 - Implementing an endoscopic spine surgery program: strategies, challenges, and best practices

Radhouane Khaled, Affes A, Farhat S, Bouzouita K, Chkili R, Yedeas MD

Neurosurgery Department, Military Hospital of Tunis, Tunis, Tunisia

Introduction: Endoscopic Spine Surgery (ESS) is increasingly recognized as an effective minimally invasive alternative to conventional spine procedures, offering reduced tissue trauma, faster functional recovery, and lower postoperative complication rates. However, implementing an ESS program is challenging due to a steep learning curve, technological requirements, and financial implications.

Aim: To outline key strategies for successfully developing an ESS program in a clinical setting.

Methods: A comprehensive review of existing ESS programs was conducted, analyzing training protocols, equipment requirements, patient selection criteria, and institutional support. Case studies from institutions that successfully integrated ESS were examined to identify best practices and common obstacles.

Results: Structured, progressive surgical training (simulation, cadaveric practice, supervised clinical work) was associated with faster proficiency and safer early outcomes. Access to high-definition endoscopic systems and specialized instruments improved workflow and patient outcomes. Multidisciplinary collaboration strengthened perioperative coordination and patient selection. High initial costs and reimbursement limitations were major barriers, but strategic financial planning, phased equipment acquisition, and gradual expansion helped mitigate them. Centers with well-defined training pathways and staged implementation reported higher adoption rates and smoother integration.

Conclusion: Developing a robust ESS program requires careful planning, surgeon education, and sustained institutional support. Addressing early technical and financial challenges through structured training and phased implementation enables successful ESS integration with significant benefits for patients and healthcare providers. Future work should focus on standardizing training models and evaluating long-term clinical and economic outcomes.

P117 - Infected dermal sinus complicated by epidural abscess and intradural epidermoid cyst in a child: a two-stage surgical management

Aziz Abdelmoula, A. Ouesleti, E. Mzoughi, F. Sliti, N. Nessib

Neurosurgery Department of National Institute of Neurology, Tunis, Tunisia

Background: Congenital dermal sinus is a rare condition that may lead to severe spinal infections and associated inclusion tumors such as epidermoid cysts. Early recognition is essential to prevent neurological complications.

Methods: We report the case of a 4-year-old child presenting with spinal infection secondary to a dermal sinus. Clinical presentation, imaging, surgical management, and outcomes were analyzed.

Results: The patient presented with bilateral lumbosciatica and urinary disturbances. MRI revealed extensive extradural collections extending from D9 to L3 with spinal cord compression, associated with a dermal sinus. Initial surgery consisted of multilevel laminotomy, evacuation of epidural abscesses, and closure of the dermal sinus. Postoperative antibiotic therapy was administered. Follow-up imaging revealed persistent intradural collections. A second surgery was performed, which identified and allowed complete excision of an intradural epidermoid cyst. The postoperative course was favorable, with complete resolution of symptoms and no neurological deficit.

Conclusions: Dermal sinus can be complicated by both infectious and tumoral lesions. Persistent or recurrent collections should raise suspicion of an associated epidermoid cyst. A staged surgical approach combined with antibiotic therapy ensures optimal outcomes.

P118 - Informed consent and preoperative information in lumbar disc herniation surgery: a systematic review and proposal of standardized tools for clinical practice

Firas Ghahbich, F. Kolsi[1], J. Kammoun[2], K. Ayadi[1], B. Essid[1], S. Abdelmoula[1], S. Chaari[1], M. Taallah[1], M. Borni[1], B. Kammoun[1], W. Ben Amar [2], Boudawara MZ[1].

[1].Neurosurgery department , Habib Bourguiba Hopsital , sfax , Tunisia

[2].Legal Medicine department , Habib Bourguiba Hopsital , sfax , Tunisia

Background: Lumbar disc herniation (LDH) surgery is one of the most frequently performed neurosurgical procedures worldwide. Although considered safe and effective, it remains an invasive intervention requiring shared decision-making grounded in clear, and honest preoperative information. Current literature reveals significant heterogeneity in practices, frequent gaps in patient understanding, and a near-total absence of standardized information and consent documents — particularly in the Tunisian context. In Tunisia, the recently enacted Law No. 32-2024 on patient rights and medical liability has strengthened legal obligations regarding informed consent, yet no specific national guidelines exist for LDH surgery.

Methods: A systematic review was conducted following the PRISMA-Equity 2012 guidelines. Bibliographic searches were performed, covering the period from January 1, 2016 to November 31, 2025, using keywords related to lumbar disc herniation, discectomy, spine surgery, informed consent, patient information; documents specifically addressing preoperative information and/or informed consent in LDH surgery were retained.

Results: Out of 11,701 documents identified, six articles met the inclusion criteria. Analysis revealed four major findings: first, preoperative information is frequently insufficient and inconsistently delivered, with patients often holding partial or erroneous understanding of surgical objectives; second, a systematic gap exists between patient expectations (complete symptom resolution) and actual surgical goals (radicular pain relief); third, patients strongly express a need for written materials, and personalized communication adapted to their sociocultural context; and fourth, despite strong recommendations in the literature, no standardized information leaflet or consent form was identified in any of the retained publications.

Discussion: These findings confirm that informed consent in LDH surgery cannot be reduced to a signature. It constitutes a dynamic, continuous process grounded in shared decision-making, transparency, and bilateral communication. Modern decision-support tools, including predictive models, and culturally adapted communication strategies — represent promising avenues for improving decision quality and patient-surgeon alignment.

Conclusion: This review demonstrates that preoperative information and informed consent in LDH surgery remain heterogeneous and insufficiently structured, undermining the quality of patient decision-making. In response to these findings and in alignment with Tunisian Law 32-2024, this work proposes a structured patient information leaflet and an informed consent form — available in both French and Arabic — as practical tools to harmonize clinical practice, strengthen the patient-surgeon relationship, and reduce medicolegal risk.

P119 - Insights from two cases of post-tuberculous cervical spine deformity: choosing the right strategy for 360° reconstruction

Ahmed Amine Daoued, G. Elkahla, M.M Hadhri, A. Ben Nsir, M. Darmoul

Neurosurgery Depratement, Fattouma Bourguiba University Hospital of Monastir, Tunisia

Background: Cervical spine deformity following spinal tuberculosis is an uncommon but challenging condition. It may result from vertebral destruction, instability, progressive kyphosis, or post-infectious structural collapse. Management must balance infection control, neurological preservation, deformity correction, and spinal stability. In selected cases, circumferential surgery combining anterior and posterior approaches may be required to achieve adequate decompression, reconstruction, and fixation.

Methods: We report two cases of cervical spine deformity following tuberculoma/spinal tuberculosis. Clinical presentation, neurological status, radiological findings, deformity characteristics, and surgical strategy were analyzed. The choice of management was guided by the severity and flexibility of the deformity, presence of cord compression, anterior column destruction, spinal instability, and the patient's functional status.

Results: Both cases presented with post-tuberculous cervical deformity requiring individualized surgical planning. Conservative treatment alone was considered insufficient because of structural instability and risk of neurological deterioration. A 360° surgical strategy was selected, beginning with an anterior cervical approach to allow decompression, debridement when needed, correction of anterior column collapse, and reconstruction using graft or cage support. This was followed by posterior cervical fixation to reinforce correction, restore alignment, and maintain long-term stability. The combined approach provided circumferential control of the deformity and allowed safer correction in a complex post-infectious spine.

Conclusions: Post-tuberculous cervical spine deformity requires careful, case-by-case management. The decision between conservative treatment, isolated anterior or posterior surgery, and 360° reconstruction should be based on neurological status, deformity severity, anterior column integrity, and instability. In severe or unstable deformities, an anterior-to-posterior circumferential approach offers effective decompression, reconstruction, and durable stabilization. These two cases highlight the importance of individualized surgical planning in cervical deformities after spinal tuberculosis.

P120 - Intracerebral tuberculoma mimicking a brain tumor: diagnostic and therapeutic challenges.

Mokfi Ferial, Houari, Derbal, Delhoul, Guezzen, Melouk, Youcef, Benchhra, Sendjasni, Ouraghi, Mecifi, Fatah, Chaban, Batoul, Bekouche, Belhadj, Baghdouri, Mimouni, Banamara, Arab, Yahyaoui, Bellebna, Guerbouz.

Department of neurosurgery 1 Novembre Oran, Algeria.

Introduction: Intracerebral tuberculoma is an uncommon manifestation of central nervous system tuberculosis and remains a diagnostic challenge due to its nonspecific clinical and radiological features. It often presents as a space-occupying lesion and may closely resemble primary or metastatic brain tumors on neuroimaging.

Methods: We retrospectively reviewed the clinical records, radiological findings, surgical reports, histopathological results, and follow-up data of a patient diagnosed with intracerebral tuberculoma at our institution. Demographic information, presenting symptoms, laboratory investigations, imaging characteristics, treatment strategy, and clinical outcomes were analyzed.

Discussion: Intracerebral tuberculomas typically present with symptoms related to increased intracranial pressure, seizures, or focal neurological deficits, depending on lesion size and location. Magnetic resonance imaging commonly reveals ring-enhancing or nodular lesions associated with perilesional edema; however, these findings are not specific and frequently overlap with those of gliomas, metastases, abscesses, and other granulomatous diseases.Definitive diagnosis often relies on histopathological examination demonstrating granulomatous inflammation with caseous necrosis.

Conclusion: Intracerebral tuberculoma should be considered in the differential diagnosis of intracranial mass lesions, especially in tuberculosis-endemic areas. Radiological findings alone may be insufficient to distinguish tuberculoma from brain tumors. Histopathological confirmation remains essential in challenging cases, allowing timely initiation of appropriate antituberculous treatment and improved patient outcomes.

P121 - Intracranial abscess formation following undetected low-velocity penetrating head trauma: a case of a retained car key

Safa Ben Yagoub, Ghassen Gader, Farah Bahri, Fares Ferjani, Maila Bounemra, Med Aziz Hermassi, Aziz Bedioui, Mouna Rkhami, Mohamed Badri, Kamel Bahri, Ihsen Zammel

Department of Neurosurgery, Ben Arous Trauma Center, Tunisia

Introduction: Penetrating cranial injuries caused by retained foreign bodies are uncommon, accounting for roughly 0.4% of head traumas, yet carry significant diagnostic and therapeutic complexity. While high-velocity mechanisms such as gunshot wounds are well-documented, low-velocity injuries — resulting from sharp objects or interpersonal assaults — can produce equally severe complications, including intracranial abscess formation and neurological deficits, particularly when the foreign body remains undetected. We report a rare case of delayed diagnosis of a penetrating craniocerebral injury caused by a car key, complicated by intracranial abscess formation.

Case report: A 38-year-old male with no prior medical history presented to our emergency department one week after sustaining blunt head trauma during an assault. Initial evaluation by an independent practitioner had revealed only a small left temporal laceration; given preserved consciousness, absence of focal neurological deficits, and no reported loss of consciousness, the wound was sutured and the patient discharged without imaging. He re-presented with persistent cephalgia but denied fever, local inflammatory signs, or seizures. Laboratory workup was unremarkable. Brain CT demonstrated a hyperdense metallic foreign body within the left temporal region, accompanied by a hypodense perilesional area consistent with a chronic hematoma. Surgical exploration via temporal craniotomy revealed a car key that had traversed the temporal bone, with macroscopic dural disruption and approximately 20 cc of purulent exudate. Given the eloquent cortical location, abscess evacuation was performed without capsule resection to minimize the risk of postoperative seizures. Empirical broad-spectrum antibiotic therapy (cefotaxime and vancomycin) was initiated and subsequently narrowed to 21 days based on culture identification of Staphylococcus aureus. Postoperative recovery was uneventful. Follow-up CT at two weeks demonstrated a stable residual capsule with surrounding edema. The patient was discharged at three weeks on oral antibiotics and remains neurologically intact at three-month follow-up, with no epileptic episodes.

P122 - Intracranial acute subdural hematoma as a rare complication of spinal anesthesia for inguinal hernia repair: a case report

Roua Latrach, E. Elouni, N. Nessib, F. Sliti, A. Slimane, K. Ghedira, K. Abderrahmen, S. Bouali, I. Ben Said, J. Kallel

Department of neurosurgery , National Institute of Neurology, Tunisia.

Spinal anesthesia is a widely used technique in various surgical procedures due to its efficacy, safety profile, and relatively low incidence of complications. Although post-dural puncture headache is a well-recognized adverse event, intracranial subdural hematoma remains an exceptionally rare but potentially life-threatening complication. Prompt recognition and accurate diagnosis are essential to ensure timely management and prevent severe neurological sequelae. We report the case of a 64-year-old male with no significant past medical history who underwent inguinal hernia repair under spinal anesthesia. In the immediate postoperative period, he developed isolated headaches without associated nausea, vomiting, seizures, or focal neurological deficits. One week later, he was admitted to the emergency department with altered consciousness. An urgent cranial computed tomography (CT) scan revealed an acute right-sided subdural hematoma. The patient was immediately transferred to our epartment, where he underwent emergency surgical evacuation of the hematoma. Postoperative recovery was uneventful, with complete neurological improvement, and he was discharged home two days after surgery. This case highlights the importance of considering intracranial subdural hematoma in patients presenting with persistent or atypical headaches following spinal anesthesia. While rare, this complication should be suspected when headaches are severe, progressive, non-postural, or associated with neurological deterioration. Early neuroimaging is crucial whenever clinical suspicion arises, as prompt diagnosis and treatment can be lifesaving and lead to favorable outcomes.

P123 - Intracranial capillary hemangioma mimicking a high-grade glioma: a rare case report

Haifa Mechergui[2], S Bechraoui, S Bouali, N Chaouch, K Ghedira, J Kallel

[1] Department of neurosurgery , National Institute of Neurology, Tunisia.

[2] Bougatfa Hospital of Bizerte department of surgery, Tunisia.

Intracranial capillary hemangioma is an exceptionally rare benign vascular lesion that can closely mimic more common neoplastic entities on neuroimaging. We report the case of a 33-year-old patient with a history of cerebral thrombophlebitis one year earlier. During follow-up, brain imaging incidentally revealed a poorly defined left fronto-temporo-insular lesion, associated with contrast enhancement around the vessels of the Sylvian fissure. Neurological examination showed only memory impairment, with no language disturbance or motor deficit. Magnetic resonance spectroscopy suggested a high-grade glial tumor. The patient underwent awake brain surgery, which was performed without intraoperative incidents or postoperative complications. Intraoperatively, the lesion showed a gliomatosis-like appearance. It was firm, non-hemorrhagic, and encased the branches of the left middle cerebral artery. A subtotal resection was performed, leaving in place the fragments that were firmly adherent to the vascular structures in order to preserve vascular integrity. The postoperative course was uneventful. Histopathological examination ultimately revealed an intracranial capillary hemangioma. Although uncommon, intracranial capillary hemangioma should be included in the differential diagnosis of intracranial masses, as surgical resection allows both definitive diagnosis and curative treatment in most cases.

P124 - Intracranial empyemas: clinical-radiological diagnosis and therapeutic management – a retrospective study of 43 cases

Balkis Essid, F. Kolsi, K. Ayedi, F.Gahbiche, A.Farikh, M.Tallah, S.Abdelmoulah, M.Borni, S.Chaari, B .Kammoun, M.Z Boudawara

Department of Neurosurgery, Hbib Bourguiba University Hospital, Sfax , Tunisia

Background: Intracranial empyemas (EIC) are purulent extra-axial collections constituting neurosurgical emergencies with significant morbidity and mortality. Consensus on optimal management remains limited.

Methods: A retrospective descriptive study included 43 patients treated for intracranial empyema at Habib Bourguiba University Hospital, Sfax (January 2012 – December 2022). Data covered epidemiology, clinical presentation, radiology, bacteriology, treatment, and outcomes.

Results: Mean age was 32.35 years (range 6 months–73 years), with a strong male predominance (sex ratio 4.37). Median diagnostic delay was 12 days. Clinical findings included infectious syndrome (79.1%), intracranial hypertension (62.7%), focal deficits (48.8%), and seizures (30.2%). Bergman's triad was present in 23.3%. Subdural empyema (76.7%) was more common than extradural empyema (23.3%). The frontal region was most affected (61.5%). Cultures were positive in 42.5%, with Streptococcus species predominating (13/17). All patients received broad-spectrum antibiotics. Surgical evacuation was performed in 97.7% (craniotomy/craniectomy in 39, trepanation in 3). Favorable outcome was achieved in 86.0% (37/43). Unfavorable outcomes (14.0%) included refractory epilepsy (4 cases) and sequelar hemiplegia (2 cases).

Conclusions: Intracranial empyemas predominantly affect young males, often originating from locoregional infections. Prompt surgical evacuation combined with appropriate antibiotics yields favorable outcomes in over 85% of cases. Early diagnosis and treatment remain key prognostic factors.

P125 - Intracranial extension of recurrent dermatofibrosarcoma protuberans with fibrosarcomatous transformation: a rare case report

Egueh Fahye Mohamed, Khalil Ghedira, Nesrine Nessib, Firas Sliti, Khansa Abderrahmen

Department of Neurosurgery, National Institute Mongi Ben Hmida of Neurology, Tunis, Tunisia

Introduction: Dermatofibrosarcoma protuberans (DFSP), also known as Darier–Ferrand dermatofibrosarcoma, is a rare, locally aggressive soft tissue sarcoma characterized by a high rate of local recurrence but a low metastatic potential. Fibrosarcomatous transformation is an uncommon event associated with increased aggressiveness and a higher risk of recurrence and metastasis. Intracranial extension secondary to calvarial invasion remains exceptionally rare. We report a case of recurrent DFSP with fibrosarcomatous transformation and extensive cranial involvement.

Case report: A 52-year-oldman consulted our department for a subcutaneous swelling. He initially underwent wide local excision with skin graft reconstruction in 2012. Histological examination concluded to a Dermatofibrosarcoma protuberans. He underwent a re-excision for local recurrence in 2017 without adjuvant therapy .In 2024; he was admitted with a new right parieto-occipital recurrence arising within the skin graft. Brain magnetic resonance imaging revealed a large exophytic scalp mass centered over the interparietal region, associated with osteolytic destruction of both parietal bones, extra-axial intracranial extension, compression and displacement of the superior sagittal sinus, and an intramural venous thrombus. No cerebral parenchymal invasion or signal abnormalities were identified. Surgery was undertaken; however, only subtotal resection of the exophytic component could be achieved because of significant intraoperative bleeding. Histopathological examination demonstrated dermatofibrosarcoma protuberans with fibrosarcomatous transformation. Immunohistochemistry showed focal CD34 positivity, BCL2 negativity, and a Ki-67 proliferation index of 10%.

Discussion: Intracranial extension of DFSP is exceedingly uncommon and usually results from progressive local invasion through the calvarium after repeated recurrences. Fibrosarcomatous transformation, reported in approximately 10–15% of DFSP cases, is associated with increased cellularity, higher mitotic activity, and a less favorable prognosis. Complete surgical excision with negative margins remains the cornerstone of treatment but may be challenging in cases involving the skull and major dural venous sinuses. Adjuvant radiotherapy and targeted therapy with imatinib should be considered in unresectable or residual disease.

Conclusion: This case highlights the aggressive potential of recurrent DFSP with fibrosarcomatous transformation and emphasizes the importance of long-term surveillance, early management of local recurrence, and a multidisciplinary approach when cranial and intracranial extension is present.

P126 - Intracranial myeloid sarcoma complicating acute myeloid leukemia: a rare case of parieto-occipital localization

Safa Ben Yagoub, Med Aziz Hermassi, Maila Bounemra, Aziz Bedioui, Ghassen Gader, Mouna Rkhami, Mohamed Badri, Kamel Bahri, Ihsen Zammel

Department of Neurosurgery, Ben Arous Trauma Center, Tunisia

Introduction: Myeloid sarcoma is a rare extramedullary malignancy composed of immature myeloid precursor cells, most frequently associated with acute myeloid leukemia (AML), myelodysplastic syndromes, or myeloproliferative disorders. While cutaneous and soft tissue localizations predominate, intracranial involvement is exceptionally uncommon and represents a significant diagnostic challenge. Definitive diagnosis relies on immunohistochemical analysis, as clinical and radiological features often mimic other intracranial neoplasms. We report a pathologically confirmed case of cerebral myeloid sarcoma in a patient with a prior history of AML, highlighting the diagnostic pitfalls and surgical considerations inherent to this rare entity.

Case report: A 28-year-old Tunisian male with a known history of AML, diagnosed in 2019 and subsequently in remission following systemic chemotherapy, presented with progressive headaches and visual disturbances. Neurological examination revealed no focal motor deficits. Cranial MRI demonstrated a well-defined intra-axial lesion within the left parieto-occipital region, exhibiting signal characteristics suggestive of a high-grade neoplasm, though indistinguishable from primary brain tumors on imaging alone. Given the mass effect and diagnostic uncertainty, the patient underwent surgical resection. Gross total removal was achieved without postoperative neurological deterioration. Histopathological and immunohistochemical analysis of the surgical specimen confirmed the diagnosis of myeloid sarcoma, with tumor cells expressing myeloperoxidase and CD43, consistent with myeloid lineage differentiation.

Discussion: Intracranial myeloid sarcoma must be considered in any patient with a history of hematological malignancy presenting with a newly identified intracranial mass, even during apparent remission. Surgical intervention serves a dual purpose: alleviating mass effect and providing tissue for definitive histopathological diagnosis. Given the absence of established consensus guidelines, treatment strategies remain individualized, typically incorporating AML-directed systemic chemotherapy as the primary modality, with surgery and adjuvant radiotherapy reserved for selected cases.

Conclusion: Cerebral myeloid sarcoma is a rare but clinically significant complication of AML. Early neurosurgical involvement, combined with immunohistochemical confirmation and prompt reinitiation of systemic therapy, is essential to optimizing patient outcomes.

P127 - Intramedullary epidermoid cyst associated with split cord malformation: a two-case series

Mohamed Znazen, A. Hachicha, M. Taallah

Department of Neurosurgery, University Hospital of Gabès, Tunisia

Background: Diastematomyelia, also known as split cord malformation, is a rare congenital spinal dysraphism resulting from abnormal notochord development during embryogenesis. It is characterized by a sagittal division of the spinal cord into two hemicords, often separated by a fibrous or osseous septum. This anomaly may be associated with various neurological, orthopedic, cutaneous, and urological abnormalities. The coexistence of diastematomyelia and an intramedullary epidermoid cyst is exceptionally rare, particularly in adults.

Methods: We retrospectively reviewed the clinical presentation, radiological findings, surgical management, and postoperative outcomes of two adult female patients treated in our Neurosurgery Department. Both patients underwent spinal magnetic resonance imaging (MRI), followed by microsurgical resection of the intramedullary cyst and excision of the septum when indicated. Histopathological examination was performed in all cases.

Results: The patients were 41 and 48 years old and presented with chronic low back pain, bilateral lower-limb weakness, gait impairment, and urinary urgency. One patient also exhibited a lumbar cutaneous stigma in the form of a tuft of hair. Spinal MRI revealed dorsolumbar diastematomyelia associated with an intramedullary cyst located caudal to the split cord in the first patient. In the second patient, MRI demonstrated a type I diastematomyelia extending to the L1 level with a median osseous spur at L1–L2 separating two hemicords, associated with a low-lying tethered cord extending to L5 and an intramedullary cyst. Both patients underwent surgical excision of the osseous spur and complete microsurgical removal of the intramedullary cyst. Histopathological examination confirmed the diagnosis of epidermoid cyst in both cases. Postoperatively, both patients experienced significant neurological improvement, particularly in gait function, with no procedure-related complications.

Conclusions: Adult presentation of diastematomyelia is uncommon, and its association with an intramedullary epidermoid cyst is exceptionally rare. Magnetic resonance imaging is essential for diagnosis and surgical planning. Early surgical treatment, including removal of the septum and complete excision of the epidermoid cyst, may provide favorable neurological outcomes and prevent further neurological deterioration.

P128 - Intramedullary spinal cord schwannomas: clinical presentation, pathogenesis, and outcomes of 3 cases

Mohamed Amine Hmida, H.Benselma, S.Gallaoui, O.Hattab, I.Ksira

Department of Neurosurgery, Sahloul Hospital, Sousse, Tunisia

Background: Spinal schwannomas are common intradural extramedullary tumors, but a strictly intramedullary localization is exceptionally rare, representing only 0.3% to 1.5% of all intramedullary spinal cord tumors. We analyze the clinical characteristics, radiological findings, and surgical management of three patients treated in our department.

Material and methods: A retrospective review was conducted on 3 patients diagnosed and surgically treated for intramedullary schwannoma (IMS) out of a series of 43 spinal cord tumors managed at our institution.

Results: Case 1: A 45-year-old male presented with progressive gait impairment, pyramidal and posterior column syndromes, and urinary incontinence. MRI showed a well-defined IMS at D5-D6. Total resection via laminectomy was performed. At 17 years follow-up, the patient is completely paraplegic but maintains a normal social life. Case 2: A 51-year-old female presented with slow spinal cord compression and paraparresis. MRI demonstrated a tumor from D8 to D9. Following laminectomy and complete removal, she achieved a partial motor recovery at 2 years, requiring walking assistance. Case 3: A 52-year-old diabetic female presented with spastic paraparresis and sphincter disturbances. Total tumor removal was achieved via a D4-D6 laminectomy. At 4 years, the patient remains paraplegic and uses a wheelchair.

Discussion & conclusion: Since Schwann cells are normally absent within the central nervous system, histogenetic hypotheses include ectopic migration during neural tube closure or neoplastic transformation of glial cells. MRI is the gold standard for diagnostic guidance, typically showing a well-demarcated, contrast-enhancing fusiform lesion with peri-tumoral edema. Total surgical resection via posterior myelotomy is highly feasible due to the well-encapsulated nature of the tumor. However, the long-term functional prognosis depends heavily on the preoperative neurological status and the quality of the surgical clearing.

P129 - Intramedullary tuberculosis : a case report

Farah Bahri, G.Gader, S.Amara, F.Ferjani, M. Bounemra, F. Ben Atig, A.Hermassi, S.Ben Zekri, A.Bedioui, M.Rkhami, M.Badri, K.Bahri, I.Zammel

Department of Neurosurgery, Ben Arous Trauma Center, Tunisia

Background: Intramedullary spinal tuberculoma (IMT) is a rare manifestation of central nervous system tuberculosis, accounting for less than 2% of spinal tuberculous lesions. Its occurrence in patients with multidrug-resistant tuberculosis (MDR-TB) is exceptionally uncommon and presents significant diagnostic and therapeutic challenges. Although antituberculous chemotherapy remains the cornerstone of treatment, progressive neurological deterioration may necessitate surgical intervention. We report a rare case of thoracic intramedullary tuberculoma in a young patient with drug-resistant tuberculosis who developed acute paraplegia despite appropriate medical treatment.

Methods: A young patient with microbiologically confirmed drug-resistant pulmonary tuberculosis receiving third-line antituberculous therapy presented with rapidly progressive bilateral lower-limb weakness culminating in paraplegia. Spinal magnetic resonance imaging demonstrated an intramedullary dorsal lesion associated with marked spinal cord compression and edema. Given the severe neurological deficit and radiological progression despite ongoing antimicrobial therapy, the patient underwent microsurgical decompression and excision of the lesion. Clinical, radiological, operative, and histopathological findings were retrospectively reviewed.

Results: Gross total excision of the intramedullary lesion was successfully achieved. Histopathological examination confirmed intramedullary tuberculoma. The postoperative course was uneventful, with significant neurological recovery, progressive improvement in motor function, and subsequent intensive rehabilitation. Antituberculous therapy was continued postoperatively under infectious disease specialist supervision.

Conclusions: Intramedullary tuberculoma should be considered in the differential diagnosis of intramedullary spinal cord lesions in patients with tuberculosis, particularly in regions where the disease remains endemic. In cases of drug-resistant tuberculosis complicated by progressive neurological decline despite optimized medical therapy, early surgical decompression provides definitive diagnosis, relieves spinal cord compression, and may result in substantial neurological recovery. This case underscores the importance of timely multidisciplinary management integrating neurosurgery, infectious diseases, radiology, and rehabilitation.

P130 - Intraoperative CT 'ICT' guided pedicle screw placement in difficult situations.

Yasser Omar Riyad, Ahmed Ragab Abdelsalam, Ayman Abd Elraouf Abd Elghafar Elshazly, Ahmed Faisal Tobar, Ahmad Mohamed Abd Raheim Elsabaa, Sameh Roshdy Tawadros.

[1] Military Medical Academy, Cairo, Egypt.
[2] Neurosurgery Department, Air Forces Specialized Hospital, Cairo, Egypt.
[3] Pediatric Department, Air Forces Specialized Hospital, Cairo, Egypt.
[4] Neurosurgery Department, Cairo University, Cairo, Egypt.
[5] Neurosurgery Department, El-Galaa Military Medical Complex, Cairo, Egypt.

Pedicle screws have become the mainstay method for spine arthrodesis. They have the ability for a strong construct that allows to stabilize instabilities and correct deformities. However, they may become challenging in certain situations such as in osteoporosis, small pedicles and abnormally structured pedicles in cervical and thoracic vertebrae, deformities such as scoliosis and other factors. This is a retrospective cohort study. After the local ethics committee approval was acquired the database in the neurosurgery department in El Galaa Medical Military Complex was searched for patients underwent lumbo-sacral fixation using iCT between 2018 to 2020. Inclusion criteria were all patients underwent lumbo-sacral transpedicular fixations using iCT, any age group and any spine pathological conditions required lumbo-sacral instrumentations. Our results of 17 screws in 5 patients were placed with iCT have shown that iCT decreased the need of intraoperative screws repositioning and placed them with accuracy to size and site. ICT navigated pedicle screw insertion is a novel technique that is currently being implicated in spine surgeries. The results show the average operative time/min was 189±9.055 and the average blood loss/ml was 445±101.488.

P131 - Intraventricular colistin in the treatment of multiloculated hydrocephalus and ventriculitis: a report of two severe cases

Syrine Saadoun, Mohamed Maher Hadhri, Ghassen Belkahla, Iness Ferchichi, Nader Yahyaoui, Kais Maamri, Mehdi Darmoul.

Neurosurgery Department, Fattouma Bourguiba University hospital, Monastir, Tunisia.

Background: Ventriculitis associated with multiloculated hydrocephalus is a life-threatening condition requiring rapid infection control and cerebrospinal fluid (CSF) diversion. Intraventricular administration of antibiotics has emerged as an adjunctive strategy for treating severe ventriculitis, particularly when systemic therapy alone is insufficient. We report two cases of ventriculitis with multiloculated hydrocephalus successfully managed with intraventricular colistin.

Methods: We retrospectively reviewed two patients with ventriculitis complicated by multiloculated hydrocephalus who underwent external ventricular drainage and intraventricular colistin administration in addition to systemic antibiotic therapy. Clinical evolution, microbiological findings, CSF sterilization, and radiological outcomes were assessed.

Results: The first patient developed ventriculitis caused by Staphylococcus aureus, whereas the second had Acinetobacter baumannii ventriculitis. Following intraventricular colistin therapy, CSF cultures became sterile after 7 days in the first case and after 12 days in the second. Both patients showed progressive clinical improvement, resolution of the infection, and stabilization of their neurological status without recurrence during follow-up.

Conclusion: Intraventricular colistin may represent an effective adjunctive treatment for severe ventriculitis associated with multiloculated hydrocephalus, facilitating rapid CSF sterilization and favorable clinical outcomes. This approach may be particularly valuable in complex infections with limited response to systemic antibiotics. Larger studies are needed to better define the indications, efficacy, and safety of intraventricular colistin in neurosurgical infections.

P132 - Knowledge of tunisian neurosurgeons regarding the electronic medical record: a descriptive cross-sectional study

Firas Gahbiche, F. Kolsi[1], W. Elleuch [2], K. Ayadi[1], B. Essid[1], S. Abdelmoula[1], S. Chaari[1], M. Taallah[1], M. Borni[1], B. Kammoun[1], M. Zribi [3], W. Ben Amar [3], Boudawara MZ.

[1]. Neurosurgery department , Habib Bourguiba Hopsital , sfax , Tunisia

[2]. Physical Medicine and Rehabilitation, HMUS , sfax , Tunisia

[3]. Legal Medicine department , Habib Bourguiba Hopsital , sfax , Tunisia

Background: The Electronic Medical Record (EMR) is central to modern healthcare, enabling secure, structured management of patient data. In neurosurgery, where clinical information is particularly complex — encompassing imaging, operative reports, and detailed postoperative follow-up — mastery of the EMR is essential for both care quality and medico-legal security. In Tunisia, EMR integration across public hospitals remains heterogeneous, formal training is inadequate, and no dedicated regulatory framework governs its use. The 2024 Patient Rights Act (Law n°2024-32) provides only partial coverage of digital-specific issues, leaving a significant legal gap. This study aimed to assess the knowledge, practices, satisfaction, and medico-legal awareness of Tunisian neurosurgeons regarding the EMR.

Methods: A descriptive, cross-sectional study was conducted from January to March 2025 among physicians active in neurosurgery departments across Tunisian public hospitals, regardless of grade (university faculty, public health specialists, residents). Interns with fewer than three months of service were excluded. An anonymous structured questionnaire distributed via Google Forms covered four domains: EMR knowledge and functionalities, daily-use satisfaction, medico-legal awareness, and suggestions for improvement. Descriptive statistics were applied to qualitative variables.

Results: Of 85 neurosurgeons contacted, 50 responded (58.8%), representing 9 hospital centers nationwide. All participants (100%) were aware of the EMR and 94% used it daily, yet 68% had never received any formal training — most learning through peer observation or self-teaching. Only 32% were fully familiar with the system's advanced functionalities. The EMR was found to facilitate daily work by 88% of respondents, improve care quality by 70%, enhance act traceability by 76%, and reduce medical errors by 60%. However, 50% reported frequent technical failures or poor integration with imaging and pharmacy systems. On the medico-legal front, 60% acknowledged insufficient knowledge of their legal obligations (confidentiality, traceability, data security), 70% had never been informed of the consequences of improper EMR use, and all participants remained uncertain about the system's compliance with Tunisian personal data protection regulations. Ninety percent expressed strong interest in supplementary training.

Conclusion: Despite widespread EMR adoption, Tunisian neurosurgeons show significant gaps in advanced functional knowledge and medico-legal literacy. The absence of a specific regulatory framework, combined with inadequate formal training, constitutes a major professional risk in a high-stakes specialty. Targeted, continuous training programs and a dedicated legal framework are urgently needed. Future larger-scale studies with comparative analyses are warranted to better assess EMR impact on care quality and professional practice in Tunisian neurosurgery.

P133 - Left vertebral artery dissecting aneurysm presenting with cranial neuropathy treated by endovascular coil embolization: a case report

Nouraz Akter, Sakib Intesar, Shawnewas, Salauddin Ahmed, Sumon Rana, Shafiqul Islam

Dhaka Medical College Hospital, Bangladesh

Intracranial vertebral artery dissecting aneurysms (VADAs) rarely present with isolated cranial neuropathies due to brainstem ischemia or mass effect, requiring urgent vascular imaging for diagnosis. This case demonstrates that endovascular coil embolization offers a safe, effective, and low-morbidity treatment strategy for VADAs, achieving complete exclusion while preserving parent artery patency. The full case study, "Left Vertebral Artery Dissecting Aneurysm Presenting with Atypical Cranial Neuropathy Treated by Endovascular Coil Embolization," is available from the poster submission platform.

P134 - Lhermitte–duclos disease: a rare cerebellar disorder – report of two cases

Mohamed Znazen, A. Hachicha, M. Taallah, H. Belmabrouk,
Department of Neurosurgery, University Hospital of Gabès, Tunisia

Background: Lhermitte–Duclos disease (LDD), also known as dysplastic cerebellar gangliocytoma, is a rare benign hamartomatous lesion of the cerebellum characterized by abnormal enlargement and disorganization of cerebellar folia. First described in 1920, its etiology and pathogenesis remain incompletely understood. LDD typically presents during the third or fourth decade of life with symptoms related to intracranial hypertension, cerebellar dysfunction, and occasionally cranial nerve involvement. Magnetic resonance imaging (MRI) plays a pivotal role in establishing the diagnosis due to its characteristic radiological appearance. We report the clinical and radiological findings of two patients diagnosed with Lhermitte–Duclos disease.

Methods: We retrospectively reviewed the clinical presentation, neuroimaging findings, and diagnostic workup of two patients diagnosed with Lhermitte–Duclos disease at our institution. Clinical examination, computed tomography (CT), magnetic resonance imaging (MRI), and magnetic resonance spectroscopy findings were analyzed.

Results: The first patient was a 50-year-old man with no significant medical history who presented with progressive headaches, photophobia, and nausea evolving over four months. Neurological examination revealed a mild right vestibular syndrome. Brain MRI demonstrated bilateral cerebellar hemispheric lesions, hypointense on T1-weighted images and hyperintense on T2-weighted images, with moderate contrast enhancement of the right-sided lesion. Magnetic resonance spectroscopy showed elevated choline peaks and decreased N-acetylaspartate (NAA) levels in both lesions. The second patient was a 9-year-old girl who presented with holocranial headaches and recurrent vomiting of two weeks' duration, refractory to analgesic treatment. Neurological examination and fundoscopic assessment were unremarkable. Non-contrast brain CT revealed an ill-defined hypodense lesion within the right cerebellar hemisphere. Subsequent MRI demonstrated a right cerebellar lesion appearing hypointense on T1-weighted images and hyperintense on T2-weighted images, with mild peripheral contrast enhancement. Spectroscopy revealed a lipid peak and an increased choline-to-NAA ratio. In both cases, the combination of clinical and characteristic radiological findings strongly supported the diagnosis of Lhermitte–Duclos disease.

Conclusions: Lhermitte–Duclos disease is a rare benign cerebellar disorder characterized by abnormal cerebellar overgrowth and architectural disorganization. Clinical manifestations commonly include symptoms of intracranial hypertension, cerebellar dysfunction, visual disturbances, and cranial nerve deficits. MRI remains the cornerstone of diagnosis, demonstrating characteristic imaging features that may obviate the need for invasive procedures. Recognition of this rare entity is essential for accurate diagnosis and appropriate management.

P135 - Limited versus extensive correction in adult degenerative scoliosis: outcomes of a symptom-driven surgical strategy

Emna Elouni, Atef Ben Nsir, Mehdi Darmoul

Neurosurgery Departement, University Hospital of Fattouma Bourguiba, Monastir, Tunisia

Background: Adult degenerative scoliosis (ADS) is a complex spinal deformity often associated with significant functional disability. Extensive corrective surgery may carry high morbidity, particularly in patients with predominant radicular symptoms. Recent trends in spine surgery favor individualized, symptom-driven approaches rather than complete radiological correction.

Methods: We report a case series of three patients aged 35–64 years presenting with chronic lumbosciatica, neurogenic claudication, and functional impairment secondary to ADS. Surgical strategy was based on clinical symptom distribution and spino-pelvic alignment assessed using the SRS–Schwab classification. Patients underwent targeted decompression and short-segment interbody fusion (TLIF/PLIF) at symptomatic levels without full curve correction. Radiological assessment included Cobb angle, pelvic incidence–lumbar lordosis (PI–LL) mismatch, and sagittal vertical axis (SVA). Clinical outcomes were evaluated using the Visual Analog Scale (VAS) and Oswestry Disability Index (ODI).

Results: All patients showed marked clinical improvement. VAS scores decreased from 7–9/10 preoperatively to 1–2/10 postoperatively, and ODI improved from 55–68% to 18–22%. Radicular pain and neurogenic claudication resolved or significantly improved in all cases. Radiological follow-up demonstrated partial correction of coronal deformity, improvement in PI–LL mismatch, and reduction in sagittal imbalance. No major perioperative complications occurred, with blood loss ranging from 120–200 mL. All patients regained independent ambulation with improved walking capacity.

Conclusion: Selective, symptom-guided short-segment fusion may represent an effective alternative to extensive deformity correction in carefully selected patients with ADS. Functional improvement can be achieved without full radiological realignment, supporting a shift toward individualized, less invasive strategies in adult spinal deformity surgery.

P136 - Long-term academic attainment and school re-entry outcomes following pediatric neurosurgery: challenges and perspectives in tunisia

Emna Elouni, Roua Latrach, Nessrine Nessib, Firas Sliti, Myriam Naceur, Slimane Abdelhafidh, Imed Ben Said, Jalel Kallel

Neurosurgery Departement, National Institute of Neurology, Tunis, Tunisia

Background: Increasing survival rates following pediatric neurosurgical interventions have shifted attention toward long-term functional outcomes, including educational achievement and successful school reintegration. In Tunisia, where specialized neuropsychological and educational support services remain limited, the impact of pediatric neurosurgical diseases on academic attainment is poorly documented.

Methods: A narrative review of the literature was conducted, focusing on long-term educational outcomes in children treated for brain tumors, hydrocephalus, epilepsy, traumatic brain injury, and congenital central nervous system malformations.

Results: Published studies indicate that academic performance after pediatric neurosurgery depends on the underlying pathology, treatment modalities, and access to rehabilitation services. Children treated for brain tumors and severe traumatic brain injuries are at increased risk of cognitive impairment, learning difficulties, and need for specialized educational support. In Tunisia, delayed neuropsychological assessment, limited rehabilitation resources, prolonged school absenteeism, and insufficient coordination between healthcare providers and educational institutions represent major barriers to successful school reintegration. Family support and early multidisciplinary follow-up appear to be key determinants of favorable academic outcomes.

Conclusions: Academic attainment and school re-entry are important but underrecognized aspects of recovery after pediatric neurosurgery in Tunisia. Establishing multidisciplinary follow-up programs, strengthening collaboration between medical and educational sectors, and implementing standardized school reintegration strategies may improve long-term quality of life and educational outcomes. Prospective studies are needed to better characterize these issues in the Tunisian population.

P137 - Lumbar intradural spinal abscess in a 19-year-old patient: a rare case report

Dahamou Mohamed, Elfarissi Mohammed Alamine, Khoulali Mohamed, Khay Hamid.

Neurosurgery Department, Mohammed VI University Hospital, Oujda, Morocco

Introduction: Intradural spinal abscesses are extremely rare infections compared to epidural abscesses because of the anatomical isolation of the intradural space. Early diagnosis is essential to avoid neurological complications.

Case presentation: A 19-year-old male with no significant medical history presented with persistent low back pain for two months associated with fever. Clinical examination revealed lumbar spinal syndrome without neurological deficit. Laboratory tests showed an inflammatory syndrome with leukocytosis (20,000/mm³) and elevated CRP (170 mg/L). Cerebrospinal fluid analysis demonstrated inflammatory findings, while cultures were negative. Spinal MRI revealed an intradural abscess at the L4–L5 level. The patient received intravenous antibiotic therapy with Ceftriaxone and Metronidazole for 21 days, with favorable clinical evolution. Follow-up MRI confirmed complete resolution of the lesion.

Conclusion: Lumbar intradural abscess is a rare condition. MRI plays a key role in diagnosis, and early antibiotic treatment may lead to good clinical and radiological outcomes.

P138 - Lumbosacral dermal sinus associated with recurrent meningitis and tethered cord syndrome: a case report

Abdelhamid Derbale, Mokfi, Mimouni, Benamara, Arab, Fardji, Chenane, Belabaci, Benkhlifa, Guerbouz .

University Hospital of Oran, Algeria

Background: Spinal dermal sinus is a rare form of closed spinal dysraphism resulting from incomplete separation of the cutaneous ectoderm from the neural tube during embryogenesis. Although uncommon, it may lead to severe infectious complications, including recurrent meningitis, and may be associated with tethered cord syndrome, resulting in neurological and urological dysfunction. Early diagnosis and surgical treatment are essential to prevent irreversible sequelae.

Methods: We report the case of a 9-month-old infant admitted for recurrent episodes of bacterial meningitis. Urological assessment revealed urinary dysfunction characterized by a post-void residual volume on bladder ultrasonography. Physical examination identified a lumbosacral cutaneous stigma suggestive of a dermal sinus. Spinal magnetic resonance imaging (MRI) demonstrated a dermal sinus tract associated with a low-lying tethered spinal cord. The patient underwent microsurgical complete excision of the dermal sinus tract and spinal cord detethering.

Results: Surgery was performed without complications. Intraoperative findings confirmed the dermal sinus tract and tethered cord syndrome. Histopathological examination was consistent with a dermal sinus tract. No further episodes of meningitis occurred during follow-up. Progressive improvement in urinary function was observed, with regression of the post-void residual volume on follow-up ultrasonography. No new neurological deficits were recorded postoperatively.

Conclusions: Spinal dermal sinus should be considered in infants presenting with recurrent meningitis and lumbosacral cutaneous stigmata. MRI plays a pivotal role in identifying associated tethered cord syndrome. Early microsurgical excision and spinal cord detethering provide effective prevention of recurrent infections and may lead to significant improvement in urinary dysfunction and long-term neurological outcomes.

P139 - Malformation of the cervical-occipital hinge with diplopia

Salim Bechraoui, N Nessib, A Slimane, H Mechergui, F Sliti, M Fahye, A Belhadj, M Naceur, K Ghedira, K Abderrahmen, S Bouali, I Ben Said, J Kallel.

[1] Department of neurosurgery , National Institute of Neurology, Tunisia.

[2] Bougatfa Hospital department of surgery, Tunisia.

Introduction: Chiari I malformation is a congenital, neurological condition that is characterized by defects of the skull base resulting in herniation of the cerebellum through the foramen magnum into the cervical spinal canal.Because the condition can result in visual symptoms, patients will often search for answers from their eye care providers. Diplopia is not frequently associated with Arnold-Chiari I malformation.

Material and methods: We report the case of a 16-year old boy,without pathological history, who reports sudden onset of an horizontal binocular diplopia without traumatic context.On examination,the patient presented a right convergent strabismus and a gaze-evoked nystagmus.Magnetic resonance imaging (MRI) showed malformation of the cervico-occipital hinge with ptosis of the tonsils without hydrocephalus nor syringomyelia. The patient underwent a suboccipital craniectomy which resulted in lessened nystagmus, diplopia regression and improved symptoms.

Discussion: The majority of patients with Chiari I malformation have an onset of symptoms in the second or third decade of life. Most commonly, a suboccipital headache that worsens with Valsalva maneuver is present. Visual symptoms include retro-orbital pain, flashing lights or floaters, blurred vision, photophobia, diplopia, transient vision loss, and peripheral vision loss. Objective evidence is often lacking in these patients;however, horizontal or vertical nystagmus is present in up to 45% of those with Chiari I malformation.Surgery has proven to be an effective and safe method to treat symptomatic Chiari I malformation. After analysising all published cases,we believe that acute acquired esotropia in Chiari I patients should be considered an indication for primary surgical suboccipital decompression rather than strabismus surgery. Although no cases of comitant esotropia in Chiari I malformation successfully treated with a single strabismus procedure have yet been reported,we cannot exclude that extraocular muscle surgery alone could be sufficient in some cases. There are no available guidelines addressing the appropriate treatment for this esotropia.The data derived from previous reports suggest that esotropia tends to recur,at least in some patients,after strabismus surgery if decompression is not performed.These recurrences tend to resolve after neurosurgical decompression. Therefore,suboccipital decompression is a safe procedure which,contrary to strabismus surgery,seems to treat the underlying process of comitant esotropia in patients with Chiari I malformation with usually minimal postoperative complications (nausea/vomiting/headache).This is why,except in cases of complex craniocervical junction abnormality,we would recommend primary suboccipital decompression to treat comitant esotropia in patients with Chiari I malformation.

Conclusion: Acquired esotropia,often in association with other eye movement abnormalities,may be an early sign of Arnold-Chiari I malformation.Neurosurgical suboccipital and upper cervical decompression may lead to improvement or resolution of diplopia.

P140 - Management and outcomes of orbital cavernous hemangioma: a 14 patients' series.

Sara Belmokhtar, Chennaoui, Abdellaoui, Mati, Bouaita.

EHS Cherchell, medical faculty of Blida, University Saad Dahlab of Blida, Algeria

Orbital cavernous hemangioma, now more accurately termed cavernous venous malformation (CVM), is the most common benign orbital lesion in adults, accounting for roughly 4.5–7.4% of all primary and secondary orbital tumors. It typically affects women in the fourth and fifth decades of life.

Clinical presentation: this lesion often presents as a slowly progressive intraorbital mass causing painless, nonpulsatile exophthalmos that may eventually impair visual acuity or ocular motility. Imaging: Magnetic resonance imaging (MRI) and computed tomography (CT) are the main diagnostic tools, with MRI preferred to limit radiation exposure and to better characterize lesion location and relationships. Surgery: Because these lesions are well encapsulated, complete surgical excision is usually feasible and can offer excellent functional and cosmetic results. Pathology: circumscribed lesions composed of dilated vessels ; These tumors were well-circumscribed with an outer fibrous capsule of variable thickness. Within the substance of the tumor, there was a quasiuniformity of large (cavernous) spaces. The present study reports a single-department experience with the management of orbital cavernous hemangioma in 14 patients, focusing on clinical presentation, imaging findings, surgical approaches, histopathological features, and postoperative outcomes.

P141 - Management of cystic craniopharyngiomas: surgical strategies and clinical outcomes

Soumia Benallag, T. Selmane, N. Baz, Z. Abdellaoui, K.Bouaita

Neurosurgery departement EHS Cherchell, Blida faculty of medecine, Algeria.

Background: Cystic craniopharyngiomas are benign epithelial tumors arising in the sellar and suprasellar region. Despite their benign histology, they present significant therapeutic challenges because of their proximity to critical neurovascular structures, including the optic apparatus, hypothalamus, and pituitary gland. The cystic component often contributes substantially to mass effect and symptom progression, requiring individualized management strategies.

Methods: We conducted a retrospective analysis of patients treated for cystic craniopharyngiomas at our institution. Clinical presentation, radiological characteristics, surgical approach, extent of cyst decompression, postoperative outcomes, and recurrence patterns were evaluated. Treatment strategies included microsurgical resection, endoscopic cyst fenestration, cyst drainage procedures, and adjuvant therapies when indicated.

Results: Visual disturbances, headaches, signs of raised intracranial pressure, and endocrine dysfunction were the most common presenting symptoms. Surgical management achieved effective cyst decompression and significant reduction in tumor volume in the majority of patients. Improvement in visual symptoms and intracranial hypertension was observed in most cases following treatment. In selected patients, subtotal resection combined with cyst drainage provided satisfactory long term tumor control while minimizing hypothalamic and pituitary injury. Recurrences were primarily related to re-expansion of the cystic component and were successfully managed through repeat drainage, endoscopic procedures, or adjuvant radiotherapy. Treatment related morbidity was mainly represented by endocrine disturbances and transient electrolyte imbalances.

Conclusion: Cystic craniopharyngiomas remain challenging lesions requiring multidisciplinary management. Effective cyst decompression, preservation of critical structures, and individualized treatment strategies can achieve favorable long term outcomes while reducing treatment related morbidity. Careful radiological surveillance remains essential because of the risk of cyst recurrence.

P142 - Management of intraventricular tumors: from diagnosis to resection:

Ferial Mokfi, Derbal, Houari, Mimouni, Banamara, Arab, Guezzn, Belahoul, Ouraghi, Belebna, Guerbouz R.

Department of neurosurgery 1 Novembre Oran, Algeria.

Intraventricular meningiomas are uncommon neoplasms originating within the ventricular system of the brain, constituting a rare subset of central nervous system tumors. Their unique location poses diagnostic challenges, and manifestations is imperative for effective Management.

Methods: We report on a 45-year-old with a lateral ventricle with surrounding edema treated in our department of neurosurgery ehu d'oran.

Results: In the present case, the tumor was successfully approached through a tailored surgical corridor that allowed adequate exposure while minimizing cortical and subcortical injury. Careful microsurgical dissection enabled maximal safe resection with preservation of the surrounding neurovascular structures. Postoperative imaging confirmed satisfactory tumor removal, and the patient's clinical outcome was favorable

Conclusion: Lateral ventricular tumors are rare lesions that pose significant diagnostic and surgical challenges. Detailed preoperative planning, knowledge of ventricular anatomy, and meticulous microsurgical techniques are essential for achieving maximal safe resection while minimizing morbidity. Gross total resection, when achievable, remains the cornerstone of treatment and is associated with favorable clinical outcomes. Continued radiological follow-up is recommended to monitor for recurrence and guide further management.

P143 - Management of thoracolumbar transdiscal fracture and severe central canal stenosis complicating ankylosing spondylitis : a case report

Ala Eddine Chaabane, Ahmed Daoued, Mohamed Maher Hadhri, Ghassen Belkahla, Mehdi Darmoul

Neurosurgery Department, Fattouma Bourguiba University hospital, Monastir, Tunisia.

Background: Spinal fractures are a well-recognized complication of advanced ankylosing spondylitis (AS), resulting from a rigid ankylosed spine and altered biomechanics. Although cervical fractures are the most frequently encountered, thoracolumbar transdiscal fractures associated with Andersson lesions remain uncommon and represent a particularly unstable entity with a high risk of neurological deterioration. Their optimal surgical management remains challenging.

Case presentation: We report the case of a patient with long-standing, poorly controlled ankylosing spondylitis who presented with progressive cervical pain, gait disturbance, and postural instability. Neurological examination demonstrated a spastic quadripyramidal syndrome without sensory deficits. Magnetic resonance imaging revealed extensive structural changes related to advanced AS, including two distinct sites of compressive myelopathy. At the craniovertebral junction, there was atlantoaxial instability with vertical subluxation and an erosive peri-odontoid inflammatory pannus causing C1–C2 spinal cord compression. At the thoracolumbar junction, MRI demonstrated an Andersson lesion at D12–L1 complicated by an unstable transdiscal fracture extending to the posterior elements. Retropulsion of the posterosuperior wall of L1, associated with posterior epidural inflammatory changes and ossification of the ligamentum flavum, resulted in severe central canal stenosis and spinal cord compression.

Results: Given the severity of the thoracolumbar instability and cord compression, surgical management was prioritized at this level. The patient underwent posterior decompression by thoracolumbar spinolaminectomy with excision of the ossified ligamentum flavum and long-segment posterior fixation. The cervical lesion was scheduled for a second-stage surgical procedure after recovery from the initial intervention.

Conclusions: Thoracolumbar transdiscal fractures through Andersson lesions are an exceptionally rare but potentially devastating complication of advanced ankylosing spondylitis. This case underscores the importance of maintaining a high index of suspicion for unstable thoracolumbar injuries in patients with advanced AS presenting with myelopathic symptoms. Prompt recognition of these uncommon lesions is crucial to prevent irreversible neurological impairment. In patients with multilevel spinal involvement, prioritizing surgery according to the most unstable and symptomatic lesion is essential.

P144 - Management strategy for a giant occipital encephalocele

Kerroum Imene, F Benamara

EHS des urgences médico chirurgicale Akid Lotfi BOUHNIFIA MASCARA, Algeria

Background: encephalocele is a rare congenital neural tube defect. the giant nature of the malformation makes our case unique the aim of this study is to report our management strategy and outcomes

Methods: our case reports a 3-month-old female infant, whose history dates back to the antenatal period with the discovery of a cranioencephalic malformation on ultrasound. A brain MRI was performed, revealing a large herniated occipital mass containing cerebrospinal fluid as well as dysplastic neural structures protruding through a large bone defect of the craniovertebral junction, measuring 180*220mm along its major axis. T1 hypointensity, T2 hyperintensity. The surgical strategy relies on low-flow drainage prior to the excision of the epidermal sac. watertight closure of the dura mater closure of the skin

Results: complete resection with tension-free skin closure. immediate postoperative period: _absence of major complications _no Cerebrospinal fluid leak _no necrosis of the skin flap. _no infection. Follow-up brain MRI Good anatomical reconfiguration. absence of secondary hydrocephalus.

Conclusions: An aggressive yet cautious surgical management of a giant occipital encephalocele is possible and can yield excellent cosmetic and neurological outcomes. A well-planned multidisciplinary strategy (Neurosurgery,pediatric intensive care specialist,+/- plastic surgery) is the key factor for success.

P145 - Mapping the unspeakable: predicting sexual dysfunction after neurosurgical procedures through a risk-zone framework

Majdouline Barkache, Affes A, Akrout F, Rachdi MA, Hdhili H, Farhat S, Chkili R, Radhouen K

Neurosurgery Department, Military Hospital of Tunis, Tunis, Tunisia

Background & objectives: Sexual dysfunction following neurosurgical procedures remains systematically underreported, poorly consented, and inadequately studied. Yet lesions or surgical manipulation involving specific cerebral and spinal structures carry reproducible, predictable risks of disrupting desire, arousal, orgasm, and erectile or ejaculatory function. This review proposes a structured risk-zone framework — a practical anatomical roadmap enabling neurosurgeons to anticipate, disclose, and potentially mitigate sexual dysfunction before, during, and after surgery.

Methods: Narrative review of PubMed and Scopus databases (2000–2024), including lesion-symptom mapping studies, fMRI connectivity analyses, spinal cord injury sexual outcome data, and neuromodulation literature. Brain and spinal structures were classified by level of evidence for sexual risk.

Results & discussion: Cerebral risk zones: The medial prefrontal cortex and orbitofrontal region govern sexual inhibition and social sexual behavior — resection or injury produces disinhibition and hypersexuality. The hypothalamus and septal nuclei are critical for desire and autonomic arousal — damage results in global sexual apathy. Temporal lobe surgery, particularly dominant hemisphere resections, disrupts sexual ideation and emotional sexual processing. The insula, increasingly recognized as the visceral-sexual integration hub, carries underestimated risk in minimally invasive approaches. Spinal risk zones: Conus medullaris and cauda equina lesions produce predictable peripheral sexual failure — erectile dysfunction, absent emission, anorgasmia. Thoracolumbar junction surgery risks sympathetic disruption and retrograde ejaculation. Cervical cord injury, including central cord syndrome, paradoxically preserves psychogenic arousal pathways while disrupting reflexogenic responses, with variable cortical compensation. Predictive tools: Preoperative fMRI mapping of sexual networks, diffusion tensor imaging of relevant white matter tracts, and structured sexual history questionnaires (IIEF, FSFI) represent underutilized but available instruments for surgical risk stratification.

Conclusion: Sexual dysfunction after neurosurgery is predictable, mappable, and therefore partially preventable. Integrating a risk-zone framework into preoperative planning and informed consent is both ethically mandatory and surgically feasible. What was once unspeakable must become standard of care.

P146 - Mature intramedullary teratoma associated with spina bifida in an adult: a rare case report

Amel Sebti, Bennas, Sahraoui

EPH Oum El Bouagui, CHU Blida, Algeria.

Introduction: Intramedullary teratomas are exceptionally rare tumors whose pathogenesis remains poorly understood. Their association with spinal dysraphism has been frequently reported. We present a rare case of a mature intramedullary teratoma associated with spina bifida in an adult patient.

Case presentation: A 30-year-old man presented with progressive neurological symptoms. Spinal magnetic resonance imaging (MRI) revealed an intramedullary lesion of the conus medullaris associated with spina bifida. Microsurgical resection was performed. Histopathological examination confirmed the diagnosis of a mature teratoma. The postoperative course was favorable, with clinical improvement.

Discussion: Intramedullary teratomas were initially described under the terms teratoid cyst, cystic teratoid lesion, or cystic teratomatosis. According to Russell and Rubinstein, a teratoma is a tumor composed of derivatives of the three embryonic germ layers: ectoderm, mesoderm, and endoderm. Eighteen cases of intramedullary teratomas, including the present case, have been reported in the literature. The conus medullaris is the most common location. These tumors occur predominantly in males and are more frequently observed in adults. Clinical manifestations are similar to those of other intramedullary tumors. However, unlike most intramedullary neoplasms, they are commonly associated with spinal dysraphism, including spina bifida, meningocele, and lipomeningocele. The most widely accepted hypothesis suggests abnormal migration of primitive germ cells during embryogenesis.

Conclusion: Mature intramedullary teratoma associated with spina bifida is an extremely rare entity. MRI is essential for preoperative diagnosis, and microsurgical resection remains the treatment of choice.

P147 - Médulloblastoma presenting as isolated leptomeningeal dissemination with no primary mass

Kribaa Amina, N.Tighilt, A.H.Zireg, A.Mensri, H.Sebhi, N.Lagha, A.Morsli

Mouhaled Lamine Debaghine univerty hospital center Algeris, Algeria

Background: Medulloblastoma is a malignant embryonal tumor accounting for 12–25% of central nervous system tumors in children and 0.1–1% in adults. It usually presents as a cerebellar mass, while diffuse leptomeningeal dissemination without an identifiable primary tumor is exceptionally rare and referred to as primary leptomeningeal medulloblastoma.

Methods: We report the case of a 13-year-old child with no significant medical history who presented with a three-month history of intracranial hypertension syndrome characterized by headaches and vomiting, followed by asthenia and weight loss. Neurological examination was otherwise normal. Comprehensive biological and radiological investigations were performed, excluding infectious, autoimmune, endocrine, and vascular etiologies. Brain and spinal MRI demonstrated diffuse leptomeningeal enhancement associated with nodular lesions involving the cauda equina roots, without evidence of an intracranial mass lesion. Surgical biopsy and excision of the cauda equina nodules and pathological arachnoid tissue were undertaken.

Results: Histopathological analysis confirmed a desmoplastic medulloblastoma, molecularly classified as non-WNT/non-SHH, with a Ki-67 proliferation index of 50%. The diagnosis of primary leptomeningeal medulloblastoma was established based on the absence of a detectable primary mass and the presence of diffuse leptomeningeal disease. The patient was subsequently referred to the oncology team for further management.

Conclusions: Primary leptomeningeal medulloblastoma is an extremely rare presentation of medulloblastoma. In patients presenting with signs of intracranial hypertension and diffuse leptomeningeal enhancement without a visible primary mass, this diagnosis should be considered. Early neurosurgical biopsy may facilitate prompt diagnosis and timely initiation of appropriate treatment Content Presentation here

P148 - Metabolic optimization through mediterranean diet in a low-grade glioma patient with drug-resistant seizures: a case report

Oumaima Rmida, F.Kolsi, M.Elleuch, K.Ayedi, S.Ben Fredj, I.Dammak, Y.Chaker, Y.Moussa, H.Jaziri, Y.Feki, Bmz .Boudawara

Neurosurgery Department of Habib Bourguiba University Hospital Sfax.

Background: Gliomas are infiltrative primary brain tumors often associated with seizures and metabolic disturbances. Nutritional status may influence neuroinflammation, systemic metabolism, and overall treatment tolerance. This case highlights the potential role of targeted nutritional intervention as an adjuvant strategy in a patient with a presumed low-grade fronto-temporal glioma presenting with generalized tonic-clonic seizures.

Methods: We report the case of a 30-year-old male admitted for two episodes of generalized tonic-clonic seizures. Brain CT imaging revealed an infiltrative expansile lesion involving the left fronto-temporal region, suggestive of a low-grade glioma. Initial evaluation showed overweight status (BMI 25.7 kg/m²), marked hypoproteinemia (47 g/L) with proteinuria, dyslipidemia (LDL 3 g/L), hypomagnesemia (0.70 mmol/L), and low serum iron (23 µmol/L), despite normal HbA1c and ferritin levels. The patient was started on corticosteroids and antiepileptic therapy. A Mediterranean-based hyperproteic diet (1.5 g/kg/day, 2300 kcal/day), with neuroprotective and anti-inflammatory properties, was implemented.

Results: After 1 month of nutritional intervention (Mediterranean Diet Score = 10), significant metabolic and clinical improvements were observed. Total protein levels normalized (70.74 g/L), LDL cholesterol decreased (2.24 g/L), and micronutrient status improved, including magnesium (1.07 mmol/L), iron (30 µmol/L), and ferritin (117.84 ng/mL). Clinically, a progressive reduction in seizure frequency was reported. At 3 months, metabolic parameters remained stable, confirming sustained correction of nutritional imbalances and clinical stabilization.

Conclusion: This case suggests that a structured Mediterranean hyperproteic diet may serve as a valuable adjunctive approach in patients with glioma, contributing to metabolic correction and possible clinical improvement in seizure control. Further prospective studies are required to validate the role of targeted nutritional strategies in neuro-oncology care.

P149 - MGMT methylation and its prognostic significance in grade IV glioblastoma: lessons from a case series

Syrine Saadoun, Mohamed Maher Hadhri, Ghassen Belkahla, Fatma Missaoui, Asma Felfoul, Balkiss Ben Ali, Mehdi Darmoul.

Neurosurgery Department, Fattouma Bourguiba University hospital, Monastir, Tunisia.

Background: O6-methylguanine-DNA methyltransferase (MGMT) promoter methylation is a well-established predictive biomarker of response to temozolomide (TMZ) chemotherapy in glioblastoma (GBM). This study aimed to evaluate the prognostic significance of MGMT promoter methylation by correlating molecular status with survival outcomes in patients with grade IV glioblastoma.

Methods: A retrospective study was conducted on patients with histologically confirmed grade IV glioblastoma treated at the Neurosurgery Department of Fattouma Bourguiba University Hospital, Monastir, between December 2019 and January 2024. MGMT promoter methylation status was determined using methylation-specific polymerase chain reaction (MSP-PCR). Demographic, clinical, and treatment-related data, including age, sex, extent of resection, adjuvant therapy, progression-free survival (PFS), and overall survival (OS), were analyzed.

Results: Fourteen patients were included. MGMT promoter methylation was identified in 30% of cases, while 70% were unmethylated. Patients with methylated MGMT demonstrated improved clinical outcomes, with a median overall survival of 14 months compared with 8 months in the unmethylated group. They also exhibited longer progression-free survival and a more favorable response to TMZ-based chemoradiotherapy. These findings support the prognostic value of MGMT methylation despite the limited sample size.

Conclusion: MGMT promoter methylation is an important prognostic and predictive biomarker in grade IV glioblastoma, associated with improved response to temozolomide and prolonged survival. Routine assessment of MGMT methylation should be integrated into the multidisciplinary management of glioblastoma to facilitate personalized therapeutic strategies. Larger prospective studies are warranted to validate these findings.

P150 - Microsurgical management of intracranial aneurysms at the national hospital center a nouakchott mauritania.

Med Soultane Med Abderrahmane, Emal Tolba, Sidi Memou, Sidi Med Salihy

Department of Neurosurgery, National Hospital Center a Nouakchott Mauritania

Introduction: Intracranial aneurysms are vascular malformations of arterial origin. In ther common anatomical form, they manifest as a saccular dilation of the artery supplying the vessel,corresponding histologically to a zone of parietal fragility.

Materials and methods: This was a retrospective study conducted over a 6 year frome 1 jabuary 2020 to 31 december 2025 in the neurosurgery departement of the national center of nouakchott(mauritania).

Results: The number of patients hospitalized for intracranial arterial aneurysms during this six year period in the neurosurgery departement of the national hospital centre was 150 reprenting 0.2. The mean age in our series was 44.65 years , with a range frome 11 to 70 years. Our female predominece with a sex-ratio of 0.85. Sudden onset headaches acconted for 80 p, of symptoms. The most aneurysme location was the anterior communicating artery acconting for 40 p of cases. 150 patients underwent microchirurgical exclusion of the aneurysms representeing 100 p of cases.post operative deaths occurred in 20 p of cases.

Conclusion: Through this serie and a review of the litterature, we conclude that the frequency of intracranial aneurysms in our study represents 0.2 p of hospitalization. Exlusion of the aneurysme should be performed as early as possible.

P151 - Microsurgical sectioning of the filum terminale in adult tethered cord syndrome associated with complex lumbar dysraphism: a case report

Farah Bahri, G.Gader, H.Hdhili, F.Ferjani, M.Bounemra, A.Hermassi, S.Ben Zekri, A.Bedioui, M.Rkhami, M.Badri, K.Bahri, I.Zammel

Department of Neurosurgery, Ben Arous Trauma Center, Tunisia

Background: Adult tethered cord syndrome (TCS) is a rare manifestation of occult spinal dysraphism caused by abnormal fixation of the spinal cord. Owing to its insidious presentation and nonspecific symptoms, diagnosis is often delayed. Surgical sectioning of the filum terminale is the standard treatment to relieve spinal cord traction, prevent neurological deterioration, and improve functional outcomes.

Methods: We report the case of a 54-year-old man presenting with chronic low back pain and progressive weakness of the left lower limb over several years. Neurological examination revealed left lower limb amyotrophy and a scoliotic posture without objective motor, sensory, or sphincter deficits. Magnetic resonance imaging demonstrated a complex congenital lumbar malformation with an L4–L5 vertebral block, right-convex scoliosis, and a low-lying conus medullaris terminating at the L4–L5 level, consistent with tethered cord syndrome. The patient underwent microsurgical untethering through limited lumbar exposure and sectioning of the filum terminale under microscopic visualization.

Results: The filum terminale was successfully identified and sectioned without intraoperative complications. The postoperative course was uneventful. At follow-up, the patient reported significant improvement in low back pain and gait, with stabilization of neurological function and no new motor, sensory, or sphincter deficits.

Conclusion: Although uncommon in adults, tethered cord syndrome should be considered in patients with chronic back pain and subtle neurological signs, particularly in the presence of congenital spinal anomalies. Microsurgical sectioning of the filum terminale is a safe and effective procedure that arrests neurological deterioration while providing meaningful functional improvement. This case highlights the importance of early recognition and meticulous microsurgical technique in the successful management of adult tethered cord syndrome.

P152 - Mind the skull: long-term neuropsychological outcomes after craniosynostosis surgery

Kais Bouzouita, Rachdi M.A., Kammoun T, Yedeas MD, Achoura S, Chkili Ridha, Radhouen K.

Neurosurgery Department, Military Hospital of Tunis, Tunis, Tunisia

Background & objectives: Craniosynostosis surgery successfully corrects craniofacial morphology and normalizes intracranial pressure in the majority of patients, yet morphological success does not guarantee neurodevelopmental normalcy. Cognitive, linguistic, behavioral, and academic difficulties persist in a significant proportion of surgically corrected craniosynostosis patients, raising questions about the adequacy of current surgical timing, the role of residual intracranial hypertension, and the independent contribution of genetic syndromic factors to neurodevelopmental outcomes. This review examines long-term neuropsychological outcomes following craniosynostosis surgery.

Methods: Narrative review of PubMed, Scopus, and PsycINFO databases (2005–2024), including prospective neurodevelopmental cohort studies, long-term follow-up series, and neuropsychological assessment reports in surgically corrected craniosynostosis patients across suture subtypes and syndromic categories.

Results & discussion: Cognitive outcomes: Mean IQ scores in isolated single-suture craniosynostosis patients following early surgical correction fall within normal ranges, yet significantly elevated rates of specific learning disabilities, attention deficits, and processing speed impairments are consistently reported compared to matched controls, independent of surgical timing. Language and literacy: Metopic and sagittal synostosis patients demonstrate disproportionate language processing and reading difficulties at school age, suggesting frontal and parietal cortical involvement beyond the primary morphological deformity. Behavioral outcomes: Attention deficit hyperactivity disorder, anxiety, and social communication difficulties are two to three times more prevalent in craniosynostosis cohorts than population norms, with syndromic patients demonstrating significantly greater behavioral morbidity than isolated cases. Surgical timing impact: Earlier surgery — before 6 months — consistently associates with superior neurodevelopmental trajectories, supporting aggressive early intervention while acknowledging that morphological correction alone does not eliminate neurodevelopmental risk.

Conclusion: Craniosynostosis surgery corrects the skull but not necessarily the brain's developmental trajectory. Systematic long-term neuropsychological surveillance, early educational intervention, and multidisciplinary craniofacial team follow-up are essential components of comprehensive craniosynostosis care extending well beyond the operating room.

P153 - Misleading MRI, decisive histology: report of two cases of intramedullary glioblastoma

Angham Grioui, Ben Fredj Rihab, Gallaoui Slim, Hajji Balkis, Barkache Majdouline, Ksira Iyadh

Department of Neurosurgery, Sahloul University Hospital, Sousse, Tunisia

Background: Intramedullary glioblastoma is an extremely rare central nervous system tumor, accounting for approximately 1.5% of all spinal cord tumors, with a predilection for the cervical and thoracic regions. Its nonspecific clinical presentation and radiological resemblance to other spinal pathologies make diagnosis particularly challenging. Despite multidisciplinary management, the prognosis remains poor, with a short overall survival.

Methods: We report two cases of young female patients presenting with rapidly progressive spinal cord compression. Case 1: A 25-year-old woman with a history of iron-deficiency anemia receiving iron supplementation was admitted for gait disturbances evolving over one month, bilateral C7 cervicobrachial neuralgia, object-dropping episodes and pollakiuria. Neurological examination revealed paraplegia, distal weakness of both upper limbs, and pyramidal syndrome. Spinal MRI suggested cervical and thoracic meningiomatosis involving the C3, C7, T3, and T4 levels. The patient underwent C6–C7 laminotomy with biopsy. Case 2: A 34-year-old woman with no significant medical history was admitted for post-traumatic neck pain associated with left upper-limb monoparesis and urinary dysfunction characterized by dysuria. Neurological examination demonstrated bilateral distal upper-limb weakness, left lower-limb monoplegia, a sensory level at T2, and pyramidal syndrome. Spinal MRI revealed an anterior compressive epidural hematoma extending from C6 to T2. A C6–C7 laminectomy was performed, revealing an intradural highly hemorrhagic tumor infiltrating the spinal cord, from which biopsy samples were obtained.

Results: Histopathological examination in case number 1 revealed a WHO grade IV, IDH-wildtype glioblastoma. Postoperatively, the motor deficit remained stable. The patient was subsequently referred for radiotherapy. Histopathological analysis for patient number 2 confirmed the diagnosis of glioblastoma. She remained with flaccid quadriplegia and was referred for adjuvant radiochemotherapy.

Conclusion: Intramedullary glioblastoma is an exceptionally rare and highly aggressive tumor. Its clinical and radiological features may mimic other spinal pathologies, leading to diagnostic uncertainty. Histopathological examination remains the cornerstone of diagnosis. Surgical management is frequently limited by the infiltrative nature of the lesion, and despite advances in adjuvant therapies, prognosis remains poor.

P154 - Mixed germ cell tumor located in the sellar and suprasellar regions

Mohammed Al Amine El Farissi, Mohamed Dahamou, Hamid Khay, Khoulali Mohamed

Department of Neurosurgery, Mohammed VI University Hospital, Faculty of Medicine and Pharmacy of Oujda, Mohammed First University, Oujda, Morocco.

37-year-old man, sudden visual loss. MRI: sellar/suprasellar lesion with pituitary apoplexy. Complete endonasal resection. Histopathology: mixed germ cell tumor. Postoperative visual improvement (right eye 3/10, left eye finger counting). Adjuvant chemoradiotherapy. One-year MRI: asymptomatic cystic lesion.

P155 - Modern neurosurgical strategies in the management of cystic craniopharyngiomas: from the literature to the experience of the EHS of cherchell

Nasreddine Baz, Chabat.A, Boudjadja.B, Dergham.D, Benallag.S, Bouaita.K

Department of Neurosurgery, EHS Cherchell, Algeria

Background: Cystic craniopharyngiomas are benign (Grade I) sellar and suprasellar tumors, yet locally aggressive. Due to their proximity to the hypothalamus and optic pathways, the dogma of radical resection has progressively given way to functional-sparing strategies. This article compares the recommendations found in the scientific literature with the clinical experience of the Specialized Hospital Establishment (EHS) of Neurosurgery in Cherchell.

Materials and methods: A cross-sectional analysis was conducted between a literature review and a retrospective single-center series of 51 patients (bimodal pediatric and adult population) operated on at the EHS of Cherchell between 2020 and the present day.

Results: The therapeutic approach was individualized according to patient age and tumor topography. The transcranial route was used in 27 patients (including 25 pterional approaches and 9 transcallosal approaches) for complex lesions or those with lateral extension. Transsphenoidal endoscopy was preferred in 13 patients, offering direct visual control of the hypothalamic-pituitary axis. For pan-cranial tumors, 4 patients required a simultaneous combined approach (transcranial and endoscopic). Given the high risk of recurrence, minimally invasive drainage was widely adopted: 30 Rickham reservoirs were implanted, of which 14 were used as exclusive treatment (emergency decompression) and 16 as adjuvant treatment either pre- or postoperatively.

Conclusion: The experience of the EHS of Cherchell corroborates the evolution of international standards. The abandonment of systematic aggressive surgical resection in favor of hybrid approaches — combining transcranial microsurgery, skull base endoscopy, and Rickham reservoir drainage — makes it possible to optimize tumor control while drastically preserving the visual and neuro-endocrine functions of patients.

P156 - Morbidity and mortality of cervical spine trauma in elderly patients: the critical impact of medical comorbidities

Rami Ben Mhenni, Hamdi Kaziz[1], Mohamed Amine Hmida[2], Sadok Chtai[1], Aymen Hanafi[1], Mourad Mtaoumi[1], Mohamed Ali Khalifa[1], Karim Bouattour[1]

[1] Department of Orthopaedic Surgery and Traumatology, Sahloul University Hospital, Sousse, Tunisia.

[2] Department of neurosurgery, Sahloul University Hospital, Sousse, Tunisia.

Introduction: Cervical spine trauma in patients over 65 is a growing public health problem associated with high mortality. The respective contributions of the spinal lesion and of systemic frailty to death remain poorly defined in this population. The objective was to describe the rate, timing and causes of mortality in elderly patients managed for cervical spine trauma.

Materials and methods: A retrospective descriptive single-centre study was conducted at *** University Hospital. All patients aged ≥65 years admitted for cervical spine fracture between January 2014 and December 2024 were included; pathological fractures, old fractures and incomplete records were excluded. Demographic, clinical, therapeutic and outcome variables — including the timing and cause of each death — were collected using a standardized form. The main outcome was overall mortality.

Results: Thirty patients were included (mean age 69 ± 4.46 years; 70% men); 83.3% had ≥1 pre-existing comorbidity. Eight deaths occurred (26.7%). Five (16.7%) were early, during the initial hospitalization, and of strictly systemic origin: cardiorespiratory arrest from acute coronary syndrome (3), acute left ventricular failure (1) and haemorrhagic stroke under vitamin-K antagonist therapy (1). Three deaths were secondary: massive pulmonary embolism (1), septic shock from infected pressure sores in a complete tetraplegic patient (Frankel A) (1) and spontaneous postoperative cardiorespiratory arrest (1). Mortality was therefore predominantly non-neurological and comorbidity-driven.

Conclusion: Immediate vital prognosis in elderly cervical spine trauma is largely determined by decompensation of pre-existing cardiorespiratory comorbidities rather than by the spinal lesion itself. Multidisciplinary perioperative management (spinal surgeons, intensivists, cardiologists) is mandatory and weighs as heavily as the spinal procedure.

P157 - More than a pretty picture: is EOS imaging essential or just convenient in spinal practice?

Ameur Affes, Rachdi M.A., Kammoun T, Bouzouita K, Achoura S, Chkili Ridha, Radhouen K.

Neurosurgery Department, Military Hospital of Tunis, Tunis, Tunisia

Background & objectives: EOS biplanar imaging, introduced as a low-dose alternative to conventional radiography and CT, provides simultaneous frontal and lateral full-body acquisitions with three-dimensional reconstruction capability. While increasingly adopted in spinal deformity centers, its added clinical value beyond conventional imaging remains debated — is EOS a genuine diagnostic and surgical planning necessity, or primarily a sophisticated, costly convenience? This review critically examines current evidence on EOS imaging's diagnostic accuracy, radiation exposure, surgical planning utility, and cost-effectiveness in spinal practice.

Methods: Narrative review of PubMed, Scopus, and Cochrane databases (2010–2024), including comparative studies evaluating EOS versus conventional radiography and CT across radiation dose, measurement reliability, 3D reconstruction accuracy, and clinical decision-making impact.

Results & discussion: Radiation reduction: EOS consistently demonstrates substantial radiation dose reduction — up to 50–85% compared to conventional radiography and significantly lower than CT — representing a major advantage in pediatric and young adult populations requiring repeated follow-up imaging. Measurement reliability: Cobb angle, sagittal balance, and pelvic parameter measurements obtained via EOS show excellent interobserver and intraobserver reliability, comparable or superior to conventional radiographs, with the added benefit of standing, weight-bearing, full-spine acquisition in a single exposure. 3D reconstruction and surgical planning: Three-dimensional vertebral reconstruction enables precise assessment of axial rotation and global spinal alignment, increasingly integrated into preoperative planning for complex deformity correction and rod contouring strategies unavailable through standard biplanar films. Cost and accessibility limitations: High acquisition costs, limited installation in resource-constrained centers, and absence of demonstrated superiority for routine, non-deformity spinal pathology temper claims of universal necessity.

Conclusion: EOS imaging is far more than a "pretty picture" — it provides genuine clinical value in radiation reduction and three-dimensional surgical planning for complex spinal deformity. However, for routine spinal pathology, its necessity over conventional imaging remains less clearly established, positioning EOS as essential in deformity-focused centers rather than universally mandatory.

P158 - Multinodular vacuolating neuronal tumor revealed by drug-resistant temporal lobe epilepsy: a case report

Imen Dammak, Ines Cherif [1], Youssef Mbarki [1], Wiem Boudabbous [1], Jihane Ketata [2], Hichem Ammar[1]

[1].Department of Neurosurgery, Sfax Military University Hospital, Tunisia 2.Department of Neurology, Sfax Military University Hospital, Tunisia

Introduction: Multinodular vacuolating neuronal tumors (MVNTs) are rare tumors of the central nervous system, classified among glioneuronal tumors, and are often revealed by drug-resistant focal epilepsy.

Case report: We report the case of an 18-year-old patient who had been followed since the age of 14 for drug-resistant temporal lobe epilepsy, with approximately ten seizures per month and secondary generalization, despite well-conducted antiepileptic treatment. This epilepsy had a significant impact on his schooling. Preoperative EEG showed left temporal epileptiform abnormalities. Brain imaging revealed a left parasagittal parietal multinodular cystic lesion, suggestive of a glioneuronal tumor. Surgical resection of the lesion was performed. Histopathological examination was consistent with an MVNT. The postoperative course was favorable, marked by disappearance of epileptic seizures. At outpatient follow-up, with a six-month follow-up period, control electroencephalography showed regression of the epileptiform abnormalities.

Conclusion: MVNTs are rare glioneuronal tumors with a generally indolent course, which may present as drug-resistant focal epilepsy in young patients. This case highlights the importance of considering this diagnosis in the presence of a multinodular brain lesion associated with chronic epilepsy resistant to medical treatment. Surgical resection, when indicated, allows both histopathological confirmation and favorable seizure control. Clinical, radiological, and electroencephalographic follow-up remains necessary to assess long-term evolution.

P159 - Neglected congenital occipital encephalocele revealed by superinfection and secondary parotitis in adolescence: a case report and review of the litterature

Emna Elouni, Roua Latrach, Firas Sliti, Nessrine Nessib, Slimane Abdelhafidh, Imed Ben Said, Jalel Kallel

Neurosurgery Departement, National Institute of Neurology, Tunis, Tunisia

Background: Occipital encephaloceles are rare congenital neural tube defects that are typically diagnosed and treated during infancy. Delayed presentation in adolescence is exceptional, particularly in neurologically intact patients. Infectious complications with extension to adjacent structures are exceedingly uncommon.

Methods: We report the case of a 19-year-old female born to non-consanguineous parents with a congenital occipital swelling that had never been investigated because of normal psychomotor development and the absence of neurological symptoms. Clinical, radiological, and therapeutic data were retrospectively reviewed.

Results: The patient presented with a one-week history of febrile headaches and vertigo. Physical examination revealed a long-standing right retroauricular mass associated with recent extension of soft tissue swelling toward the parotid region. Computed tomography demonstrated a congenital occipital encephalocele with signs of superinfection. The lesion was in close contact with the parotid gland, resulting in secondary parotitis. The diagnosis of a neglected congenital occipital encephalocele complicated by local infection and parotid extension was established. Multidisciplinary management involving neurosurgical and infectious disease teams was undertaken.

Conclusion: This case highlights a rare late complication of an untreated congenital occipital encephalocele. Despite normal neurological development, congenital cranial malformations require early evaluation and follow-up to prevent potentially serious infectious complications. Clinicians should consider underlying congenital anomalies when assessing atypical retroauricular or parotid infections.

P160 - Neurological rescue via ventriculoperitoneal shunting in pediatric tuberculous hydrocephalus: when and how to shunt? a case report and literature review

Raoud Abderrezak, Khiter Sarah, Gasmi Naserdine

Department of Neurosurgery, Hassani Abdelkader University Hospital, Sidi Bel Abbes, Algeria

Introduction: La méningite tuberculeuse (MTB) infantile est grevée d'une lourde morbi-mortalité. L'hydrocéphalie, sa complication majeure, résulte du blocage des voies du liquide cérébrospinal (LCS) par l'exsudat inflammatoire basilaire. Nous discutons la place de la dérivation ventriculo-péritonéale (DVP) après temporisation par dérivation ventriculaire externe (DVE).

Observation: Un enfant de 11 ans a été admis pour hypertension intracrânienne (HTIC) et altération de l'état général. L'imagerie (TDM/IRM) a révélé une hydrocéphalie tétraventriculaire communicante avec arachnoïdite basilaire. L'analyse du LCS a confirmé la MTB (hyperprotéinorachie, hypoglycorachie, pléiocytose). Malgré une quadrithérapie antituberculeuse et une corticothérapie, l'état neurologique s'est détérioré. Face au risque d'obstruction d'une valve définitive par ce LCS hyperprotéinorachique, une DVE transitoire a été posée, avec des switchs itératifs toutes les 3 à 4 semaines. Dès obtention d'un LCS stérile et normalisé, une DVP définitive a été implantée. Les suites ont été marquées par une récupération neurologique spectaculaire (régression de l'HTIC, reprise de la marche) et une nette réduction de la taille ventriculaire.

Discussion: Le traitement de l'hydrocéphalie post-MTB pédiatrique associe urgence décompressive et gestion du risque de dysfonctionnement de valve. La littérature valide cette stratégie séquentielle : la DVE temporaire contrôle l'HTIC aiguë et protège le matériel définitif en attendant l'assainissement biochimique du LCS. Les changements réguliers de cathéter préviennent la surinfection nosocomiale. Une fois le LCS stérile, la DVP assure un drainage pérenne efficace.

Conclusion: L'hydrocéphalie sur MTB est une urgence médico-chirurgicale. En cas d'évolution réfractaire, la DVP précédée d'une DVE de temporisation constitue une stratégie séquentielle sûre et efficace pour optimiser le pronostic fonctionnel de l'enfant.

P161 - Neurosurgery without borders: adapting evidence-based standards to resource-limited settings

Ameur Affes, Rachdi M.A., Hdhili H, Bouzouita K, Achoura S, Yedeas MD, Chkili Ridha, Radhouen K.

Neurosurgery Department, Military Hospital of Tunis, Tunis, Tunisia

Background & objectives: Over 90% of the global neurosurgical burden falls upon low- and middle-income countries, where access to neuroimaging, operative infrastructure, intensive care, and trained neurosurgeons remains critically deficient. The direct transposition of high-income country guidelines and standards to resource-limited settings is neither feasible nor always appropriate, yet no structured framework currently guides evidence-based neurosurgical practice adaptation in constrained environments. This review examines the challenges, adaptations, and innovations characterizing neurosurgery in resource-limited settings.

Methods: Narrative review of PubMed, Scopus, and global surgery databases (2010–2024), including epidemiological studies, outcome analyses, and implementation research addressing neurosurgical capacity, access barriers, and context-adapted management strategies in low- and middle-income countries.

Results & discussion: Epidemiological burden: Traumatic brain injury, hydrocephalus, spina bifida, and neuroinfection collectively represent the dominant neurosurgical pathologies in resource-limited settings, contrasting sharply with the elective degenerative and oncological case mix of high-income centers, demanding fundamentally different prioritization frameworks. Infrastructure and workforce gaps: Neurosurgeon-to-population ratios below 0.1 per 100,000 in sub-Saharan Africa and parts of the Middle East and North Africa region, combined with limited neuroimaging access and absent neurointensive care, necessitate triage-based, conservative-first management protocols incompatible with standard Western guidelines. Context-adapted innovations: Endoscopic third ventriculostomy with choroid plexus cauterization has emerged as a viable shunt-free hydrocephalus treatment in resource-limited settings, reducing device-dependent complications. Task-sharing models, point-of-care ultrasound for ICP estimation, and teleneurosurgery consultation platforms represent validated adaptations demonstrably improving outcomes within existing constraints. Training and capacity building: Sustainable neurosurgical development requires in-country residency program strengthening, regional fellowship networks, and simulation-based surgical training, rather than reliance on short-term visiting surgeon missions with limited durable impact.

Conclusion: Resource-limited neurosurgery demands contextually adapted, evidence-informed solutions rather than simplified reproductions of high-income standards. Building local capacity, embracing appropriate technological innovation, and prioritizing the highest-burden pathologies constitute the foundation of equitable global neurosurgical care.

P162 - Neurosurgical management of scaphocephaly: clinical experience and updated literature review

Raoud Abderrezak, Dakhokh A., Larbi K., Belghazali, Motoless C.

Department of Neurosurgery, Ahmed Medeghri Hospital, Saïda, Algeria.

Introduction: Scaphocephaly, resulting from premature sagittal suture synostosis, is the most common craniosynostosis in pediatric neurosurgery. Recent literature highlights the critical importance of early intervention to optimize morphological, neurodevelopmental, and cosmetic outcomes. Advancements in cranial remodeling techniques, coupled with progress in anesthesia and perioperative care—specifically early on-table extubation—have significantly reduced postoperative morbidity. This study reports the clinical experience conducted in Saïda as part of a specialized pediatric neurosurgery twinning program.

Materials and methods: We report a case series of four infants aged 7, 9, 13, and 15 months, respectively, treated for scaphocephaly. All patients underwent a comprehensive clinical examination and preoperative radiological assessment confirming sagittal synostosis. Surgical interventions consisted of tailored cranial remodeling for each case. Anesthetic management played a pivotal role, particularly in hemodynamic control, blood loss prevention, and optimizing postoperative emergence. Early on-table extubation was successfully achieved in all patients, followed by close postoperative monitoring.

Results: The postoperative course was favorable for all infants. No deaths or major neurological complications occurred. Morphological outcomes were highly satisfactory, demonstrating significant correction of the cranial deformity. Early on-table emergence allowed for immediate neurological assessment and minimized complications related to prolonged intubation and intensive care stays.

Discussion: Recent literature confirms that early surgical intervention for scaphocephaly improves functional and cosmetic outcomes while reducing the risk of intracranial hypertension. Multidisciplinary collaboration among neurosurgeons, anesthesiologists, and intensive care teams remains essential for therapeutic success. Our experience aligns with current data emphasizing the impact of intraoperative anesthetic control and rapid-wake protocols in minimizing morbidity.

Conclusion: Early neurosurgical management of scaphocephaly yields excellent cosmetic and functional results. The experience gained in Saïda through this twinning program underscores the importance of specialized cooperation, the fundamental role of pediatric anesthesia, and the benefits of early on-table extubation in improving postoperative outcomes.

P163 - Occlusion of the bilateral foramina of monro in adults: diagnosis and management based on a case report

Roua Latrach, E. Elouni, F. Sliti, N. Nessib, A. Slimane, K. Ghedira, K. Abderrahmen, S. Bouali, I. Ben Said, J. Kallel

Department of neurosurgery , National Institute of Neurology, Tunisia.

Bilateral occlusion of the foramina of Monro is an exceptionally rare cause of obstructive hydrocephalus in adults, with only a limited number of cases reported in the literature. The condition may occur secondary to infection, inflammation, neoplastic lesions, congenital abnormalities, or may be classified as idiopathic. Owing to its rarity, the diagnosis is often challenging and the optimal management remains a subject of discussion. We report the case of a 65-year-old man with no significant past medical history who was initially treated in 2016 for obstructive hydrocephalus caused by bilateral occlusion of the foramina of Monro. Extensive investigations failed to identify any infectious, inflammatory, neoplastic, or congenital etiology. The patient underwent surgical treatment with cerebrospinal fluid diversion and experienced an uneventful postoperative recovery, subsequently resuming a normal quality of life. Several years later, he was admitted to our department with progressive deterioration of consciousness. Cranial computed tomography revealed recurrent hydrocephalus suggestive of shunt malfunction. An urgent surgical procedure was performed, consisting of ventriculo-peritoneal shunt revision and placement of a new shunt system. The patient recovered rapidly, regained full consciousness postoperatively, and was discharged three days later. During follow-up, the patient experienced multiple episodes of shunt dysfunction requiring repeated surgical revisions. Owing to recurrent distal shunt failure, a ventriculo-atrial shunt was ultimately implanted, resulting in satisfactory clinical and radiological outcomes. Idiopathic bilateral occlusion of the foramina of Monro is a rare but important cause of obstructive hydrocephalus in adults. Early recognition and appropriate surgical management are essential to prevent neurological deterioration. Long-term follow-up is required because patients may remain dependent on cerebrospinal fluid diversion procedures and are at risk of recurrent shunt-related complications.

P164 - Odontoide fractures anterior screw fixation

El Kartit Fatima, Khoulali Mohamed, Hamid Khay, El Farissi, Mohamed Dahamou.
Neurosurgery Departement of the Mohamed VI University Hospital Oujda, Morocco.

Background: odontoide fractures represent 5 to 15% of cervical spine fractures, the anterior screw fixation is the gold standard in the treatement of unstable posterior fractures.

Objective: descripe the epidemiological, radiological and clinical aspects of this time of fracture according to our departement experience patients and methodes : this is a retrospective study of 11 patients who underwent anterior screw fixation for anterior odontoide process fracture mostly after a traumatic event, the study was conducted over a period of four years; main age was 43 years old. 7 patients had a type II fracture and 4 patients a type III on the Anderson d'Alonzo classiffication. as for the roy camille classification there was two oblique fractures and two horizontal fractures with no anterior oblique fractures. post surgery bony union was assessed on CT scan at a 3 months intervall. we present an example of the cases included and describe the surgical technique used.

Results: all the patients were operated on; the union rate was 100%. 3 of the patients presented post surgery complications such as transient dysphgie and one patient presented a post traumatic stress disorder with a major depressie episode

Discussion: most of our patients didnt exhibit any neurological symptoms but had neck pain; the patients selection was based on all the patients who got admitted into our departement of neurosurgery and got operated on by an anterior approach. the union rate was satisfactory. the anterior screw fixation for odontoide fractures helps rotain the cervical rotation and has a higher rate of bony fusion with less damage to vital and surrounding tissues, therefore it can be considered as a first line of treatement in carefully selected patients.

P165 - Optimal timing of cranioplasty following infectious complications: a narrative review of current evidence

Majdouline Barkache, Akrout F, Rachdi MA, Hdhili H, Farhat S, Chkili R, Radhouen K

Neurosurgery Department, Military Hospital of Tunis, Tunis, Tunisia

Background & objectives: Cranioplasty following decompressive craniectomy is complicated by infection in 5–20% of cases, necessitating implant or bone flap removal and creating one of the most debated dilemmas in reconstructive neurosurgery: how long must the surgeon wait before safe reimplantation? Too early risks reinfection and construct failure; too late prolongs neurological vulnerability, craniectomy syndrome, and psychosocial burden. No universally accepted protocol currently defines the optimal waiting period. This review critically appraises existing evidence to establish evidence-based timing recommendations for cranioplasty after infectious complications.

Methods: Narrative review of PubMed and Scopus databases (2000–2024), including retrospective cohort studies, case series, and expert consensus statements addressing cranioplasty timing, infection eradication criteria, implant selection, and reinfection rates following infectious cranioplasty removal.

Results & discussion: Minimum waiting interval: The majority of published series advocate a minimum delay of 6–12 months following infection-related explantation, allowing complete soft tissue healing, infection eradication confirmed by normalized inflammatory markers (CRP, ESR, procalcitonin), and stable neurological status. Earlier reimplantation — below 6 months — is consistently associated with significantly higher reinfection rates (up to 30%). Infection eradication criteria: Clinical resolution alone is insufficient. Normalization of serum inflammatory markers, absence of cutaneous fistula, negative intraoperative cultures, and ideally negative nuclear medicine imaging (labeled leukocyte scintigraphy or PET-CT) constitute the most robust eradication criteria before proceeding. Implant selection: Custom porous polyethylene and PEEK implants demonstrate lower reinfection rates compared to autologous bone reimplantation in the post-infectious setting, likely reflecting superior resistance to bacterial adhesion and biofilm formation. Individualized approach: Patient age, causative organism, prior surgical history, and soft tissue quality mandate individualized rather than protocol-driven timing decisions.

Conclusion: Current evidence supports a minimum 6–12 month waiting period after infectious cranioplasty removal, contingent upon rigorous biological and imaging eradication criteria. Implant choice and individualized risk assessment are equally critical determinants of successful reconstruction.

P166 - Optimizing hemostasis in spine surgery: clinical benefits of tranexamic acid administration

Mohamed Amine Hmida, R.Benfredj, M.Baazoug, S.Guillim, A.Chaouech, I.Ksira

Department of Neurosurgery, Sahloul Hospital, Sousse, Tunisia

Introduction: Intraoperative blood loss remains a major concern in spine surgery, contributing to increased morbidity, prolonged hospitalization, and higher transfusion requirements. Tranexamic acid (TXA), an antifibrinolytic agent, has been increasingly used to reduce perioperative bleeding; however, its effectiveness and safety in routine clinical practice remain subjects of ongoing investigation.

Objective: To evaluate the impact of tranexamic acid administration on intraoperative blood loss and transfusion requirements in patients undergoing spine surgery.

Methods: A retrospective study was conducted including patients who underwent spinal surgical procedures. Patients were divided into two groups according to perioperative TXA administration. The primary outcome was intraoperative blood loss. Secondary outcomes included blood transfusion requirements and thromboembolic complications.

Results: A total of 214 patients were included, of whom 128 received TXA. Patients receiving TXA experienced significantly lower intraoperative blood loss compared with those who did not receive TXA (540 ± 210 mL vs. 820 ± 300 mL, $p < 0.001$). The transfusion rate was also significantly reduced in the TXA group (18% vs. 34%, $p = 0.01$). No significant difference was observed in the incidence of thromboembolic complications between the two groups ($p = 0.62$).

Conclusion: Tranexamic acid significantly reduces intraoperative blood loss and transfusion requirements in spine surgery without increasing the risk of thromboembolic events. These findings support the routine use of TXA as a safe and effective blood-conservation strategy in spinal procedures.

P167 - Optimizing medication management in neurosurgery: evaluation of pharmaceutical interventions and their outcomes

Ben Azouz Chayma, Emna Bokri[1], Nesrine Hasni[1], Jalel Kallel[2]

[1] :Pharmacy department, Tunisian institue of Neurology, Mongi Ben Hamida 2 : Neurosurgery Department, Tunisian institue of Neurology, Mongi Ben Hamida

Background: Optimizing medication management in hospitalized patients is a major challenge for improving the quality and safety of care. In this context, the pharmacist plays a central role, particularly through prescription review and validation. Pharmaceutical interventions (PIs) are a key component of pharmaceutical practice aimed at optimizing therapeutic management.

Materials and methods: A prospective study was conducted in the neurosurgery department over a period of 3 months. Pharmacists carried out prescription analysis and validation in accordance with the methodology of the French Society of Clinical Pharmacy (SFPC). Each identified pharmacotherapeutic problem led to a pharmaceutical intervention. The clinical and economic impacts of these interventions were assessed using the CLEO scale.

Results: A total of 38 PIs were performed. Dosage-related issues represented the most frequent medication-related problems (29 %), with dosage adjustment being the most commonly proposed PI (73%), followed by untreated indications (11%) and pharmacovigilance-related interventions (8%). The acceptance rate of PIs was 76 %. Based on CLEO assessment, PIs demonstrated a positive clinical impact in 97% of cases. Economic evaluation showed a reduction in healthcare costs in 26% of cases, while organizational impact was favorable across all PIs (O1).

Conclusion: This study highlights the essential role of pharmacists in identifying and preventing medication-related problems, supporting therapeutic decision-making, improving treatment safety, and contributing to cost containment.

P168 - Osteolytic calvarial metastasis revealing renal cell carcinoma

Fatma Ben Atig, Yasmine Fouzri, Malek Bourgou, Kamel Ben Gayed

Department of neurosurgery, Regional Hospital Sadok Mkadem Djerba, Tunisia
ICU Department, Regional Hospital Sadok Mkadem Djerba, Tunisia

Introduction: Renal cell carcinoma (RCC) is the most common primary malignancy arising from the renal parenchyma. Approximately one-third of patients develop metastatic disease, most commonly involving the lungs, liver, bones, and adrenal glands. Calvarial metastasis remains an exceptionally rare presentation and may constitute the initial manifestation of an otherwise clinically silent tumor.

Case report: We report the case of a 74-year-old woman presenting with a progressively enlarging frontal exophytic calvarial mass associated with scalp involvement. Brain magnetic resonance imaging demonstrated a destructive osteolytic frontal lesion with marked contrast enhancement, suggestive of a hypervascular tumor. Further systemic investigation with contrast-enhanced abdominal computed tomography revealed a left renal mass consistent with RCC. The patient underwent surgical excision of the cranial lesion with dural resection, followed by calvarial reconstruction. Histopathological examination confirmed metastatic clear cell RCC. A second-stage surgery consisting of nephrectomy was subsequently performed.

Conclusion: Calvarial metastasis from RCC is an uncommon entity but should be considered in the differential diagnosis of destructive hypervascular skull lesions. Such lesions may reveal an otherwise asymptomatic renal malignancy. Early recognition and multidisciplinary management are essential for optimal surgical planning and oncological treatment.

P169 - Paediatric intracranial suppurations

El Kartit Fatima, Khoulali, Khay, El Farissi, Dahamou.

Neurosurgery Departement of the Mohamed VI University Hospital Oujda, Morocco.

Background: intracranial suppurations, encompassing brain abscesses and empyema are life threatening conditions requiring prompt diagnosis and management. these intracranial infections are rare in children and can lead to devastating outcomes. the development of better imaging equipment, antibiotics, and surgical techniques has enabled significant progress in their treatement.

Objective: our study aims to analyze the epidemiology, the clinical aspects, the diagnostic challenges and therapeutic outcomes of pediatric intracranial suppurations at the neurosurgery departement of Mohammed VI University Hospital Oujda

Patients and methods: a retrospective study of 16 pediatric intracranial suppurations cases with age ranging from 1 to 16 years old. the study was conducted over a 9 years period. Epidemiological, clinical, radiological, microbiological, and therapeutic data were analyzed

Results: sixteen cases met the inclusion criteria (62.5% male, 37.5% female). The main age was 9 years old, the most affected were children between 11- and 16-years old accounting for 43.75% of the cases. brain abscess occurred in 25% of the cases while empyema in 75%. 80% of infants younger than 2 years old had a medical history of meningitis while one patient developed an empyema after a cranial surgery. 50 % of patients had an intracranial hypertension syndrom and local signs. Common symptoms included also fever (37.5%), and Bergman's triad (13%). frontal and temporal locations were the most frequent and were found in 58% of the cases. Surgical interventions included burr hole drainage (58.3%), trephination (50%), and craniotomy (8.3%). The mortality rate was 12% (resulting in one death). Pathogens were identified in 25% of cases, with Staphylococcus aureus and Streptococcus B being the most common

Conclusion: A brain abscess in children is a neurosurgical emergency whose consequences can be catastrophic despite advances in neuroimaging techniques and antibiotic therapy. Symptoms are nonspecific and may vary depending on the child's age, the location, size, number, and stage of the abscess, as well as the primary source of the infection.

P170 - Pediatric growing skull fractures : about six cases

Amina Oueslati, Nessib N, Slimane A, Fahye M, Sliti F, Abderahmene K, Ben Said I, Kallel J

Department of Neurosurgery, National Institute of Neurology, Tunis, Tunisia

Introduction: Growing skull fracture (GSF) is a rare complication of pediatric head trauma . It results from progressive enlargement of a cranial defect due to an underlying dural tear and brain pulsations. Early diagnosis and surgical treatment are essential to prevent neurological and cosmetic sequelae.

Objective: To analyze the clinical presentation, management, and outcomes of pediatric growing skull fractures treated at our institution.

Methods: We conducted a retrospective study of pediatric patients managed for growing skull fractures. Clinical records, imaging findings, surgical procedures, and outcomes were reviewed.

Results: Six children were diagnosed with growing skull fractures during the study period. All patients had a documented history of head trauma preceding diagnosis. Surgical treatment was performed in all cases. Four patients underwent duraplasty and and a correction of the cranial defect with favorable postoperative outcomes and no recurrence during follow-up. Two patients required a second surgery of ventriculoperitoneal shunt placement in addition to fracture repair. Clinical and radiological evolution was satisfactory in all patients, with stabilization of the cranial defect and improvement of presenting symptoms.

Discussion: Growing skull fractures remain an uncommon but potentially progressive consequence of pediatric cranial trauma. Their development is closely related to the presence of a dural defect, making surgical repair mandatory. While most patients can be successfully treated with dural reconstruction and cranial defect repair alone, associated hydrocephalus may require cerebrospinal fluid diversion procedures.

Conclusion: Growing skull fractures are rare lesions that require prompt recognition and surgical management. Duraplasty with cranial defect repair remains the cornerstone of treatment, while ventriculoperitoneal shunting may be necessary in selected cases complicated by hydrocephalus. Early intervention is associated with favorable clinical outcomes.

P171 - Penetrating craniocerebral injury by a retained rake with superior sagittal sinus involvement: surgical management and outcome

Safa Ben Yagoub, Ghassen Gader, Fares Ferjani, Farah Bahri, Maila Bounemra, Med Aziz Hermassi, Aziz Bedioui, Mouna Rkhami, Mohamed Badri, Kamel Bahri, Ihsen Zammel

Department of Neurosurgery, Ben Arous Trauma Center, Tunisia.

Introduction: Penetrating craniocerebral injuries caused by retained foreign bodies are rare, accounting for less than 0.4% of all traumatic head injuries, yet carry substantial morbidity and mortality. Low-velocity mechanisms, predominantly encountered in civilian settings, tend to produce more localized injury than high-velocity counterparts, though surgical management remains complex, particularly when critical neurovascular structures are involved.

Case report: A 30-year-old male with no prior medical history presented following an assault in which a rake was driven into his cranium, leaving four metallic teeth embedded in the skull. On initial assessment, his Glasgow Coma Scale score was 14/15 with no motor deficits. Preoperative CT imaging was uninterpretable due to patient positioning constraints and metallic artifacts. The patient was taken directly to surgery. With the patient placed in the prone position and the head rigidly fixed, the rake handle was sectioned using a metal-cutting saw, isolating four independent spikes. Individual mini-craniectomies were performed circumferentially around each spike to allow controlled extraction. The two paramedian spikes were removed without complication; however, the two medial spikes had penetrated approximately 2 cm into the superior sagittal sinus (SSS), resulting in significant venous hemorrhage upon removal. Hemostasis was achieved through MacKenzie clip application, packing, and pericranial dural patching. All four dural breaches were repaired with pericranialplasties reinforced with biological glue. Cranioplasty was deferred given sepsis risk. Postoperative CT confirmed an endoluminal SSS defect with localized thrombosis. The patient was initiated on curative anticoagulation 48 hours postoperatively. His recovery was complicated by ventilator-acquired pneumonia, successfully treated with antibiotics. He was extubated on postoperative day nine and discharged at 15 days with residual right upper limb monoparesis.

Conclusion: This case illustrates the critical surgical challenges posed by multi-spike penetrating cranial trauma involving the SSS, emphasizing individualized operative planning, meticulous vascular control, and vigilant postoperative management of thrombotic and infectious complications.

P172 - Penetrating craniocerebral injury caused by a drill bit involving the frontal sinus: a case report

Mohamed Znazen, A. Hachicha, H. Belmabrouk

Department of Neurosurgery, University Hospital of Gabès, Tunisia.

Background: Penetrating craniocerebral injuries caused by foreign bodies are uncommon but potentially life-threatening lesions due to the risk of infectious, hemorrhagic, and neurological complications. Injuries involving the frontal sinus represent a particular neurosurgical challenge because of their proximity to intracranial structures and the increased risk of cerebrospinal fluid leakage and intracranial infection. Early diagnosis and prompt surgical management are essential to optimize outcomes. We report a rare case of a penetrating craniocerebral injury caused by accidental drill-bit penetration involving the frontal sinus.

Methods: We describe the case of a patient admitted to the Neurosurgery Department of Gabès University Hospital for a penetrating craniocerebral injury secondary to accidental drill-bit projection. Clinical, neurological, and radiological assessments were performed on admission, and the patient underwent emergency surgical treatment.

Results: A 40-year-old man with no significant past medical history presented following accidental penetration of the skull by a drill bit. On admission, he complained of isolated headaches without loss of consciousness, seizures, or cerebrospinal fluid rhinorrhea. Neurological examination was unremarkable. Emergency brain computed tomography (CT) demonstrated a penetrating craniocerebral injury with a depressed fracture involving both the anterior and posterior tables of the frontal sinus caused by the foreign body, associated with adjacent pneumocephalus. Emergency surgery was performed through a bicoronal approach. The procedure consisted of a frontal craniotomy exposing the frontal sinus, meticulous extraction of the foreign body, watertight repair of a small dural defect, and frontal sinus cranialization. Postoperative antibiotic prophylaxis was administered. The postoperative course was uneventful, with no infectious or neurological complications. The patient was discharged home without neurological deficits or functional sequelae.

Conclusions: Penetrating craniocerebral injuries involving the frontal sinus are rare neurosurgical emergencies requiring rapid multidisciplinary management. Computed tomography remains the cornerstone of diagnostic evaluation and surgical planning. Early surgical intervention combined with appropriate antibiotic prophylaxis can effectively prevent infectious complications and achieve excellent functional outcomes.

P173 - Perfect trajectory: how artificial intelligence is revolutionizing pedicle screw placement in spinal surgery

Majdouline Barkache, Affes A, Rachdi MA, Akrout F, Kammoun T, Farhat S, Chkili R, Radhouen K

Neurosurgery Department, Military Hospital of Tunis, Tunis, Tunisia

Background & objectives: Pedicle screw placement remains one of the most technically demanding and risk-laden procedures in spinal surgery. Malposition rates with conventional freehand techniques range from 15 to 40%, carrying potentially catastrophic consequences including neurological injury, vascular damage, and construct failure. Navigation, robotics, and more recently artificial intelligence (AI) have progressively transformed screw placement accuracy. This review appraises current evidence on AI-based systems for pedicle screw trajectory planning, intraoperative guidance, and postoperative accuracy assessment, and evaluates their readiness for routine clinical adoption.

Methods: Narrative review of PubMed, Scopus, and IEEE Xplore databases (2010–2024), including studies on machine learning-based preoperative planning, AI-integrated robotic systems, computer vision-guided intraoperative navigation, and automated postoperative CT-based accuracy grading.

Results & discussion: Preoperative planning: Deep learning algorithms applied to CT datasets enable automated pedicle morphometry, trajectory optimization, and screw dimensioning with accuracy comparable to experienced spine surgeons, while dramatically reducing planning time. Intraoperative guidance: AI-integrated robotic platforms — including Renaissance, Mazor X, and Excelsius GPS — achieve Grade A/B Gertzbein-Robbins accuracy rates exceeding 95%, consistently outperforming freehand and fluoroscopy-guided techniques across cervical, thoracic, and lumbar segments. Computer vision systems provide real-time trajectory deviation alerts, adding a critical safety layer independent of surgeon experience. Postoperative assessment: Convolutional neural networks enable automated, reproducible CT-based screw accuracy grading, eliminating interobserver variability and facilitating large-scale outcome auditing. Current limitations: High acquisition costs, steep learning curves, workflow integration challenges, and limited evidence in highly deformed or revision spines temper enthusiasm for universal adoption.

Conclusion: AI is not replacing the spine surgeon — it is making every surgeon more precise. From preoperative planning to intraoperative guidance and postoperative audit, AI-driven tools are systematically closing the accuracy gap between expert and novice hands. The perfect trajectory is no longer an aspiration — it is becoming the standard.

P174 - Perforated duodenal cushing's ulcer following posterior fossa tumor surgery in a child: revisiting harvey cushing's original observations in the modern era

Ahmed Mribah, R. Ben Fredj, S.Gallaoui, M.A Hmida, O. Hattab. C.Abdelilah. I. Ksira

Department of Neurosurgery, Sahloul Hospital, Sousse, Tunisia

Introduction: Cushing's ulcer is a rare but potentially life-threatening gastrointestinal complication associated with intracranial hypertension and posterior fossa lesions. First described by Harvey Cushing in patients with cerebellar tumors, it is believed to result from autonomic dysregulation and vagal overstimulation originating from the brainstem. Although its incidence has markedly decreased in the era of modern neurocritical care and stress-ulcer prophylaxis, severe presentations still occur. We report a pediatric case of perforated duodenal ulcer following surgical treatment of a fourth ventricular tumor, revisiting Cushing's original observations.

Case presentation: A previously healthy 6-year-old boy presented with a six-week history of morning headaches, vomiting, and progressive gait disturbance. Neurological examination revealed bilateral grade II papilledema and a static cerebellar syndrome without focal neurological deficits. Brain magnetic resonance imaging demonstrated a well-circumscribed posterior fossa mass occupying the fourth ventricle and causing active triventricular hydrocephalus. An urgent ventriculoperitoneal shunt was performed, followed 20 days later by gross-total tumor resection. The immediate postoperative course was initially uneventful. On postoperative day 2, however, the patient developed severe abdominal pain, fever, and abdominal tenderness. Abdominal computed tomography revealed a large intraperitoneal fluid collection. Clinical deterioration with septic shock requiring vasopressor support prompted emergency exploratory laparotomy, which demonstrated a perforated duodenal ulcer. Surgical repair, extensive peritoneal lavage, removal of the ventriculoperitoneal shunt, and conversion to external ventricular drainage were performed. Despite progressive biological improvement, recovery remained prolonged in the intensive care unit.

Discussion and conclusion: This case closely mirrors Harvey Cushing's original reports linking posterior fossa pathology to severe gastroduodenal ulceration. Cushing proposed that such lesions resulted from "an irritative disturbance either of fiber tracts or vagal centers in the brain stem." The occurrence of a perforated duodenal ulcer after resection of a fourth ventricular tumor supports the enduring relevance of this hypothesis. More than a historical curiosity, Cushing's ulcer remains a clinically significant manifestation of the brain–gut axis and highlights the need for further research into the roles of brainstem compression, autonomic dysfunction, and intracranial pressure dynamics in neurogenic gastrointestinal injury.

P175 - Periventricular rigidity in patients presenting with hydrocephalus treated with long-term VP shunting?

Saddem Messai, Mechiche Zohir, Mahdaoui Rima, Hallaci Azeddine .

Neurosurgery department. SETIF ALGERIA .

Introduction: The failure of ventricles to enlarge after shunt dysfunction in patients with long-term shunt dependency has puzzled investigators for many years. This condition persists in shunt-dependent patients experiencing overpressure, even though cerebral CT scans show narrow ventricles. The etiology and pathogenesis of this clinical picture remain unclear, and its management is problematic.

Objective: The inability of the ventricles to dilate following acute shunt dysfunction in long-term shunt-dependent patients is generally attributed to the presence of periventricular rigidity resulting from gliosis. The purpose of this study was to test the hypothesis of periventricular rigidity in these patients.

Methods: Four patients who developed an inability of the ventricles to dilate following acute shunt dysfunction were included in this study. All four patients had undergone ventriculoperitoneal shunting procedures for hydrocephalus during infancy. They subsequently developed symptoms suggesting shunt failure, despite CT evidence of small ventricles. The mean fronto-occipital horn ratio for these patients was 0.30 ± 0.01 (normal ratio is 0.37). At the time of the shunt revision, intraventricular pressure measurement was performed.

Conclusion: Although there is morphological evidence of periventricular gliosis in some long-term shunt-dependent patients, the results of our study indicate that the periventricular wall does not limit ventricular enlargement. A complex interaction between impaired venous compliance, venous dilation, and a shift in cerebral blood flow related to prolonged cerebrospinal fluid (CSF) over-drainage may be among the factors responsible for the failure of the ventricles to enlarge.

P176 - Persistent hydrocephalus despite multiple shunt revisions: unexpected clinical improvement following pneumoventricle

Roua Latrach, E. Elouni, F. Sliti, N. Nessib, M. Naceur, A. Slimane, K. Ghedira, K. Abderrahmen, S. Bouali, I. Ben Said, J. Kallel

Department of neurosurgery , National Institute of Neurology, Tunisia.

Management of hydrocephalus remains a challenging issue in contemporary neurosurgery, mainly due to the frequency of postoperative complications associated with cerebrospinal fluid shunts, including mechanical failure, infection, and functional under- or over-drainage. More complex is the scenario of refractory hydrocephalus, defined by persistent or recurrent intracranial hypertension despite multiple shunt revisions and apparently adequate system function. This situation poses significant diagnostic and therapeutic difficulties and often reflects an underlying disturbance in cerebrospinal fluid dynamics rather than simple mechanical obstruction. We present the case of an 18-year-old female patient with no significant past medical history who presented with symptoms of isolated intracranial hypertension. Brain magnetic resonance imaging demonstrated tetraventricular hydrocephalus without evidence of associated tumor, infection, or inflammatory disease. The patient underwent urgent ventriculoperitoneal shunt placement, with an uneventful immediate postoperative course and significant clinical improvement. Two months later, she re-presented with recurrent symptoms of intracranial hypertension. Computed tomography suggested shunt dysfunction. Surgical revision was performed; however, the shunt was found to be patent intraoperatively. Despite this, the patient experienced only transient postoperative improvement. Over time, multiple shunt revisions were performed, including changes in shunt position and laterality, without sustained clinical benefit. Given the refractory nature of her condition, an alternative cerebrospinal fluid diversion strategy was attempted, resulting in inadvertent pneumoventricle following intraventricular air entry during the procedure. Interestingly, the patient demonstrated marked postoperative improvement with complete resolution of symptoms of intracranial hypertension. This unexpected clinical evolution raises the hypothesis that intraventricular air may have transiently modified cerebrospinal fluid dynamics, potentially through temporary restoration of ventricular compliance, relief of intermittent obstruction, or reopening of functional cerebrospinal fluid pathways.

P177 - Ping-pong depressed skull fracture in a child older than 10 years: a rare case report

Fayçal Houari, Mokfi, Fardji, Derbal, Guerbouz.

University hospital of Oran, Algeria.

Background: Ping-pong skull fracture is a rare type of depressed cranial fracture characterized by inward buckling of the calvarium without a visible fracture line. It predominantly occurs in neonates and infants because of the high malleability of the immature skull. Its occurrence in children older than 10 years is exceptionally uncommon. We report a rare case and discuss its management.

Methods: A 12-year-old child presented after blunt head trauma. Clinical examination, neurological assessment, and cranial computed tomography (CT) were performed. The patient underwent surgical treatment, and postoperative clinical and radiological outcomes were evaluated.

Results: The patient was admitted with a localized parietal skull depression and no focal neurological deficit (Glasgow Coma Scale score: 15). CT imaging demonstrated a focal inward deformation of the parietal bone without a distinct fracture line, intracranial hemorrhage, or cerebral contusion, consistent with a ping-pong fracture. Given the marked depression and potential risk of cortical compression, surgical elevation was performed. Postoperative CT confirmed satisfactory restoration of the skull contour. The postoperative course was uneventful, and follow-up showed excellent cosmetic and neurological outcomes.

Conclusion: Ping-pong skull fracture in children older than 10 years is an exceptionally rare entity. Recognition of this unusual presentation is important to avoid misdiagnosis and to guide appropriate management. CT remains the cornerstone of diagnosis. Surgical elevation can provide excellent cosmetic and functional outcomes in cases with significant depression. Additional reports are needed to improve understanding of the pathophysiology and optimal treatment of this uncommon condition.

P178 - Pituitary apoplexy mimicking acute bacterial meningitis and septic shock: a diagnostic challenge

Khalil Ayadi, F. Kolsi, A. Farikh, B Kammoun, MZ Boudawara

Department of neurosurgery, Habib Bourguiba University Hospital, Sfax, Tunisia

Background: Pituitary apoplexy is a rare neurosurgical emergency caused by acute hemorrhage or infarction of a pituitary adenoma. Its presentation is highly variable and may closely mimic infectious or vascular emergencies, leading to delayed diagnosis and treatment. We report a case of pituitary apoplexy initially managed as bacterial meningitis with septic shock.

Methods: A 48-year-old woman was admitted to the infectious diseases department with sudden-onset severe headache, fever, and altered general condition. Acute bacterial meningitis was suspected. A cerebral CT scan followed by a lumbar puncture was performed, and empirical broad-spectrum antibiotics were initiated. Shortly after admission, she developed profound hypotension refractory to fluid resuscitation, raising suspicion of septic shock, and was transferred to the intensive care unit. Further evaluation, including brain magnetic resonance imaging, was performed because of the persistence of neurological symptoms despite antimicrobial therapy.

Results: Magnetic resonance imaging demonstrated a hemorrhagic pituitary macroadenoma consistent with pituitary apoplexy. The patient's hypotension was attributed to acute secondary adrenal insufficiency resulting from pituitary dysfunction rather than sepsis. Intravenous corticosteroid replacement was promptly initiated, leading to rapid hemodynamic stabilization and clinical improvement. The patient subsequently underwent neurosurgical evaluation for definitive management of the pituitary adenoma, with a favorable outcome.

Conclusions: Pituitary apoplexy should be considered in patients presenting with sudden severe headache, fever, and hemodynamic instability, particularly when the clinical course is atypical or unresponsive to antimicrobial therapy. Acute hypopituitarism may mimic septic shock through secondary adrenal insufficiency. Early neuroimaging and prompt corticosteroid replacement are essential to establish the diagnosis, prevent life-threatening complications, and guide appropriate neurosurgical treatment.

P179 - Pituitary metastasis from HER2-positive breast carcinoma mimicking macroadenoma treated by endoscopic endonasal transsphenoidal resection: a case report and review of the literature.

Dergham Djamel Eddine, A.Mati, A.Chabat, S.Benallag, K.Bouaita

Department of neurosurgery, neurosurgery hospital Cherchall, Algeria

Background: Pituitary metastases are rare, accounting for approximately 0.5% of surgically treated pituitary tumors, and breast carcinoma is the most common primary source in women. They often mimic benign pituitary neuroendocrine tumors on imaging, making preoperative diagnosis difficult. Recognition is particularly important in patients with a prior history of malignancy presenting with visual and oculomotor deficits.

Methods: We report the case of a 50-year-old woman with a history of invasive breast carcinoma treated by mastectomy in 2024 and adjuvant radiochemotherapy between 2024 and 2025. She presented with a 7-year history of progressive visual decline that evolved to severe bilateral visual loss, optic chiasm syndrome, and bilateral third-nerve palsy. Brain MRI revealed a 25 × 18 × 14 mm intra- and suprasellar mass initially interpreted as a pituitary macroadenoma. The patient underwent endoscopic endonasal transsphenoidal resection. Histopathological examination and immunohistochemical profiling were performed on the resected specimen.

Results: Surgery allowed tissue diagnosis and decompression of the sellar lesion. The postoperative course was complicated by severe hypernatremia, reaching 178 mEq/L, which was successfully corrected with medical management. The patient was discharged in stable condition on postoperative day 3. Histopathology confirmed metastatic carcinoma, and immunohistochemistry showed invasive breast carcinoma NST of ductal type, with HER2 3+ positivity, ER positivity, and strong diffuse CK7 staining, establishing the diagnosis of pituitary metastasis from breast cancer.

Conclusions: Pituitary metastasis should be considered in any patient with a history of breast cancer who presents with a new sellar or suprasellar mass, especially when associated with neuro-ophthalmic deficits. Because imaging findings may closely resemble those of a macroadenoma, histological confirmation with immunohistochemistry is essential for definitive diagnosis and therapeutic planning. Accurate diagnosis is critical to guide systemic oncologic management, including HER2-targeted therapy when indicated.

P180 - Posterior fossa decompression for massive cerebellar infarction revealing a cardiac myxoma

Emna Mzoughi, Saadoun S, Trifa A, Hadj Taieb A, Belkahla G, Maamri K, Darmoul M

Neurosurgery Department, Fattouma Bourguiba University hospital, Monastir, Tunisia.

Introduction: Cardiac myxoma is the most common primary benign cardiac tumor and represents a rare cause of ischemic stroke. Cerebral embolization maybe the first manifestation of the disease and can occasionally result in life-threatening posterior circulation infarctions requiring urgent neurosurgical intervention. We report a rare case of multiple ischemic strokes caused by an undiagnosed cardiac myxoma, initially presenting with malignant cerebellar infarction and acute hydrocephalus.

Case presentation: A 62-year-old man was admitted to our department for sudden alteration of consciousness. On admission, neurological examination revealed a Glasgow Coma Scale score of 8/15. Brain magnetic resonance imaging demonstrated multiple acute ischemic infarctions involving several vascular territories, predominantly affecting both cerebellar hemispheres. Significant mass effect with compression of the brain stem and fourth ventricle was noted. Given the severity of posterior fossa compression and the risk of neurological deterioration, emergency posterior fossa decompressive craniectomy was performed. The patient's neurological status partially improved postoperatively, with recovery of consciousness. However, secondary deterioration occurred a few days later due to obstructive hydrocephalus. An external ventricular drain was subsequently inserted, resulting in further clinical stabilization. Etiological investigations were pursued to identify the source of the multiple embolic infarctions. Transthoracic echocardiography revealed a left atrial cardiac myxoma, considered the origin of the cerebral embolic events. Following neurological stabilization, the patient was referred to the cardio vascular surgery department for definitive surgical excision of the cardiac tumor.

Conclusion: Cardiac myxoma should be considered in the etiological workup of multiple ischemic strokes involving different vascular territories. Cerebellar infarctions secondary to cardio embolic events may rapidly become life-threatening due to brain stem compression and hydrocephalus, requiring urgent neurosurgical management. Early recognition of the under lying cardiac source is essential to prevent recurrent embolic complications and allow definitive treatment.

P181 - Posterior surgical management of thoracolumbar spine trauma: a single-center experience of 104 cases

Emna Mzoughi, Trifa A[1], Khelifi A[2], Belkahla G[1], Hadhri M[1], Maamri K[1], Darmoul M[1]

[1] Department of Neurosurgery, Hospital of Fattouma Bourguiba, Monastir, Tunisia.

[2] Department of Emergency, Hospital of Fattouma Bourguiba, Monastir, Tunisia.

Introduction: Thoracolumbar spine fractures are among the most common spinal injuries and may result in significant neurological impairment and spinal instability. Although several surgical approaches have been described, the posterior approach has become increasingly favored because of its ability to provide rapid stabilization and effective neural decompression. This study aimed to evaluate the epidemiological characteristics, surgical management, and outcomes of patients with thoracolumbar spine trauma treated through a posterior approach.

Materials and methods: We conducted a retrospective descriptive study including 104 consecutive patients who underwent posterior surgical fixation for thoracolumbar spine fractures at the Department of Neurosurgery, Fattouma Bourguiba University Hospital, Monastir, Tunisia, between January 2018 and December 2023. Demographic, clinical, radiological, operative, and follow-up data were analyzed. Neurological status was assessed using the ASIA grading system, while sagittal alignment was evaluated by measuring the Regional Traumatic Angle (RTA).

Results: The mean age was 40.7 years, with a male predominance (70.2%). Falls from height were the leading cause of injury (67%), followed by road traffic accidents (22%). The thoracolumbar junction (T12–L1) was the most frequently affected level (53%). Type A fractures according to the AO Spine classification represented 58% of cases. Neurological deficits were present in 23 patients, including 13 with complete paraplegia (ASIA A). Mean hospital stay was 5.2 days. Postoperative complications included two surgical site infections (1.9%), one implant malposition requiring revision, one hardware failure, and two cases of progressive post-traumatic kyphosis. No neurological deterioration was observed after surgery. At final follow-up, neurological improvement occurred in 7 of 10 patients with incomplete deficits (ASIA B–D), whereas no recovery was observed in ASIA A patients. Significant correction of sagittal deformity was achieved at the thoracolumbar junction (RTA 10.3° vs. 2.22°, $p < 0.01$). Mortality was 0.96%.

Conclusion: Posterior surgical fixation is a safe and effective strategy for the management of thoracolumbar spine trauma. It provides reliable spinal stabilization, satisfactory correction of sagittal alignment, preservation of neurological function, and meaningful neurological recovery in patients with incomplete deficits, with an acceptable complication rate.

P182 - Post-fusion low back pain: etiologies and management strategies

Rachdi Mohamed Amine, Kammoun T, Bouzouita K, Achoura S, Chkili Ridha, Radhouen K.

Neurosurgery Department, Military Hospital of Tunis, Tunis, Tunisia

Background & objectives: Persistent or recurrent low back pain following lumbar fusion surgery affects a substantial proportion of patients despite radiographically successful arthrodesis, contributing to the entity widely recognized as failed back surgery syndrome. This discordance between structural fusion success and unsatisfactory clinical outcome represents a major challenge in spinal surgery. This review critically examines the principal etiologies of post-fusion low back pain and synthesizes current evidence-based management strategies.

Methods: Narrative review of PubMed, Scopus, and Cochrane databases (2010–2024), including cohort studies, systematic reviews, and clinical guidelines addressing causes, diagnostic workup, and therapeutic management of persistent low back pain following lumbar instrumented fusion.

Results & discussion: Mechanical etiologies: Pseudarthrosis, adjacent segment disease, hardware-related pain, and sagittal malalignment constitute the leading mechanical causes, requiring dedicated imaging (CT, dynamic radiographs) for accurate diagnosis beyond standard postoperative follow-up films. Neuropathic and central etiologies: Epidural fibrosis, residual nerve root compression, and central sensitization contribute significantly to persistent pain independent of structural fusion status, often underrecognized in routine postoperative assessment. Myofascial and biomechanical factors: Paraspinal muscle atrophy and denervation following extensive posterior approaches, sacroiliac joint dysfunction, and altered spinal biomechanics adjacent to the fused segment represent frequently overlooked contributors requiring targeted clinical examination. Management strategies: A stepwise approach is supported by current evidence — multimodal pharmacological management, structured physical therapy emphasizing core stabilization, image-guided diagnostic and therapeutic blocks (facet, sacroiliac, epidural), and neuromodulation (spinal cord stimulation) for refractory neuropathic pain. Revision surgery should be reserved for clearly identified mechanical etiologies, given inconsistent outcomes when performed for unexplained pain. Psychosocial dimension: Preoperative psychological screening and addressing catastrophizing, depression, and unrealistic expectations significantly influence postoperative pain perception and should be integrated into comprehensive management.

Conclusion: Post-fusion low back pain is multifactorial, requiring systematic etiological investigation before treatment escalation. A structured, stepwise, multidisciplinary approach — reserving revision surgery for clearly mechanical causes — optimizes outcomes and avoids unnecessary reoperation.

P183 - Postherpetic neuralgia: pathophysiology and treatment

Kribaa Amina, H.Zireg, O. Abassi, F. Aichaoui, A. Morsli

Mohamed Lamine Debaghine univerty hospital center Algeris ALGERIA

Background: Postherpetic neuralgia (PHN) is a frequent complication of herpes zoster that may develop after the resolution of the skin rash. Its pathophysiology remains poorly understood despite several proposed mechanisms. Management is primarily pharmacological; however, surgical intervention may be considered in refractory cases. We report the outcome of microsurgical DREZotomy in a patient with severe drug-resistant PHN.

Methods: A 69-year-old man presented with chronic postherpetic neuropathic pain localized to the area of a previous herpes zoster eruption. The pain appeared immediately after skin healing and was characterized by electric shock-like sensations, burning pain, and stabbing attacks. Pain intensity was rated 10/10 on the Visual Analog Scale (VAS), with a DN4 score of 7/10. The condition significantly affected mood, daily activities, and sleep quality. The patient remained refractory to optimized medical treatment, including Tramadol, Pregabalin, Carbamazepine, and Amitriptyline. Neurological examination revealed hypoesthesia associated with allodynia in the left T6–T8 dermatomes and hyperesthesia in the left T9 dermatome. Spinal MRI was unremarkable. The patient underwent microsurgical DREZotomy, The procedure consisted of microsurgical DREZ lesioning performed under an operating microscope, involving micro-incisions along the dorsolateral sulcus at the dorsal root entry zone, followed by low-intensity microcoagulation.

Results: A marked reduction in pain was observed immediately after surgery. Improvement of both continuous and paroxysmal pain components exceeded 90%. Analgesic medications were progressively discontinued within three weeks. At 15 months of follow-up, pain relief remained sustained under low-dose tricyclic antidepressant therapy, with persistent improvement in daily functioning and sleep quality.

Conclusions: Postherpetic neuralgia remains a therapeutic challenge, particularly in medically refractory cases. Microsurgical DREZotomy may represent an effective treatment option, providing durable pain relief and functional improvement. Preventive strategies, including vaccination and early antiviral therapy, remain essential to reduce the incidence and severity of PHNter Content Presentation here.

P184 - Postoperative pseudomeningocele and functional recovery: importance of surgical repair and rehabilitation

Mohamed Znazen, A. Hachicha, M. Taallah, H. Belmabrouk,
Department of Neurosurgery, University Hospital of Gabès, Tunisia

Introduction: Spinal pseudomeningocele (PM) is defined as an extradural collection of cerebrospinal fluid (CSF) within the soft tissues, communicating with the subarachnoid space through a dural defect of traumatic, congenital, or iatrogenic origin. Postoperative PM is a rare complication following spinal surgery, such as laminectomy or discectomy, with an incidence ranging from 0.3% to 13%. It predominantly occurs in the lumbar region. The incidence increases to 5–6% in patients undergoing intradural procedures, particularly for tumors such as neurinomas. Clinical manifestations vary widely, ranging from an asymptomatic subcutaneous mass to signs of spinal cord compression.

Methods: We report the case of a 54-year-old patient with no significant medical history who underwent surgical resection of a T11 dorsal neurinoma, initially presenting with isolated back pain without neurological deficits, spinal claudication, or sphincter dysfunction.

Results: One month postoperatively, the patient developed a painful subcutaneous swelling at the surgical site associated with progressive lower limb weakness. Magnetic resonance imaging was performed to evaluate the postoperative complication. MRI demonstrated a large extradural and subcutaneous cerebrospinal fluid collection with a “dumbbell-shaped” configuration at the T11–T12 level, in continuity with the dural sac, consistent with a postoperative pseudomeningocele. The patient underwent surgical revision, including evacuation of the pseudocyst, identification and primary repair of the dural defect, and reinforcement with biological sealant. The postoperative course was uneventful. Clinical outcome was favorable, with significant neurological improvement and progressive functional recovery under rehabilitation.

Conclusions: Postoperative pseudomeningocele is a rare but potentially serious complication of spinal surgery. Clinical presentation is often variable and may be subtle. Early postoperative magnetic resonance imaging plays a key role in diagnosis. Treatment should be individualized based on clinical and radiological findings. This case emphasizes the importance of meticulous dural closure in preventing this complication and highlights the role of postoperative rehabilitation in functional recovery.

P185 - Post-traumatic epilepsy in personal injury assessment: medico-legal considerations

Hadjazi Omar, Merad Yassine

University Hospital of SIDI BEL ABBES, Algeria

Background: Post-traumatic epilepsy (PTE) is a well-recognized complication of traumatic brain injury and represents an important issue in personal injury assessment. From a medico-legal perspective, establishing the causal relationship between head trauma and subsequent epileptic seizures remains a complex task, particularly when the clinical history or diagnostic data are incomplete. Accurate evaluation is essential for determining long-term disability and compensation.

Methods: This communication reviews the medico-legal aspects of post-traumatic epilepsy in the context of personal injury evaluation. The analysis focuses on the mechanisms and risk factors associated with the development of epilepsy following traumatic brain injury, as well as the diagnostic criteria used to establish a causal link between trauma and seizures. Particular attention is given to the temporal relationship between trauma and seizure onset, the severity of the initial injury, neuroimaging findings, electroencephalographic data, and the exclusion of alternative etiologies.

Results: Post-traumatic epilepsy occurs more frequently after moderate to severe traumatic brain injury, especially in the presence of cerebral contusions, intracranial hemorrhage, depressed skull fractures, or penetrating injuries. The latency period between trauma and seizure onset may vary widely, ranging from months to several years. From a medico-legal standpoint, the evaluation requires a comprehensive review of medical records, clinical history, and complementary investigations in order to support or refute the causal relationship between the traumatic event and the epileptic disorder.

Conclusions: Post-traumatic epilepsy represents a significant challenge in personal injury assessment due to the complexity of causal attribution and the potential long-term functional consequences. A rigorous medico-legal evaluation based on clinical, radiological, and electrophysiological data is essential to ensure an objective assessment of causality and disability.

P186 - Post-traumatic intracranial pseudoaneurysm: a case report and review of the literature.

Saddem Messai, Mechiche Zohir, Mahdaoui Rima, Hallaci Azeddine.

Neurosurgery Department, Setif, Algeria .

Introduction: Post-traumatic aneurysms represent less than 1% of intracranial aneurysms and are more frequent in children. Their unpredictable progression carries a risk of fatal rupture. The role of imaging is paramount for both diagnosis and potential therapeutic intervention. We report a case of a post-traumatic aneurysm of the superior sagittal sinus.

Objective: To establish a prompt diagnosis in order to improve the quality of management and the overall prognosis.

Methods: A 4-year-old child presented to the emergency department unconscious following a traumatic brain injury caused by a 4-meter fall. A contrast-enhanced brain CT scan revealed a bilateral frontal extradural hematoma associated with a pseudoaneurysm of the anterior third of the superior sagittal sinus and a right frontal fracture. Intraoperatively, during the evacuation of the extradural hematoma, a breach of the superior sagittal sinus spanning approximately 2 cm was discovered, accompanied by significant bleeding, which was successfully repaired. The postoperative CT angiography showed the complete resolution of both the extradural hematoma and the pseudoaneurysm.

Results: Postoperatively, the child was extubated 48 hours after the surgical procedure and demonstrated a favorable clinical recovery.

Conclusion: Despite their rarity, post-traumatic intracranial aneurysms should be suspected in any patient with recent or past traumatic brain injury. This warrants urgent angiographic evaluation before considering radical treatment, whether through a surgical or an endovascular approach.

P187 - Post-traumatic trans-ethmoidal foreign body with cribriform plate osteomeningeal defect, meningoencephalocele, and frontal cerebral abscess in a child: staged endoscopic endonasal removal and multilayer fascia lata reconstruction — a case report

Dergham Djamel Eddine, N.Baz, A.Chabat, S.Benallag, K.Bouaita

Department of neurosurgery, neurosurgery hospital Cherchall, Algeria

Background: Post-traumatic anterior skull base defects in children are rare, insidious, and potentially fatal. Penetrating trans-ethmoidal foreign bodies are exceptionally uncommon in the pediatric population and may silently create a persistent osteodural breach, leading to ascending intracranial infectious complications such as meningoencephalocele, epidural empyema, and cerebral abscess. Endoscopic endonasal surgery is an effective approach for anterior skull base reconstruction with low morbidity.

Methods: A 5-year-old boy sustained craniofacial trauma at age 4, resulting in a trans-ethmoidal penetrating foreign body and a left cribriform plate osteomeningeal defect measuring 6 × 3 mm. He subsequently developed ascending bacterial meningitis, a left frontal cerebral abscess measuring 40 × 28 × 42 mm, and an anterior epidural empyema with meningoencephalocele at the cribriform plate defect. After emergency neurosurgical abscess drainage and complete infection control, elective endoscopic endonasal removal of the foreign body was performed, followed by multilayer skull base reconstruction using a fascia lata onlay graft secured with biological fibrin glue and a mucosal rotation flap.

Results: The postoperative course was uneventful. The patient recovered without complications and was discharged on postoperative day 2.

Conclusions: This case highlights the catastrophic infectious potential of an unrecognized trans-ethmoidal foreign body in a young child and supports systematic multimodal skull base imaging in pediatric patients with intracranial infection after craniofacial trauma. A staged multidisciplinary strategy combining acute infection control with delayed endoscopic endonasal reconstruction can achieve excellent outcomes.

P188 - Pre and postoperative brain imaging in moya-moya disease: a case report

Ben Amor Wajdi, Dkhil Insaf, Ghedira Khalil, Jelassi Soumaya, Belakhel Amine, Abderrahmen Khansa, Hammemi Nadia, Neji Sonia.

Department of Neurosurgery, National Institute of Neurology, Tunis, Tunisia
Department of Radiology, National Institute of Neurology, Tunis, Tunisia

Introduction: Moya-Moya disease is a chronic, progressive steno-occlusive cerebrovascular disorder involving the terminal internal carotid arteries and the development of compensatory collateral vessels. Multimodal brain imaging is essential for diagnosis, disease staging, surgical planning, and postoperative assessment. We report the contribution of pre- and postoperative imaging in a patient undergoing direct cerebral revascularization.

Methods: A 47-year-old woman with Moya-Moya disease and recurrent ischemic strokes despite antiplatelet therapy underwent preoperative brain MRI and digital subtraction angiography. Imaging findings were correlated with surgical results and postoperative angiographic evaluation following direct extracranial-to-intracranial bypass using an anastomosis between the superficial temporal artery and a cortical M4 branch of the left middle cerebral artery.

Results: Preoperative MRI demonstrated a subacute ischemic infarction in the left temporo-occipital region, bilateral chronic ischemic lesions within the deep white matter, and steno-occlusive involvement of the left internal carotid and vertebrobasilar territories. Vascular imaging revealed extensive cortical and perforating collateral circulation, consistent with advanced Moya-Moya disease. Postoperative angiography showed a thread-like left internal carotid artery with absent opacification of the carotid terminus and partial filling of the middle cerebral artery through a fine network of collateral arterioles, producing the characteristic “puff of smoke” appearance. The extracranial-to-intracranial bypass between the superficial temporal artery and the M4 cortical branch of the middle cerebral artery remained patent, confirming successful direct revascularization and restoration of cerebral perfusion.

Conclusion: This case highlights the pivotal role of multimodal imaging in the management of Moya-Moya disease. MRI accurately characterizes ischemic brain injury and vascular involvement, whereas digital subtraction angiography remains the reference standard for evaluating collateral circulation and bypass patency after revascularization. Comprehensive imaging is therefore indispensable for therapeutic decision-making and postoperative follow-up in patients with Moya-Moya disease.

P189 - Precocious puberty revealing a craniopharyngioma : a pediatric case report

Hamza Bouchekoura, C. Handis, A. Morsli.

Mohamed Lamine Debaghine University Hospital, Bab el oued, Algiers, Algeria.

Background: Craniopharyngiomas are rare benign epithelial tumors arising in the sellar and suprasellar region and account for approximately 5–10% of pediatric intracranial tumors. They usually present with visual impairment, symptoms of increased intracranial pressure, growth retardation, or endocrine dysfunction. Central precocious puberty is an exceptionally rare presenting feature and may complicate the diagnostic process. We report a pediatric case of craniopharyngioma revealed by central precocious puberty.

Methods: We retrospectively reviewed the clinical presentation, endocrine investigations, neuroimaging findings, surgical management, and histopathological results of a child referred for evaluation of gonadotropin-dependent precocious puberty. Magnetic resonance imaging of the hypothalamic-pituitary region was performed, followed by surgical treatment and pathological examination.

Results: An 8-year-old child presented with progressive early pubertal development in the absence of visual or neurological symptoms. Hormonal assessment confirmed central precocious puberty. Brain MRI demonstrated a heterogeneous sellar-suprasellar lesion with mixed cystic and solid components and evidence of hypothalamic involvement. The radiological differential diagnosis included craniopharyngioma and germinoma. The patient underwent endoscopic endonasal resection. Histopathological analysis confirmed an adamantinomatous craniopharyngioma. Postoperative recovery was uneventful, with preservation of neurological function and satisfactory endocrine status. Early postoperative MRI revealed no residual tumor or evidence of recurrence.

Conclusions: Although endocrine disturbances are common in pediatric craniopharyngioma, central precocious puberty is an uncommon initial manifestation. This atypical presentation may delay diagnosis and mimic other suprasellar lesions, particularly germinomas. Neuroimaging should be systematically considered in children presenting with central precocious puberty to exclude underlying hypothalamic-pituitary pathology. Early diagnosis and multidisciplinary management are essential to optimize surgical, endocrine, and long-term outcomes.

P190 - Predicting recovery after subaxial cervical spine trauma: which factors really matter?

Mohamed Amine Hmida, M. Ben Messaoud, M. Berkache, O. Hattab, I. Ksira

Department of Neurosurgery, Sahloul Hospital, Sousse, Tunisia.

Introduction: Neurological outcomes following subaxial cervical spine trauma (C3–C7) remain highly variable. While surgical stabilization can often restore mechanical stability, neurological recovery depends on a complex interplay of biological, radiological, and therapeutic factors. Early identification of prognostic indicators is crucial for patient counseling, treatment planning, and rehabilitation strategies.

Objective: To identify clinical, radiological, and therapeutic factors associated with neurological recovery at six months following subaxial cervical spine trauma.

Materials and methods: We conducted a retrospective descriptive and analytical study of 34 patients treated for subaxial cervical spine injuries. Variables analyzed included age, initial American Spinal Injury Association (ASIA) grade, injury level, MRI findings (spinal cord edema versus intramedullary hemorrhage), timing of surgical intervention, and associated comorbidities. The primary outcome measure was neurological improvement defined as an increase of at least one ASIA grade after a minimum follow-up of six months.

Results: Multivariate analysis identified several significant prognostic factors. The initial neurological status emerged as the strongest predictor of recovery. Among patients with incomplete spinal cord injuries (ASIA B, C, or D), 68.4% demonstrated significant neurological improvement. In contrast, only 12.5% of patients with complete injuries (ASIA A) achieved meaningful motor recovery. Preoperative MRI findings provided substantial prognostic value. Intramedullary hemorrhage was consistently associated with poor neurological outcomes and absence of significant recovery, whereas isolated spinal cord edema was associated with a more favorable prognosis. Therapeutic factors also influenced outcomes. Early surgical decompression, commonly performed within the first 24 hours after injury, correlated with superior neurological recovery and improved functional status at follow-up. Demographic factors played an additional role, with younger patients and those without major associated systemic injuries demonstrating greater recovery potential and more effective rehabilitation outcomes.

Conclusion: Neurological recovery after subaxial cervical spine trauma is multifactorial. Initial ASIA grade and MRI evidence of intramedullary hemorrhage provide the strongest baseline prognostic information. However, early surgical decompression remains the principal modifiable factor available to clinicians and may significantly improve neurological outcomes. These findings support aggressive early management and comprehensive prognostic assessment in patients with cervical spinal cord injury.

P191 - Predicting surgical site infection after thoracolumbar spine surgery using machine learning : an explainable approach

Syrine Saadoun, Mm.Hadhri, I.Ferchichi, N.Yahyaoui, M.Darmoul

Neurosurgery Department, Fattouma Bourguiba University hospital, Monastir, Tunisia.

Background: Surgical site infection (SSI) after thoracolumbar spine fixation is an uncommon but potentially serious complication. Predicting rare complications, such as SSI, remains challenging because of their multifactorial nature and the complex interactions among patient-related and perioperative variables.Integrating explainable machine learning models provides clinically relevant insights by identifying patient-specific risk factors, enabling targeted interventions on modifiable variables and improving perioperative decision-making.

Methods: A balanced random forest model was developed to predict SSI using selected clinical and perioperative variables. The dataset was updated with recent SSI-positive cases recorded up to April 2026. Model performance was evaluated using stratified five-fold cross-validation. Discrimination was assessed by ROC-AUC, precision-recall performance by average precision, and calibration by the Brier score. SHAP analysis was used to explain individual predictions.

Results: A total of 235 patients were included, of whom 24 developed SSI. The model showed moderate discriminative performance, with a ROC-AUC of 0.623, an average precision of 0.135, and a Brier score of 0.158. At the selected threshold of 0.24, sensitivity was 95.8%, specificity 28.9%, positive predictive value 13.3%, and negative predictive value 98.4%. SHAP provided patient-specific explanations and helped identify modifiable risk contributors.

Conclusion: This study demonstrates the feasibility of an explainable machine learning model for SSI prediction after thoracolumbar spine fixation. Despite limited sample size and moderate performance, the model may serve as a screening and decision-support tool. Its integration into a web application represents a step toward personalized perioperative risk assessment..

P192 - Predicting survival in acute subdural hematoma: which factors truly matter?

Majdouline Barkache, R. Benfredj, S. Galaoui, H. Kammoun, I.Ksira

Department of Neurosurgery, Sahloul Hospital, Sousse, Tunisia

Background: Acute subdural hematoma (ASDH) is a life-threatening neurosurgical emergency with high mortality and variable functional outcomes. Despite advances in neurocritical care and surgical management, prognosis remains largely dependent on early clinical and radiological severity. Identifying reliable predictors of survival is essential for decision-making and family counseling.

Methods: A retrospective study was conducted including 56 patients admitted with acute subdural hematoma between 2021 and 2023. Clinical, radiological, and therapeutic variables were analyzed. Data collected included age, Glasgow Coma Scale (GCS) at admission, pupillary reactivity, anticoagulant use, hematoma thickness, midline shift, associated intracranial lesions, and timing of surgical intervention. Survival at discharge was used as the primary outcome. Univariate and multivariate analyses were performed to identify independent predictors of mortality.

Results: Overall mortality remained high in this cohort. Lower admission GCS was strongly associated with poor survival. Radiological severity, particularly significant midline shift and larger hematoma thickness, correlated with worse outcomes. Bilateral or non-reactive pupils were also significant predictors of mortality. Associated brain injuries, including contusions and diffuse cerebral edema, further increased risk. Early surgical evacuation was associated with improved survival in selected patients, particularly those with moderate neurological impairment at presentation, whereas extremely low GCS scores were linked to poor outcomes despite surgery. On multivariate analysis, admission GCS and pupillary reactivity emerged as the strongest independent predictors of survival.

Conclusion: In acute subdural hematoma, survival is primarily determined by initial neurological status and radiological severity. While surgery remains a cornerstone of management, its benefit is highly dependent on early clinical condition. Rapid assessment of GCS, pupillary response, and imaging findings is essential to guide treatment decisions and improve outcome stratification.

P193 - Predictors of functional recovery after posterior fossa tumor surgery in children

Majdouline Barkache, M. Ben Messaoud, H. Kamoun, I. Ksira

Department of Neurosurgery, Sahloul Hospital, Sousse, Tunisia

Background: Surgical resection is the cornerstone of treatment for pediatric posterior fossa tumors. Although survival has improved substantially, postoperative functional recovery remains highly variable. Identifying factors associated with favorable neurological recovery may improve surgical decision-making, postoperative counseling, and rehabilitation planning.

Methods: A retrospective study was conducted on children who underwent posterior fossa tumor resection between 2012 and 2022 at our institution. Clinical presentation, tumor characteristics, radiological findings, surgical data, and postoperative outcomes were reviewed. Functional recovery was defined as improvement in neurological status and return to age-appropriate daily activities within six months after surgery. Clinical and radiological variables associated with favorable recovery were analyzed.

Results: A total of 45 children (mean age 7.2 ± 3.8 years) were included. At six months, 31 patients (68.9%) achieved favorable functional recovery. Significant improvement was observed in gait disturbances (71%), headache (76%), cerebellar signs (63%), and cranial nerve deficits (58%). Postoperative cerebellar mutism occurred in 10 patients (22.2%), leading to delayed recovery but not permanent disability in most cases. Favorable recovery was significantly associated with younger age (<10 years) (p=0.03), absence of severe preoperative neurological deficits (p=0.01), limited brainstem compression (p=0.02), and resolution of postoperative hydrocephalus (p=0.01). Tumor histology and extent of resection were not independently associated with functional outcome.

Conclusion: Most children experience substantial neurological recovery following posterior fossa tumor surgery. Functional outcome depends more on preoperative neurological status and brainstem involvement than on tumor histology or extent of resection. Early diagnosis, timely surgery, and structured postoperative rehabilitation remain essential to maximize long-term functional recovery in pediatric patients.

P194 - Prehospital management and prognostic factors in spontaneous subarachnoid hemorrhage: a retrospective study

Balkis Essid, F.Kolsi, M. Ben Abdallah, K. Ayedi, F. Gahbiche, M. Tallah, S. Abdelmoulah, M. Borni, S. Chaari, B. Kammoun, M.Z. Boudawara.

Department of Neurosurgery, Hbib Bourguiba University Hospital, Sfax , Tunisia

Background: Spontaneous subarachnoid hemorrhage (SAH) is a severe neurological emergency with high morbidity and mortality. Early recognition and prehospital management are critical but remain understudied.

Methods: We conducted a retrospective descriptive and analytical study including 61 patients hospitalized for spontaneous SAH between January 2022 and September 2025 at Habib Bourguiba University Hospital, Sfax. Data were collected from neurosurgical records and SAMU 04 (Emergency Medical Assistance Service). Univariate analysis identified factors associated with complications (motor deficit, hydrocephalus, rebleeding, meningitis, death).

Results: Median age was 54 years (range 12–95), with a slight female predominance (sex ratio 0.9). Only 31.1% of patients were transported by SMUR; 62.3% used self-transport. Headache was the main symptom (91.8%), thunderclap in nature. Complications occurred in 32.8% (n=20): motor deficit (14.7%), hydrocephalus (9.8%), rebleeding (4.9%), meningitis (1.6%), and death (3.3%). Significant predictors of complications were initial loss of consciousness (OR=26.6; $p<0.001$), seizures (OR=22.6; $p=0.009$), and GCS <13 (OR=17.14; $p=0.004$). CT angiography was associated with reduced complication risk (OR=0.25; $p=0.049$).

Conclusions: Early clinical severity signs—altered consciousness, seizures, and low GCS—strongly predict complications in spontaneous SAH. Strengthening prehospital recognition and early vascular imaging may improve patient outcomes.

P195 - Prenatal repair of myelomeningocele: outcomes and perspectives in low- and middle-income countries

Emna Elouni, Emna Mzoughi, Sofiene Bouali, Roua Latrach, Khalil Ghedira, Khansa Abderrahmene, Asma Bouhoula, Jalel Kallel

Neurosurgery Departement, National Institute of Neurology, Tunis, Tunisia

Background: Open spina bifida (myelomeningocele) is a severe neural tube defect associated with significant neurological morbidity. Prenatal surgical repair has emerged as a therapeutic option following the landmark Management of Myelomeningocele Study (MOMS), demonstrating improved fetal outcomes compared to postnatal repair. However, its applicability in low- and middle-income countries (LMICs) remains limited due to structural, economic, and ethical constraints.

Methods: We conducted a narrative review of the current literature on intrauterine repair of myelomeningocele, focusing on neurological outcomes, maternal risks, and implementation challenges. Particular attention was given to disparities in access to fetal surgery and perspectives for LMIC settings.

Results: Prenatal repair has been associated with reduced need for cerebrospinal fluid shunting, improved motor outcomes, and partial reversal of hindbrain herniation compared to postnatal surgery. The MOMS trial demonstrated significant fetal benefit at the cost of increased maternal and obstetric risks, including uterine dehiscence and preterm delivery. Despite these advantages, widespread implementation remains restricted to high-income countries with specialized multidisciplinary fetal surgery centers. In LMICs, late diagnosis, limited prenatal screening, lack of fetal surgery infrastructure, and financial constraints significantly limit access. Consequently, postnatal repair remains the standard of care. Prevention through folic acid supplementation and improvement of neonatal neurosurgical care represent the most impactful strategies in these settings.

Conclusions: Prenatal repair of myelomeningocele offers clear neurological benefits but is currently not widely feasible in LMICs due to infrastructural and economic limitations. Bridging this gap requires prioritizing prevention programs, strengthening postnatal surgical care, and developing regional fetal surgery centers through international collaboration. Equity in access to advanced fetal neurosurgical techniques remains a major global health challenge.

P196 - Primary bilateral occipital cerebral hydatid cysts: a rare case report and surgical management

Safaa Ben Yagoub, Med Aziz Hermassi, Maila Bounemra, Aziz Bedioui, Ghassen Gader, Mouna Rkhami, Mohamed Badri, Kamel Bahri, Ihsen Zammel

Department of Neurosurgery, Ben Arous Trauma Center, Tunisia

Introduction: Cerebral hydatidosis is a rare manifestation of Echinococcus granulosus infection, accounting for approximately 2% of all hydatid disease localizations, with even lower incidence in adults. While solitary supratentorial cysts represent the most frequently reported intracranial presentation, bilateral and multiple cerebral involvement is exceptionally uncommon, particularly in the occipital region. The pathogenetic mechanisms underlying primary multiple bilateral cerebral hydatid cysts remain incompletely understood, and their management poses unique surgical challenges. We report a rare case of primary bilateral occipital hydatid cysts, highlighting the diagnostic workup and operative strategy employed.

Case report: A 36-year-old Tunisian male with no significant medical history presented with progressive headaches and visual impairment. Neurological examination revealed bilateral reduction in visual acuity without other focal deficits. Cranial MRI demonstrated two well-defined, thin-walled, non-enhancing cystic lesions with fluid signal intensity isointense to cerebrospinal fluid, located bilaterally in the occipital regions, consistent with primary cerebral hydatid cysts. Serological testing supported the diagnosis. Thoracic and abdominal imaging excluded systemic involvement, confirming the primary intracranial nature of the disease. The patient underwent surgical excision of both cysts through two sequential craniotomies performed within a single operative session. The Dowling technique was employed, using continuous saline irrigation to hydrodissect the cysts intact from the surrounding cerebral parenchyma, thereby avoiding intraoperative rupture and the associated risks of anaphylaxis and perioperative dissemination.

Discussion: Primary multiple bilateral cerebral hydatid cysts are exceedingly rare, even in endemic regions such as North Africa. MRI remains the gold standard for diagnosis, providing superior characterization of cyst architecture and anatomical relationships. Surgical excision constitutes the definitive treatment, with intact cyst removal being paramount to preventing recurrence and life-threatening anaphylactic complications. Postoperative albendazole therapy is recommended to reduce recurrence risk.

Conclusion: This case underscores the importance of considering cerebral hydatidosis in patients from endemic regions presenting with intracranial cystic lesions, and highlights that bilateral occipital involvement, though rare, is surgically manageable with meticulous operative technique and comprehensive perioperative care.

P197 - Primary isolated spinal pilomyxoid astrocytoma without intracranial involvement: a rare pediatric case and literature review

Ines Ferchichi, Mohamed Amine Hadj Taieb, Syrine Saadoun, Alaeddine Chaabene, Mehdi Darmoul

Neurosurgery Department, Fattouma Bourguiba University hospital, Monastir, Tunisia.

Background: Pilomyxoid astrocytoma (PMA) is a rare pediatric glial neoplasm that most commonly arises in the hypothalamic–chiasmatic region and is considered to have a more aggressive clinical course than pilocytic astrocytoma. Primary spinal PMA without any associated intracranial lesion is exceptionally uncommon, with only 17 cases previously reported in the English-language literature. Because of this extreme rarity, the natural history, radiologic features, and optimal treatment strategy for isolated spinal PMA remain incompletely understood. We report a new pediatric case and summarize the available literature to better characterize this unusual entity.

Methods: A 3-year-old boy presented with progressive motor weakness, gait difficulty, and torticollis. Neurological examination suggested cervical spinal cord involvement. Magnetic resonance imaging of the spine revealed a long-segment intramedullary lesion extending from C7 to T5, with heterogeneous enhancement and cord expansion. Brain imaging showed no evidence of intracranial disease. The patient underwent subtotal microsurgical resection with the aid of intraoperative neurophysiological monitoring to maximize tumor removal while preserving neurological function. Histopathological examination and immunohistochemical profiling confirmed the diagnosis of pilomyxoid astrocytoma. Following surgery, adjuvant chemotherapy was initiated. In addition, a focused review of previously published cases of isolated spinal PMA was performed.

Results: The postoperative course was uncomplicated, and the patient demonstrated gradual neurological recovery during follow-up. At 1 year after surgery, magnetic resonance imaging showed stable residual tumor without radiographic progression or new intracranial lesions. Review of the literature identified only 17 prior cases of isolated spinal PMA without brain involvement, making the present case the 18th reported example. Reported patients have varied in age, tumor extent, and treatment approach, but most required subtotal resection because of the infiltrative nature of the lesion and the risk of neurological injury. These findings underscore both the rarity of this diagnosis and the limited evidence available to guide management decisions.

Conclusions: Isolated spinal PMA is a rare pediatric spinal cord tumor that may behave more aggressively than pilocytic astrocytoma. Complete surgical excision is often not feasible because of the tumor's infiltrative growth pattern and the need to preserve neurological function. In such cases, adjuvant therapy should be considered on an individualized basis. Careful long-term surveillance is essential because the biological behavior of this entity remains uncertain. Additional case reports, pooled analyses, and multicenter studies with extended follow-up are needed to clarify prognosis and establish evidence-based treatment strategies for children with isolated spinal PMA.

P198 - Primary spinal mesenchymal chondrosarcoma: a rare malignant tumor with aggressive clinical course

Hamid Khay, Mohamed Dahamou, Mohammed Al Amine El Farissi, Mohammed Khoulali

University hospital Center Mohammed VI Oujda, Morocco

Background: Mesenchymal chondrosarcoma is a rare, high-grade malignant subtype of chondrosarcoma accounting for a small proportion of primary bone tumors. Spinal involvement is uncommon and represents a significant diagnostic and therapeutic challenge because of its aggressive behavior, high metastatic potential, and lack of standardized treatment guidelines.

Case presentation: A 16-year-old female presented with a one-month history of progressive bilateral lower-limb weakness and urinary dysfunction. Neurological examination demonstrated upper motor neuron syndrome with paraparesis, hyperreflexia, Babinski sign, and a sensory level at the umbilicus. Magnetic resonance imaging revealed an extradural thoracic spinal mass extending from T7 to T9 with marked contrast enhancement and spinal cord compression. Whole-body computed tomography demonstrated hilar lymphadenopathy. The patient underwent T7–T9 laminectomy with gross total tumor resection, posterior spinal fixation, and histopathological examination. Microscopy showed sheets of small round and oval atypical cells associated with well-differentiated cartilaginous islands, while immunohistochemistry demonstrated CD99 positivity, confirming the diagnosis of mesenchymal chondrosarcoma. Postoperatively, neurological function improved markedly, and the patient received adjuvant radiotherapy followed by multi-agent chemotherapy. Two years later, imaging demonstrated no local recurrence. However, six months afterward, she developed rapid neurological deterioration caused by recurrent thoracic disease and metastatic involvement of L1. A second decompressive procedure was performed, but subsequent imaging revealed pulmonary, peritoneal, and abdominal metastatic dissemination. Despite palliative chemotherapy, the patient died six months later.

Discussion: Primary spinal mesenchymal chondrosarcoma is an exceptionally rare neoplasm with a high risk of local recurrence and distant metastasis despite aggressive multimodal therapy. Histopathological and immunohistochemical analyses remain essential for definitive diagnosis. Gross total surgical resection remains the cornerstone of treatment, whereas the survival benefit of adjuvant chemotherapy and radiotherapy remains uncertain.

Conclusion: This case illustrates the highly aggressive nature of spinal mesenchymal chondrosarcoma and emphasizes the importance of early diagnosis, radical surgical resection, multidisciplinary management, and prolonged surveillance because of the substantial risk of late recurrence and metastatic progression.tation du contenu

P199 - Printing the perfect skull: a narrative review of 3D-printed custom cranioplasty materials and techniques

Ameur Affes, Barkache M, Akrout F, Rachdi MA, Kammoun T, Farhat S, Chkili R, Radhouen K

Neurosurgery Department, Military Hospital of Tunis, Tunis, Tunisia

Background & objectives: Cranioplasty has evolved far beyond the simple reimplantation of autologous bone. The advent of 3D printing technology has introduced a new era of patient-specific implants, enabling precise anatomical reconstruction, reduced operative time, and improved aesthetic and functional outcomes. However, the rapidly expanding landscape of printable biomaterials — including titanium, polyetheretherketone (PEEK), hydroxyapatite, and composite scaffolds — creates significant uncertainty regarding optimal material selection. This review appraises current evidence on 3D-printed custom cranioplasty implants, comparing materials, techniques, clinical outcomes, and emerging innovations.

Methods: Narrative review of PubMed, Scopus, and Cochrane databases (2010–2024), including prospective and retrospective studies, case series, and biomechanical analyses evaluating 3D-printed cranioplasty implants across all printable material categories.

Results & discussion: Titanium: Laser sintered titanium mesh implants offer exceptional mechanical strength, osseointegration potential, and radiolucency on imaging. Infection rates remain low (3–7%), though thermal conductivity and artifact generation on MRI represent persistent limitations. PEEK: Thermoplastic PEEK implants demonstrate superior biomechanical compatibility, MRI transparency, and infection resistance. Patient-specific PEEK cranioplasty consistently achieves excellent cosmetic outcomes with complication rates below 8%, establishing it as the current benchmark for complex reconstructions. Hydroxyapatite and bioactive composites: Osteoconductive ceramic-based implants promote native bone ingrowth but remain mechanically inferior and fragile, limiting their application to non-load-bearing defects in selected patients. Hybrid and smart implants: Emerging composite scaffolds combining PEEK frameworks with hydroxyapatite coatings or drug-eluting surfaces represent the next frontier, aiming to combine mechanical reliability with biological integration and infection prophylaxis. Limitations: High fabrication costs, regulatory heterogeneity, and absence of prospective randomized comparisons between materials limit definitive recommendations.

Conclusion: 3D-printed custom cranioplasty represents a genuine surgical revolution, transforming skull reconstruction from an approximation into a precision procedure. PEEK currently leads the evidence base, while bioactive composites define the horizon. Standardized outcome reporting and prospective comparative trials are now essential.

P200 - Prognosis of cystic gliomas: from pascal's hydrodynamics to WHO CNS5 molecular profiling

Ines Keddari, Maghni I., Raoud A., Gasmi N.

Department of Neurosurgery, Hassani Abdelkader University Hospital, Sidi Bel Abbes, Algeria

Introduction: The prognostic value of the cystic component in adult gliomas remains a major debate in neurosurgery. While clinical practice often suggests better survival rates, recent studies show divergent results. This study proposes an innovative approach by integrating fluid mechanics and modern molecular oncology to explain the "cystic phenomenon."

Material and methods: We combined a theoretical hydrodynamic analysis based on Pascal's law with a clinical and molecular evaluation (according to the WHO CNS5 classification) of a cystic glioblastoma case. The impact of intracystic pressure transmission on the early onset of symptoms was compared against molecular markers (IDH, MGMT, Ki-67).

Results: The Physics of Diagnosis: According to Pascal's law, pulsatile pressures from the parenchyma are transmitted fully to the cystic fluid, creating a spherical expansion force. This force increases local tissue pressure more rapidly than in solid tumors, causing early symptomatology. This premature diagnosis mathematically induces prolonged survival (lead-time bias). Molecular Integration: Analysis of an IDH-wildtype glioblastoma (grade 4) case shows that, despite biological aggressiveness (high Ki-67), the cystic configuration facilitated a near-total gross total resection (GTR) thanks to effective surgical decompression. Therapeutic Implications: Cysticity does not replace molecular biology. Management of the cystic wall must be guided by imaging (searching for tumor nodules) and the molecular profile (MGMT status, PDGFRA) to optimize adjuvant protocols.

Conclusion: The apparent better prognosis of cystic gliomas is not solely biological, but also mechanical. The cyst acts as a "pressure amplifier" promoting early diagnosis. However, long-term management must remain strictly dictated by the integrated WHO CNS5 molecular classification, as cysticity can mask highly heterogeneous genetic profiles.

P201 - Prognostic factors influencing functional recovery after posterolateral fusion for isthmic spondylolisthesis

Rami Ben Mhenni, Guermazi Ahmed[2], Hamdi Kaziz[1], Mohamed Amine Hmida[2], Aymen Hanafi[1], Mourad Mtaoumi[1], Mohamed Ali Khalifa[1], Karim Bouattour[1]

[1] Department of Orthopaedic Surgery and Traumatology, Sahloul University Hospital, Sousse, Tunisia.

[2] Department of neurosurgery, Sahloul University Hospital, Sousse, Tunisia.

Background: Optimizing patient selection for posterolateral fusion (PLF) in isthmic spondylolisthesis requires identifying reliable prognostic factors. Age, obesity, pathological level, and sagittal morphotype have been proposed as outcome modifiers; however, their individual contributions remain poorly characterized in North African populations. This study systematically evaluates their impact on functional recovery.

Methods: Subgroup analyses were performed on a retrospective cohort of 34 adults treated by instrumented PLF (2010–2024). Functional outcomes — JOA score, Oswestry Disability Index (ODI), and Visual Analogue Scale (VAS) — were compared according to: age (≤50 vs. >50 years), BMI (<30 vs. ≥30 kg/m²), pathological level (L4–L5 vs. L5–S1), Roussouly morphotype (Types I–II vs. III–IV), and follow-up duration (<5 vs. >5 years). Student's t-test and Fisher's exact test were applied (significance threshold $p < 0.05$).

Results: BMI ≥30 kg/m² was the sole variable independently associated with significantly inferior JOA recovery (19.9 vs. 23.0; $p = 0.039$). Age, pathological level, and Roussouly morphotype showed no statistically significant influence on any functional endpoint (all $p > 0.09$). Notably, long-term follow-up (>5 years) did not result in functional deterioration compared to shorter follow-up (JOA: 23.2 vs. 21.0; ODI: 26.8% vs. 27.2%; VAS: 3.7 vs. 3.7; all $p > 0.09$), confirming sustained outcome durability.

Conclusions: Obesity is the only modifiable factor significantly impairing neurological recovery after PLF for isthmic spondylolisthesis. PLF delivers consistent functional benefit regardless of patient age, affected spinal level, or preoperative sagittal morphotype, underscoring its broad applicability. Perioperative weight optimization represents an actionable lever for outcome improvement. Multicentric prospective studies are needed to validate these findings.

P202 - Prognostic factors of tumor recurrence and visual outcome after surgery for non-functioning pituitary adenomas

Emna Mzoughi, Hajji B, Gallaoui S, Trifa A, Darmoul M, Zammel I, Kallel J

Department of Neurosurgery, Hospital of Fattouma Bourguiba, Monastir , Tunisia .
Department of Neurosurgery, Burns and Trauma Center, Ben Arous , Tunisia.
Department of neurosurgery , National Institute of Neurology, Tunisia.

Background: Despite advances in pituitary surgery, tumor recurrence, postoperative visual recovery, and surgical morbidity remain major concerns in the management of non-functioning pituitary adenomas. Identifying prognostic factors is essential to guide surgical strategy, optimize follow-up, and select patients who may require adjuvant treatment.

Methods: This retrospective multicenter study analyzed 95 patients operated on for non-functioning pituitary adenomas over a six-year period. Clinical, radiological, surgical, and postoperative variables were evaluated. Prognostic factors associated with tumor recurrence, visual outcome, and postoperative complications were analyzed, with particular attention to age, Knosp grade, surgical technique, and extent of resection.

Results: Tumor recurrence was not significantly associated with age. However, cavernous sinus invasion assessed by the Knosp classification was significantly associated with recurrence, with higher recurrence rates in patients with Knosp grade greater than 2. The extent of resection also had a significant prognostic impact, as incomplete resection was associated with a higher risk of postoperative recurrence. In contrast, no significant difference in recurrence was observed between endoscopic and microscopic surgical approaches. Regarding visual outcome, age, Knosp grade, surgical technique, and extent of resection were not significantly associated with postoperative visual improvement in this cohort. Postoperative complications included diabetes insipidus, corticotropic insufficiency, cerebrospinal fluid leak, meningitis, and medical deaths unrelated directly to surgery.

Discussion: Our findings emphasize the prognostic importance of tumor invasiveness and extent of resection in recurrence of non-functioning pituitary adenomas. Cavernous sinus invasion may limit complete surgical removal and contribute to postoperative residual tumor progression. Although the endoscopic approach is increasingly used, surgical technique alone did not appear to influence recurrence or visual recovery in our series. These results support the need for individualized postoperative surveillance based on radiological invasiveness and quality of resection.

Conclusion: Knosp grade greater than 2 and incomplete tumor resection appear to be key prognostic factors for recurrence after surgery for non-functioning pituitary adenomas. Long-term multidisciplinary follow-up, including clinical, ophthalmological, hormonal, and radiological assessment, is mandatory, particularly in patients with invasive or subtotally resected tumors. Adjuvant radiotherapy or reoperation should be discussed in selected cases with progressive residual or recurrent disease.

P203 - Prognostic value of transcranial doppler ultrasonography in brain-injured patients admitted to the intensive care unit

Balkis Essid, Fatma Kolsi, R. Ammar, K. Ayadi, F. Gahbiche, M. Tallah, S. Abdelmoulah, M. Borni, S. Chaari, B. Kammoun, MZ. Boudawara

Department of Neurosurgery, Hbib Bourguiba University Hospital, Sfax , Tunisia

Background: Intracranial hypertension is a major complication in brain-injured patients, associated with increased morbidity and mortality. Transcranial Doppler (TCD) is a non-invasive, bedside tool for assessing cerebral hemodynamics, but its prognostic value in intensive care unit (ICU) patients requires further evaluation.

Methods: A prospective observational study included 55 brain-injured patients admitted to the polyvalent ICU of Habib Bourguiba University Hospital, Sfax (October 2022 – May 2023). TCD measurements (systolic velocity, diastolic velocity, pulsatility index [PI]) were performed on admission D1, D3, and D5. Outcomes were neurological recovery (awakening) and mortality.

Results: Mean age was 36.9±18.2 years; 90.9% were male. Traumatic brain injury was the main admission diagnosis (87.3%). Overall mortality was 25.5% (14/55). On D3 and D5, non-awakening patients had significantly lower diastolic velocity and higher PI compared to awakened patients ($p<0.05$). A PI increase >14% between D1 and D3 predicted poor neurological outcome (sensitivity 100%, specificity 89%; AUC 0.917). Deceased patients had significantly lower diastolic velocity on admission (26.4 vs. 32.2 cm/s; $p=0.036$). A PI variability >16.6% between D1 and D5 was an independent predictor of mortality (OR=15.0; $p=0.035$).

Conclusions: Serial TCD monitoring in brain-injured ICU patients provides valuable prognostic information. Early increase in pulsatility index predicts poor neurological outcome and mortality. TCD should be integrated into multimodal cerebral monitoring in neurocritical care.

P204 - Pronostic factors in chronic subdural hematoma : results from a retrospective study of 300 cases

El Kartit Fatima, Khoulali Mohamed, Hamid Khay, El Farissi, Mohamed Dahamou.

Neurosurgery Departement of the Mohamed VI University Hospital Oujda, Morocco.

Background: The study of age-related diseases like chronic subdural hematoma (CSDH) is of high interest, considering, he general ageing of the population. our study aim to evaluate pronostic factors, as well as characteristics of CSDH patients, treatment and comorbidities/complications.

Methods: a retrospective study of 300 cases of chronic subdural hematoma admitted to the neurosurgery departement of OUJDA university hospital since 2014

Results: the main age of the patients was 64,76 with extremes ranging between 7 and 102 years old with a male sex predominance, 73% of the cases patients had a clinical history of head injury; anticoagulant or antiplatelet drugs intake in 22% of the cases, hypertension in 30% of patients and diabetes in 29%; the clinical presentaion varied among patients, some prensented with hemiparesis or hemiplegia; some were confused; others with epileptic seizures, cranial hypertension syndrome or an altered state of consciousness. paraclinical diagnosis was assessed mostly by a head CT scan, two of the patients had a brain MRI performed. the location was left in 63% f the cases, right in 25% of the cases and bilateral in 12%. all of our patients got operated on, the chronic subdural hematoma was evacuated using a two burr hole and leaving in place an external drainage for 48 hours. short term prognosis was favorable in 262 of the patients, reccurence in 19 cases; 7 patients developped meningitis and 5 empyema; 7 patients died with an average hospital stay of 4 days. prognostic factors for death were mainly age related with it being greater for patients older than 75 years old, the intake of anticoagulant and antipletelet drugs also was responsible for more complications be it ischemic or hemorrhagic.

Conclusion: the knowledge of prognostic factors which might impact on the clinical outcomes could help to better manage patients with CSDH, which represents a surgically “simple” but, indeed, not trivial disease.

P205 - Pulmonary adenocarcinoma metastasis mimicking a sacral chordoma : a case report

Syrine Saadoun, A.Trifa, I.Ferchichi, N.Yahyaoui, M.Darmoul

Neurosurgery Department, Fattouma Bourguiba University hospital, Monastir, Tunisia.

Background: Chordoma is the most common primary malignant tumor of the sacrum and typically appears as a destructive midline sacral mass. However, metastatic lesions may closely mimic its radiological features, posing a significant diagnostic challenge. Accurate differentiation is essential because management and prognosis differ substantially. We report a rare case of sacral metastasis from lung adenocarcinoma initially diagnosed radiologically as a sacral chordoma.

Methods: We describe the clinical presentation, radiological findings, surgical management, histopathological diagnosis, and subsequent oncological workup of a patient presenting with a destructive sacral lesion suggestive of chordoma.

Results: A 55-year-old man presented with chronic lumbosacral pain associated with bilateral S1 radiculopathy, without motor, sensory, or sphincter deficits. Magnetic resonance imaging revealed a large destructive midline sacral lesion extending into both sacral alae, with imaging characteristics highly suggestive of sacral chordoma. Owing to the patient's symptoms and radiological findings, gross total tumor resection was performed through a posterior approach without perioperative complications. Histopathological examination unexpectedly demonstrated metastatic adenocarcinoma. Immunohistochemical analysis supported a pulmonary origin, and subsequent systemic investigations confirmed primary lung adenocarcinoma. The patient was referred for multidisciplinary oncological management, including staging, radiotherapy, and systemic treatment.

Conclusion: Sacral metastases may closely resemble primary sacral chordomas on imaging, making preoperative diagnosis challenging. Histopathological examination remains the gold standard for definitive diagnosis. This case emphasizes the importance of including metastatic disease in the differential diagnosis of destructive sacral lesions, even when imaging strongly favors chordoma, and highlights the value of a multidisciplinary approach to optimize patient management and outcomes.

P206 - Quality of life in children with cerebral palsy after repetetive botulinum toxin injections

Atika Mallek, Elleuch.W[1 4], Gahbich.F[3], Kolsi.F[3], Azaza. M[5], Elleuch Mh[2 4]

[1] Physical medicine department, Military university hospital of sfax , Tunisia

[2] Department of Physical Medicine, Habib Bourguiba Hospital of Sfax, Tunisia

[3] Department of Neurosurgery, Habib Bourguiba Hospital of Sfax, Tunisia

[4] Research Unit for the Evaluation of Musculoskeletal Disorders (04/UR/08-07), University of Sfax, 3000, Tunisia

[5] General surgery Department , Military university hospital of sfax , Tunisia

Introduction: Our objective is to assess the quality of life in children with cerebral palsy (CP) while highlighting the contribution of repetitive botulinum toxin (BT) injections.

Patients and methods: This is a prospective study including 60 children aged 2 to 18 years who received repeated botulinum toxin (BT) injections. All patients were assessed before, at 1 month, and at 6 months after BT injection in terms of functional status using the Gross Motor Function Classification System (GMFCS) and the Manual Ability Classification System (MACS). Quality of life was evaluated using the Child Health Questionnaire Parent Form 50 (CHQ-PF50) before injections and after one year.

Results: All families were two-parent households. The CHQ-PF50 was completed for 40 of the included children. The time required to complete the questionnaire was approximately 150 minutes per patient. The mean scores for most quality-of-life domains were above 50. No correlation was found between socio-demographic data and quality-of-life scores, whether physical or psychosocial, although in our practice we observed a predominance of families with low socioeconomic status. The psychosocial score was higher in children over 12 years of age. After the injections, we noted a mean visual analogical satisfaction scale (VAS) satisfaction score > 5, which increased with successive injections until reaching a plateau. We observed an improvement in CHQ-PF50 scores correlated with functional improvement: the physical score was correlated with GMFCS ($r = -0.747$, $p < 0.001$) and MACS ($r = -0.529$, $p < 0.001$); the psychosocial score was correlated with MACS ($r = -0.432$, $p = 0.005$).

Discussion: The benefits of multisite botulinum toxin injections in children with cerebral palsy (CP) are well established, particularly in terms of functional outcomes. However, they are less well documented regarding quality of life and satisfaction with this type of treatment. Contrary to the literature, our children with CP maintain a relatively good quality of life. Cultural factors may explain these differences. This quality of life improves after botulinum toxin injections, in parallel with functional improvement.

P207 - Rare case of diffuse spinal arachnoiditis following a complicated vertebral artery dissection

Kerroum Imene, F Benamara

EHS des urgences médico chirurgicale Akid Lotfi BOUHNIFIA MASCARA, Algeria

Background: Spinal arachnoiditis (SA) is an extremely rare and delayed complication of intracranial subarachnoid hemorrhage (SAH). SA is an inflammatory process leading to chronic fibrosis of the spinal cord. Possible pathophysiology is a two-staged disease of initial inflammatory reaction secondary to SAH, followed by a “free interval phase” prior to delayed adhesive phase(i.e. SA). The clinical course can be complicated and is the cause of major morbidity. 25 case reports since first described by Nelson in 1943. Majority of cases occur in females (86%) between ages of 22 and 69 years old.8

Methods: 47-year-old female complains of having the “worst headache” of her life and a grade 3 SAH. Past medical history: benign paroxysmal positional vertigo (BPPV) Diffuse Subtraction Angiography (DSA): Ruptured dissection/dissecting fusiform aneurysm of V4 segment of left VA Intact 1.7 x 1 mm aneurysm at proximal A1 segment of left ACA CT scan: diffuse SAH in the basal cisterns and posterior fossa extending through the foramen magnum.

Results: Patient developed SA with extensive, multiple localizations, involving segments from the posterior fossa, extending from cervical area to the sacrum. One other case had comparable diffuse arachnoiditis of thoracic and lumbar spine. Involvement of cervicomedullary junction, the highest-involved region currently reported in literature. Previously reported highest-involved region was C2. Unique symptoms of ataxia, nausea, and vomiting. First reported SA from a ruptured VA aneurysm.

Conclusion: Clinical course of SA after SAH can be complicated and is the cause of major morbidity. Patients showing signs and symptoms of SA following SAH, especially those involving the posterior circulation, should be followed closely as time of onset ranges from days to years after SAH.

P208 - Recurrent cervical myelopathy due to adjacent segment disease after cervical fusion: a surgical management case

Aziz Abdelmoula, A. Ouesleti, E. Mzoughi, F. Sliti, N. Nessib

Neurosurgery Department of National Institute of Neurology, Tunis, Tunisia

Adjacent segment disease (ASD) is a known complication following anterior cervical discectomy and fusion (ACDF), potentially leading to progressive myelopathy requiring revision surgery.

Methods: We report the case of a 34-year-old woman initially treated for C6–C7 disc herniation, who later developed recurrent neurological symptoms. Clinical course, imaging findings, and surgical management were reviewed.

Results: The patient initially presented with cervico-brachial neuralgia and pyramidal signs. MRI revealed a large C6–C7 disc herniation, treated with anterior discectomy and fusion, with initial clinical improvement. One year later, she developed progressive cervical myelopathy with claudication, upper limb weakness, and urinary urgency. Imaging revealed a compressive disco-osteophytic bar at C5–C6 with spinal cord compression. A revision surgery was performed, consisting of C6–C7 corporectomy with decompression extending to adjacent levels and stabilization using an expandable cage. Postoperatively, the patient showed stabilization of neurological symptoms with no further deterioration.

Conclusions: Adjacent segment disease is a significant long-term complication after cervical fusion. Early recognition of progressive myelopathy is essential. Revision surgery with extended decompression and stabilization can effectively halt neurological decline.

P209 - Recurrent intracranial hypertension in a young adult with arachnoid cyst managed with cystoperitoneal shunt: a case report of carotid cistern fenestration

Rim Baklouti, K.Maarmi, A. Ben Kedher, M. Darmoul.

Neurosurgery Department, Fattouma Bourguiba University hospital, Monastir, Tunisia.

Background: Arachnoid cysts are benign congenital cerebrospinal fluid (CSF) collections that may require surgical management when symptomatic. Cystoperitoneal (CP) shunting is a common treatment, but shunt-related complications, including malfunction and recurrent intracranial hypertension, are well-documented and often necessitate revision surgery. We report the case of a young adult with a history of arachnoid cyst treated by CP shunt, who experienced multiple episodes of shunt revision for recurrent intracranial hypertension, ultimately managed by carotid cistern fenestration.

Methods: A 23-year-old male with a known history of arachnoid cyst, initially treated with cystoperitoneal shunt placement, presented with recurrent episodes of intracranial hypertension. On each prior occasion, he underwent shunt revision. At the current presentation, he again exhibited signs of intracranial hypertension, including blurred vision, and fundoscopic examination revealed papilledema. Given the recurrent nature of shunt failure, surgical management with microsurgical opening (fenestration) of the carotid cistern was performed instead of further shunt revision.

Results: The patient underwent successful fenestration of the carotid cistern, establishing a communication between the arachnoid cyst and the basal cisterns to allow alternative CSF drainage pathways. Postoperatively, clinical signs of intracranial hypertension improved, with resolution or improvement of visual symptoms and papilledema on follow-up fundoscopic examination. No further episodes of shunt-related complications were noted at follow-up.

Conclusions: This case highlights the limitations of repeated cystoperitoneal shunt revision in patients with recurrent arachnoid cyst-related intracranial hypertension and underscores carotid cistern fenestration as a valuable alternative surgical strategy. Internal CSF diversion techniques, such as cisternostomy, may reduce dependence on shunt hardware and the associated risk of recurrent mechanical failure, offering a more durable solution in selected patients with refractory symptomatic arachnoid cysts.

P210 - Recurrent spinal hydatidosis: when does further surgery become futile?

Majdouline Barkache, R. Ben Fredj, A. Hmida, A. Mribah, I. Ksira

Department of Neurosurgery, Sahloul University Hospital, Sousse, Tunisia

Background: Spinal hydatidosis is a rare parasitic disease with high rates of recurrence and significant surgical morbidity. Despite repeated surgical interventions, complete eradication is often difficult due to infiltrative bone involvement and the risk of dissemination. Determining the limits of surgical management in recurrent cases remains a clinical challenge. This study aims to evaluate outcomes of repeated surgery in recurrent spinal hydatidosis and to discuss factors associated with surgical futility.

Methods: A retrospective case series was conducted including 15 patients treated for recurrent spinal hydatidosis between 2018 and 2024. Clinical records, imaging findings, surgical reports, and follow-up data were reviewed. Variables analyzed included number of previous surgeries, extent of vertebral involvement, neurological status, presence of extraspinal disease, and postoperative recurrence. Surgical futility was defined as persistent or rapidly recurrent disease despite multiple interventions associated with progressive neurological decline or poor quality of life.

Results: All patients had undergone at least one prior surgical procedure, with several requiring multiple revisions. Recurrent disease was most commonly associated with extensive vertebral destruction and paravertebral extension. Despite repeated decompressions and cyst evacuations, recurrence remained frequent, particularly in cases with multilevel involvement or associated extraspinal hydatidosis. Neurological deterioration was observed in a subset of patients despite surgery, and disease control became increasingly difficult with successive interventions. Patients with diffuse disease burden and repeated early recurrence showed limited long-term benefit from further surgery.

Conclusion: Recurrent spinal hydatidosis carries a high risk of surgical failure and progressive disease despite repeated interventions. The benefit of further surgery appears limited in cases with extensive, multilevel, or rapidly recurrent disease. A multidisciplinary approach combining surgery, prolonged antiparasitic therapy, and careful patient selection is essential. Earlier recognition of surgical futility may help avoid repeated high-morbidity procedures with limited clinical benefit.

P211 - Redo endoscopic endonasal surgery for recurrent pituitary adenomas: surgical challenges and lessons learned

Houssem Hdhili, K. Radhouane, A. Rachdi, T. Kamoun, S. Achoura, A. Harbaoui, R. Chkili, M.D.Yedeas

Department of Neurosurgery, Military Hospital of Tunis, Tunisia

Introduction: Recurrent pituitary adenomas represent a demanding challenge because postoperative fibrosis and distorted anatomical landmarks increase the complexity and potential morbidity of reoperation. Endoscopic endonasal techniques have improved the safety and efficacy of repeat surgery.

Methods: We retrospectively reviewed five consecutive patients who underwent redo endoscopic endonasal transsphenoidal surgery for recurrent pituitary adenomas at the Military Hospital of Tunis between January 2023 and January 2026. Clinical, radiological, operative, and outcome data were analyzed.

Results: The series included three men and two women (mean age 47 years). Four patients had non-functioning macroadenomas and one harbored a giant macroprolactinoma. Suprasellar extension was present in three cases and cavernous sinus invasion in two. Reoperations were complicated by fibrosis, loss of sellar landmarks, and adhesions to surrounding structures. Angled endoscopy and neuronavigation facilitated identification of residual tumor and safe dissection. Gross total resection was achieved in three patients and near-total resection in one. In a patient with a Knosp grade IV macroprolactinoma and extensive cavernous sinus invasion, subtotal resection was intentionally performed because of adherence to the intracavernous carotid artery and cranial nerves, followed by adjuvant medical therapy. One postoperative cerebrospinal fluid leak was successfully treated with multilayer reconstruction. Transient diabetes insipidus and temporary anterior pituitary dysfunction occurred in one patient each and resolved during follow-up. No vascular injury, visual deterioration, permanent endocrine deficit, or mortality was observed. After a mean follow-up of 18 months, all patients achieved satisfactory tumor control without requiring further surgery.

Conclusion: Redo endoscopic endonasal surgery is a safe and effective option for recurrent pituitary adenomas. Careful preoperative planning, preservation of neurovascular structures, and selective use of subtotal resection combined with adjuvant therapy are key factors for durable tumor control with low morbidity.

P212 - Respiratory distress due to persistent syringomyelia after chiari type 1 decompression

Roua Latrach, E. Elouni, N. Nessib, F. Sliti, A. Slimane, K. Ghedira, K. Abderrahmen, S. Bouali, I. Ben Said, J. Kallel

Department of Neurosurgery, National Institute of Neurology, Tunis, Tunisia

Syringomyelia is defined as the development of a fluid-filled cyst within the spinal cord. Several etiologies are possible, but Chiari malformation is the most common. Generally, the syrinx (the cyst) regresses or stabilizes after cranio-cervical decompression. In very rare cases, the cyst persists and may enlarge, causing variable symptoms ranging from simple pain to muscle dysfunction. We present the case of a 64-year-old female patient with a past medical history of ischemic stroke without sequelae, who was treated in our institute in 2023 for Chiari malformation type I associated with cervical syringomyelia by cranio-cervical decompression with C1 laminectomy. The patient initially experienced symptomatic improvement. Two years later, she presented with recurrence of motor deficit and gait disturbance. MRI demonstrated enlargement of the pre-existing syringomyelia with stable basilar impression and C1-C2 luxation, and she was admitted for surgery. During hospitalization, she developed acute respiratory distress requiring intubation. Further investigations were inconclusive, and syringomyelia progression was considered the most likely explanation. A syringo-subarachnoid shunt was performed, resulting in a favorable outcome. Syringomyelia generally regresses after Chiari decompression with improvement of symptoms. However, although rare, in some cases it can persist and cause severe complications such as acute respiratory distress. Continuous surveillance is therefore required, even in asymptomatic patients.

P213 - Respiratory infections and thromboembolic events: the hidden burden of cervical spine trauma surgery

Mohamed Amine Hmida, K.Maamri, M.Ghorbel, M.Hadhri, M.Darmoul

Neurosurgery Department, Fattouma Bourguiba University hospital, Monastir, Tunisia.

Introduction: Surgical management of subaxial cervical spine trauma (C3–C7) remains challenging, particularly in patients presenting with severe neurological deficits or associated injuries. Despite advances in spinal stabilization and decompression techniques, postoperative morbidity continues to significantly impact hospitalization duration, functional recovery, and overall outcomes.

Objective: To analyze the incidence, spectrum, and risk factors of postoperative complications following surgical treatment of subaxial cervical spine injuries.

Materials and methods: We conducted a retrospective study of 26 consecutive patients who underwent surgical treatment for subaxial cervical fractures or fracture-dislocations. Inclusion criteria comprised patients treated through anterior, posterior, or combined surgical approaches. Postoperative complications were categorized as systemic (infectious and thromboembolic) or local (surgical site-related). Statistical analysis was performed to investigate potential associations between complication occurrence and patient age, initial neurological status, and the presence of polytrauma.

Results: The overall postoperative complication rate was 26.5%. Respiratory infections were the most common complication, occurring predominantly in patients with severe cervical spinal cord injury and impaired ventilatory function. Surgical site infections were mainly observed following posterior approaches. Thromboembolic events, including deep vein thrombosis, were identified despite standard prophylactic measures. A significantly higher incidence of complications was observed among elderly patients, polytraumatized individuals, and patients presenting with complete tetraplegia (ASIA grade A).

Conclusion: Postoperative complications remain frequent after surgical treatment of subaxial cervical spine trauma and significantly influence patient outcomes. Successful management extends beyond the technical aspects of surgery and requires comprehensive perioperative care. Particular attention should be directed toward early and aggressive respiratory management, rigorous thromboprophylaxis protocols, and close monitoring of elderly and polytraumatized patients to anticipate and prevent systemic complications.

P214 - Reversible cerebral vasoconstriction syndrome mimicking a brain abscess: a case report and literature review

Mohamed Znazen, M. Taallah, I. Ketata, H. Belmabrouk, A. Hachicha

Department of Neurosurgery, University Hospital of Gabès, Tunisia

Background: Reversible cerebral vasoconstriction syndrome (RCVS) is an uncommon cerebrovascular disorder characterized by multifocal segmental narrowing of cerebral arteries that resolves spontaneously within weeks to months. It predominantly affects women and typically presents with recurrent thunderclap headaches. Neurovascular complications include intracerebral hemorrhage, cortical subarachnoid hemorrhage, and ischemic stroke. Atypical presentations may pose significant diagnostic challenges and mimic other intracranial pathologies.

Methods: We report the case of a 40-year-old man with no significant medical history who presented with isolated headaches evolving over four months. Clinical, biological, and neuroradiological findings were retrospectively analyzed, and a review of the literature was performed.

Results: Neurological examination was unremarkable, and laboratory investigations showed no abnormalities. Brain computed tomography revealed two left parietal cortical lesions with peripheral contrast enhancement, initially suggesting cerebral abscesses. Subsequent magnetic resonance imaging demonstrated two left parieto-occipital lesions characterized by T2 and T2* hypointensity, increased apparent diffusion coefficient (ADC) values, and peripheral enhancement, consistent with resolving intracerebral hematomas. Magnetic resonance angiography disclosed multifocal segmental cerebral arterial vasoconstriction. Based on the clinical and radiological findings, a diagnosis of reversible cerebral vasoconstriction syndrome was established. Follow-up brain MRI performed two months later demonstrated marked regression of the lesions, further supporting the diagnosis.

Conclusions: RCVS may present with atypical radiological features mimicking infectious intracranial lesions such as brain abscesses. This case highlights the importance of MRI and vascular imaging in the differential diagnosis of ring-enhancing cerebral lesions. Early recognition of RCVS is essential to avoid unnecessary invasive procedures and inappropriate treatments.

P215 - Revision surgery following anterior cervical discectomy and fusion: a four-patient case series of mechanical failure and adjacent segment disease

Emna Elouni, Abdelhafidh Slimane, Nessrine Nessib, Firas Sliti, Myriam Naceur, Imed Ben Said, Jalel Kallel

Neurosurgery Departement, National Institute of Neurology, Tunis, Tunisia

Background: Anterior cervical discectomy and fusion (ACDF) is the gold standard for the surgical management of cervical degenerative disc disease, with excellent clinical outcomes and high fusion rates. Nevertheless, late complications requiring revision surgery, including implant failure and adjacent segment disease (ASD), may occur. We report our experience with four patients who underwent revision surgery following ACDF.

Methods: We retrospectively reviewed four patients who required reoperation after ACDF. Clinical presentation, imaging findings, indications for revision, surgical management, and postoperative outcomes were analyzed.

Results: Four patients underwent revision surgery for delayed complications after ACDF. Three patients presented with anterior cervical plate fracture associated with recurrent neck pain and neurological deterioration. Imaging demonstrated construct failure, with pseudoarthrosis in two cases. All three patients underwent hardware removal, revision decompression when indicated, and repeat fusion using new anterior instrumentation. The fourth patient developed symptomatic cranial ASD several years after the index procedure, presenting with progressive cervical myelopathy caused by adjacent-level stenosis. Decompression and extension of the fusion to the affected level were performed. At a mean follow-up of 12 months, all patients experienced neurological improvement or stabilization, significant pain relief, and satisfactory radiological stability, with no revision-related complications or recurrent hardware failure.

Conclusion: Revision surgery after ACDF is uncommon but may be required for late mechanical failure or adjacent segment degeneration. Prompt recognition of these complications and individualized surgical management can achieve favorable clinical and radiological outcomes. Long-term follow-up remains essential to detect delayed complications and optimize patient outcomes.

P216 - Revisiting the controversies in the managment of brainstem gliomas: CSF diversion and tissue diagnosis

Houssem Hdhili, M.D.Yedeas, T.Kamoun, A.Affes, S.Achoura, A.Harbaoui, R.Chkili, K.Radhouane

Department of Neurosurgery, Military Hospital of Tunis, Tunisia

Background: Brainstem gliomas constitutes a heterogeneous group of tumors whose management remains challenging. Historically, treatment decisions have relied heavily on radiological findings, and tissue diagnosis was often deferred because of concerns regarding surgical morbidity. However, advances in molecular pathology and biopsic techniques have renewed interest in biopsy as a tool for individualized treatment.

Methods: We report the case of a 12-year-old girl who presented with obstructive hydrocephalus secondary to a brainstem lesion. A ventriculoperitoneal shunt was initially performed. Based on magnetic resonance imaging findings suggestive of a low-grade brainstem glioma and the patient's clinical stability, conservative management with serial radiological follow-up was adopted without tissue diagnosis.

Results: After six years of surveillance, radiological progression prompted reassessment of the diagnosis and treatment strategy. An open biopsy was subsequently performed and demonstrated a pilocytic astrocytoma. Histopathological confirmation led to a change in management from observation to active surgical treatment. The patient is currently undergoing preoperative planning for tumor resection.

Discussion: This case highlights two major dilemmas in the management of brainstem gliomas: cerebrospinal fluid diversion and the timing of tissue diagnosis. While radiological surveillance may be appropriate in selected cases, delayed progression can uncover tumors with favorable histology and distinct therapeutic implications. Modern stereotactic biopsy techniques provide high diagnostic accuracy with acceptable morbidity and may prevent prolonged diagnostic uncertainty.

Conclusion: Brainstem gliomas should not be considered a homogeneous entity. In the era of precision medicine, tissue diagnosis can profoundly influence therapeutic decisions. This case underscores the importance of reconsidering biopsy in progressive lesions and illustrates how histological confirmation may open new surgical perspectives and improve patient management.

P217 - Rewiring the pelvis: sacral neuromodulation for sexual dysfunction beyond bladder control

Firas Akrout, Affes A, Rachdi M.A., Hdhili H, Bouzouita K, Achoura S, Chkili Ridha, Radhouen K.

Neurosurgery Department, Military Hospital of Tunis, Tunis, Tunisia

Background & objectives: Sacral neuromodulation (SNM), widely established for refractory overactive bladder, urinary retention, and fecal incontinence, operates through modulation of sacral nerve roots governing the entire pelvic floor neurocircuitry — including the neural pathways mediating sexual arousal, orgasm, and genital sensation. Incidental improvements in sexual function following SNM implantation have been increasingly reported, yet this dimension remains systematically underinvestigated and absent from current indications. This systematic review appraises evidence on SNM effects on sexual function beyond its established urological indications.

Methods: Systematic review conducted according to PRISMA guidelines across PubMed, Scopus, Embase, and Cochrane databases (2000–2024). Studies reporting sexual function outcomes following SNM implantation, measured by validated instruments (FSFI, IIEF, GRISS), were included. Case series, prospective cohorts, and randomized controlled trials were critically appraised.

Results & discussion: Female sexual function: Multiple cohort studies report significant improvements in sexual desire, arousal, lubrication, and orgasm following SNM, with FSFI total scores improving by 30–50% in responders. Proposed mechanisms include direct modulation of pudendal afferent pathways and normalization of pelvic floor hypertonicity contributing to dyspareunia and anorgasmia. Male sexual function: Limited but consistent evidence suggests SNM improves erectile function and ejaculatory disorders in men with concomitant voiding dysfunction, mediated through shared sacral autonomic circuitry governing both urological and sexual responses. Neurological populations: Patients with multiple sclerosis, incomplete spinal cord injury, and cauda equina syndrome demonstrate sexual function improvements alongside urological benefits, suggesting SNM's neuromodulatory effects extend beyond peripheral reflex arc modulation to supraspinal pathway reorganization. Limitations: Significant heterogeneity in outcome measures, absence of sexual function as a primary endpoint in existing trials, small sample sizes, and limited long-term follow-up data constrain definitive conclusions.

Conclusion: Sacral neuromodulation exerts clinically meaningful effects on sexual function extending well beyond bladder control. Dedicated prospective trials incorporating validated sexual outcome measures as primary endpoints are urgently needed to establish SNM as a legitimate therapeutic option for refractory sexual dysfunction.

P218 - Rhabdoid brain tumor: an uncommon and highly aggressive neoplasm

Ines Ferchichi, Amine Trifa, Rim Baklouti, Aziz Ben Khedher, Mehdi Darmoul

Neurosurgery Department, Fattouma Bourguiba University hospital, Monastir, Tunisia.

Background: Rhabdoid brain tumors are rare, highly aggressive neoplasms of uncertain histogenesis, predominantly affecting children under the age of three and accounting for approximately 3% of pediatric brain tumors. These tumors are strongly associated with deletions in chromosome 22q11 and inactivation of the tumor suppressor gene INI1/hSNF5. They are characterized by rapid progression, frequent recurrence, and a poor prognosis, with reported median survival of approximately one year. The World Health Organization classifies central nervous system (CNS) rhabdoid tumors within embryonal tumors, most commonly represented by atypical teratoid/rhabdoid tumors (ATRT).

Methods: We report a single case managed in the Neurosurgery Department of Fattouma Bourguiba University Hospital. Clinical presentation, neuroimaging findings, surgical management, histopathological results, adjuvant treatment, and clinical evolution were analyzed.

Case presentation and results: A 3-year-old female with no significant past medical history presented with vomiting and partial secondary generalized tonic-clonic seizures. Brain computed tomography and magnetic resonance imaging revealed a well-defined right temporal mass associated with significant perilesional edema, compression of the right lateral ventricle and midbrain, and downward transtentorial herniation of the temporal lobe. Radiological features initially suggested an infantile astrocytoma. The patient underwent surgical intervention with total macroscopic tumor resection. Histopathological examination confirmed a diagnosis of rhabdoid tumor of the central nervous system. Postoperative adjuvant radiotherapy and chemotherapy were administered. Despite initial management, the patient developed recurrent partial tonic-clonic seizures one month later. Follow-up MRI demonstrated rapid tumor recurrence, with regrowth to its initial preoperative size. The clinical course was rapidly progressive, and the patient died five months after diagnosis. No autopsy was performed.

Conclusion: Rhabdoid brain tumors are rare embryonal CNS neoplasms with highly aggressive behavior and extremely poor prognosis. They often present with nonspecific clinical and radiological features, leading to diagnostic challenges. Despite multimodal treatment including surgery, chemotherapy, and radiotherapy, outcomes remain dismal due to rapid recurrence and resistance to therapy. Early recognition and prompt histopathological diagnosis, including molecular confirmation of INI1 loss, are essential. A systemic evaluation to exclude a primary renal rhabdoid tumor is mandatory in all cases

P219 - Risk factors for recurrence and management of chronic subdural hematoma in the neurosurgery department of monastir

Rim Baklouti, MA.Hadj Taieb, K. Maamrin A. Ben Kedher, M.Darmoul

Neurosurgery Department of Fatouma Bourguiba University Hospital

Background: Over the past decades, the incidence of chronic subdural hematoma (CSDH) has steadily increased, largely driven by the aging of the population and the widespread use of antithrombotic therapies. Treatment is primarily surgical, and postoperative outcomes are generally favorable. However, the recurrence rate following surgical evacuation remains significant and may lead to considerable neurological morbidity. Precise identification of the risk factors associated with recurrence is therefore critical to optimize management strategies and improve patient prognosis.

Methods: We conducted a retrospective, descriptive, and analytical study including all patients who underwent surgical evacuation for symptomatic CSDH at the Neurosurgery Department of Fattouma Bourguiba University Hospital, Monastir, Tunisia, over a five-year period from January 1, 2020 to December 31, 2024. Univariate analysis was performed using the Chi-square test and Fisher's exact test for qualitative variables. Multivariate logistic regression was subsequently applied to identify independent predictors of recurrence. Statistical significance was set at $p < 0.05$.

Results: A total of 141 patients were included, with a mean annual incidence of 28 cases. Thirtythree patients (23.4%) experienced recurrence, with a mean of 6 recurrences per year. The mean age of the overall population was 69 years, with a male predominance (sex ratio: 3.27). On univariate analysis, several factors were significantly associated with recurrence, including age ≥ 75 years, female sex, heavy smoking, bilateral hematoma, midline shift > 10 mm, local anesthesia, use of a single burr hole or craniotomy with bone flap, drainage duration of 24 hours, and unipolar drainage. On multivariate analysis, only midline shift > 10 mm and postoperative drainage duration remained independently associated with recurrence. These findings directly influenced our postoperative management protocol in order to reduce the risk of recurrence.

Conclusion: Identifying predictive factors of CSDH recurrence enables better stratification of high-risk patients and supports the implementation of more tailored surgical and postoperative management strategies, ultimately contributing to improved functional outcomes.

P220 - Risk factors for symptomatic postoperative epidural fibrosis following interlaminar lumbar discectomy: a retrospective analysis of 422 cases

Kais Bouzouita, S.Fahat, H.Kammoun, A.Rachdi, S.Achoura, A.Harbaoui, R.Chkili, M.D.Yedeas, K.Radhouane.

Neurosurgery Department, Military Hospital of Tunis, Tunis, Tunisia

Background: Postoperative epidural fibrosis (PEF) is a leading cause of failed back surgery syndrome and persistent radiculopathy after lumbar disc surgery. Radiologically detectable in 10–75% of cases, it remains clinically symptomatic in only 5–20%. Independent risk factors for symptomatic PEF are incompletely characterised and no consensus preventive strategy exists.

Methods: Single-centre retrospective cohort study (Military Hospital of Tunis, January 2020 – December 2022). Inclusion criteria: adults undergoing single-level unilateral interlaminar discectomy for MRI-confirmed lumbar disc herniation with ≥24 months follow-up. Exclusion criteria: multi-level procedures, concomitant lumbar pathology, prior surgery, or preoperative epidural injections. PEF was defined as gadolinium-enhanced MRI-confirmed recurrent radiculopathy ≥6 weeks post-surgery without recurrent herniation. Fibrosis extent was graded using the ROSS classification. Statistical analysis used Pearson chi-square test ($p < 0.05$; IBM SPSS v26).

Results: Of 422 patients, 48 (11.4%) developed symptomatic PEF. Mean age was 40.5 years; male predominance (68.8%). Symptoms appeared within 6 months in 77.1% of cases. Four independent risk factors were identified: diabetes mellitus (50.0% vs. 14.9%; $p = 0.002$), active smoking (64.6% vs. 36.9%; $p = 0.04$), intraoperative blood loss (mean 139.3 vs. 87.6 mL; $p = 0.001$), and operative time (mean 104.3 vs. 80.3 min; $p = 0.01$). ROSS Grade 3–4 fibrosis correlated with poor prognosis (78.1% vs. 37.5%; $p = 0.006$).

Conclusions: Symptomatic PEF affects ~11% of patients after interlaminar discectomy. Four modifiable risk factors were identified, supporting targeted prevention: glycaemic optimisation, preoperative smoking cessation, meticulous haemostasis, and efficient surgical technique. ROSS MRI grading should guide therapeutic decisions. Prospective multicentre studies are warranted.

P221 - Schneider syndrome at the crossroads: building a joint emergency-neurosurgery protocol for optimal diagnosis and timely decompression

Tayssir Saafi, Khayat M, Affes A, Rachdi MA, Akrout F, Yedeas MD, Chkili R, Radhouen K

Neurosurgery Department, Military Hospital of Tunis, Tunis, Tunisia

Background & objectives: Central cord syndrome (CCS), first described by Schneider in 1954, is the most common incomplete spinal cord injury (~50% of cases). Its paradoxical presentation — preserved ambulation with disproportionate upper limb weakness — makes it particularly prone to misdiagnosis in the polytrauma setting. No standardized joint protocol between emergency physicians and neurosurgeons currently guides its management. This presentation aims to define key diagnostic pitfalls, establish a collaborative emergency pathway, and determine optimal medical and surgical management.

Methods: Narrative review of prospective cohort studies, systematic reviews, and major society guidelines (AO Spine, CNS, AANS, EuroSpine, 2010–2024), integrated with clinical experience from our neurosurgical unit (CHU Sahloul, Sousse).

Results & discussion: Diagnostic pitfalls: Six critical gaps were identified at the emergency-neurosurgery interface: distracting injuries masking neurological evaluation, normal cervical X-rays falsely reassuring in pre-existing stenosis (SCIWORA-like), underestimation of preserved gait, confusion with cerebral lesions, delayed MRI in unstable patients, and urinary retention masked by routine catheterization. Systematic ASIA assessment at admission is mandatory regardless of other injuries. Acute management: High-dose methylprednisolone is no longer recommended in polytrauma (AO Spine/AANS/CNS, evidence level I). Rigid cervical immobilization, hemodynamic optimization (MAP ≥ 85 mmHg, SpO_2 ≥ 95%), and early neurosurgical consultation — triggered upon clinical suspicion — form the backbone of the joint protocol. MRI timing: Emergency MRI within 8 hours is the shared target for both diagnosis and surgical planning. Neurosurgical coordination of imaging must begin at the moment of clinical alert, not after emergency workup completion. Surgical timing & goals: Early decompression within 24 hours is associated with significantly greater neurological recovery (≥ 2 ASIA grades; OR 2.8, STASCIS 2012). The primary goal is cord decompression; stabilization is added when instability is confirmed. Approach selection is driven by MRI morphology and jointly assessed surgical fitness.

Conclusion: CCS sits at the crossroads of emergency medicine and neurosurgery. A formalized joint protocol — systematic ASIA scoring, early neurosurgical alert, MRI within 8 hours, no routine steroids, and decompression within 24 hours — is essential to close the diagnostic and therapeutic gaps that compromise functional recovery.

P222 - Schwannoma of the orbit: a case report.

Melouk Khadidja, Mimouni

Neurosurgery department of ORAN EHUO, Algeria.

Background: Orbital schwannomas are rare benign tumors arising from Schwann cells of the peripheral nervous system. Localization within the optic nerve sheath is exceptional because Schwann cells are physiologically absent at this site. Their clinicoradiological diagnosis remains challenging due to the nonspecific clinical presentation and variable radiological features.

Methods: We report the case of a patient presenting with progressive proptosis associated with decreased visual acuity. Orbital MRI revealed a well-circumscribed intraconal mass, initially suggesting several differential diagnoses. Surgical excision was performed through an approach tailored to the tumor location. Histopathological and immunohistochemical examination confirmed the diagnosis of orbital optic nerve sheath schwannoma.

Results: Orbital schwannomas account for approximately 1–4% of orbital tumors. MRI is the imaging modality of choice and may suggest the diagnosis based on the lesion characteristics. However, definitive diagnosis relies solely on histopathological examination. The choice of surgical approach mainly depends on tumor size and location. Early management improves visual functional outcome and helps avoid aggressive surgical procedures.

Conclusion: Optic nerve sheath schwannoma is an exceptional entity whose diagnosis remains challenging. Complete surgical excision generally provides an excellent prognosis with a low risk of recurrence. Better awareness of this rare pathology may promote earlier diagnosis and more conservative management.

P223 - Schwannomatosis: a rare case highlighting diagnostic challenges

Mohammed Al Amine El Farissi, Mohamed Dahamou, Hamid Khay, Khoulali Mohamed

Department of Neurosurgery, Mohammed VI University Hospital, Faculty of Medicine and Pharmacy of Oujda, Mohammed First University, Oujda, Morocco.

47-year-old woman, history of brachial plexus schwannoma, presented with chronic lumbar pain and electric discharges. MRI revealed an L3 intradural extradural mass. Complete surgical resection was performed. Histopathology confirmed schwannoma. No genetic mutation or family history. Diagnosis: sporadic schwannomatosis (Kehrer-Sawatzki criteria). Favorable postoperative outcome.

P224 - Sealing the skull base: predictors of nasoseptal flap success in endoscopic transsphenoidal approaches

Kais Bouzouita, Ameur A, Rachdi M.A., Kammoun T, Achoura S, Chkili Ridha, Radhouen K.

Neurosurgery Department, Military Hospital of Tunis, Tunis, Tunisia

Background & objectives: The nasoseptal flap (NSF), introduced by Hadad and Bassagasteguy in 2006, has become the workhorse reconstructive technique for skull base defect closure following endoscopic transsphenoidal surgery, dramatically reducing postoperative CSF leak rates from 15–20% to below 5% in high-flow defects. Despite its widespread adoption, reconstruction failure and postoperative CSF fistula remain clinically significant complications with potentially life-threatening consequences. Identifying reliable predictors of NSF success is essential to optimize surgical planning and intraoperative execution. This review critically examines anatomical, technical, and patient-related determinants of NSF reconstruction success.

Methods: Narrative review of PubMed, Scopus, and Cochrane databases (2006–2024), including prospective cohort studies, comparative series, and technical reports evaluating NSF outcomes, failure predictors, and reconstruction strategies in endoscopic transsphenoidal and expanded skull base approaches.

Results & discussion: Anatomical determinants: Adequate flap dimensions — governed by nasoseptal artery territory, septal length, and defect size — represent the primary anatomical success criterion. Preoperative MRI-based defect mapping and intraoperative fluorescein-assisted flap perfusion assessment improve dimensional planning accuracy and reduce undersizing errors. Technical determinants: Meticulous vascular pedicle preservation during posterior septal dissection, complete dural defect coverage with minimum 1 cm overlap, elimination of dead space through multilayer reconstruction, and secure flap fixation with hemostatic agents constitute the critical technical success factors consistently identified across series. Patient-related factors: Elevated body mass index, prior transsphenoidal surgery, previous radiotherapy, and intraoperative high-flow CSF leaks are independently associated with increased reconstruction failure rates, mandating augmented multilayer closure strategies in these high-risk profiles. Salvage strategies: Contralateral NSF, temporoparietal fascia flap, and free mucosal grafts represent validated alternatives when primary NSF harvest is compromised by prior surgery or inadequate dimensions.

Conclusion: NSF success in endoscopic transsphenoidal surgery depends on systematic anatomical planning, meticulous vascular preservation, complete defect coverage, and individualized risk stratification. Standardizing these criteria within institutional protocols offers the most reliable pathway to minimizing postoperative CSF fistula.

P225 - Seeing through the skull: augmented reality as the next frontier in neurosurgical visualization

Ameur Affes, Rachdi M.A., Hdhili H, Bouzouita K, Achoura S, Chkili Ridha, Radhouen K.

Neurosurgery Department, Military Hospital of Tunis, Tunis, Tunisia

Background & objectives: Augmented reality (AR) in neurosurgery superimposes three-dimensional anatomical reconstructions, vascular maps, tumor boundaries, and navigational trajectories directly onto the surgeon's visual field, creating an unprecedented fusion of preoperative planning data with intraoperative reality. Unlike conventional neuronavigation requiring gaze redirection to external screens, AR maintains surgical focus while delivering continuous spatial guidance. This review examines current evidence on AR applications in neurosurgery, evaluating technical maturity, clinical validation, and translational readiness.

Methods: Narrative review of PubMed, Scopus, and IEEE Xplore databases (2010–2024), including technical validation studies, cadaveric experiments, and clinical series evaluating AR systems in cranial tumor surgery, vascular neurosurgery, and spinal instrumentation.

Results & discussion: Cranial tumor surgery: AR overlays delineating tumor boundaries and eloquent structure proximity onto the operative field have demonstrated submillimetric projection accuracy in phantom and cadaveric validation, with early clinical series confirming reduced approach trajectory deviations and improved surgeon confidence during deep lesion targeting. Vascular neurosurgery: AR-assisted aneurysm clipping, projecting three-dimensional aneurysm morphology and parent vessel anatomy onto the microscopic field, reduces reliance on repeated fluorescein angiography and improves clip placement accuracy, particularly for complex or partially hidden aneurysm necks. Spinal surgery: AR-guided pedicle screw insertion via head-mounted displays achieves accuracy rates comparable to robotic navigation systems while preserving full surgical freedom of movement, without the workflow disruption of robotic arm positioning. Current limitations: Registration drift, computational latency, haptic feedback absence, and headset ergonomics during prolonged procedures remain significant barriers to routine clinical adoption. No prospective randomized trial has yet demonstrated AR superiority over conventional neuronavigation in patient outcome metrics.

Conclusion: Augmented reality represents a genuine paradigm shift in neurosurgical visualization, transitioning guidance from external screens to the surgeon's direct visual field. Technical validation is mature; clinical outcome evidence is emerging. Full integration into routine neurosurgical practice appears imminent.

P226 - Selective neurotomy as a sustainable alternative to intrathecal baclofen pumps for spasticity management in low-income countries: a review of literature

Haifa Mechergui, Salim Bachraoui[2], Slimane Abdelhafidh[2], Khalil Ghedira[2]

[1]Surgery Department, Habib Bougatfa Hospital Bizerte; [2] Neurosurgery Department , national institut of Tunis,

Selective neurotomy may represent a sustainable alternative to intrathecal baclofen pumps for the management of spasticity in low-income countries. Although intrathecal baclofen therapy is an effective and adjustable treatment for severe generalized spasticity, its use is often limited in low-income countries by the high cost of the implantable device, the need for regular refilling, specialized follow-up, technical maintenance, and the risk of complications such as infection, catheter dysfunction, overdose, or withdrawal. In contrast, selective neurotomy is a surgical procedure aimed at reducing muscle stiffness by partially sectioning selected motor nerve branches while preserving useful motor functions. It does not require an implanted programmable device or repeated hospital visits for pump refilling, making it potentially more accessible and cost-effective in resource-limited environments. However, selective neurotomy should not be considered a universal replacement for intrathecal baclofen therapy. Its indications are mainly restricted to patients with focal or multifocal spasticity, clearly defined functional goals, and access to postoperative rehabilitation. Intrathecal baclofen remains preferable in cases of severe generalized spasticity, diffuse dystonia, or fluctuating tone requiring reversible and adjustable treatment. Therefore, in carefully selected patients, selective neurotomy may offer a durable, affordable, and effective strategy for spasticity management in low-resource countries.

P227 - Sellar and suprasellar mixed germ cell tumor mimicking a pituitary adenoma: a rare pediatric case and therapeutic challenges

Ines Ferchichi, Mohamed Amine Hadj Taieb, Alaeddine Chaabene, Mehdi Darmoul

Neurosurgery Departement of Fattouma Bourguiba University Hospital, Monastir, Tunisia

Background: Intracranial germ cell tumors are rare, representing approximately 0.5% of all primary brain tumors. They most commonly arise in the pineal and suprasellar regions. Mixed germ cell tumors with a predominant immature teratoma component are particularly uncommon. When extending into the sellar region, they may closely mimic pituitary macroadenomas both clinically and radiologically, leading to frequent diagnostic difficulty. However, their biological behavior and therapeutic approach differ significantly from pituitary adenomas, making early recognition essential. We report a rare pediatric case presenting with acute hypopituitarism.

Methods: An 11-year-old girl was admitted with acute central adrenal insufficiency. Endocrinological evaluation revealed hypocortisolism, central hypothyroidism, and mild hyperprolactinemia, consistent with hypopituitarism. Brain MRI demonstrated a large sellar and suprasellar lesion initially suggestive of a pituitary macroadenoma. Due to diagnostic uncertainty, a right pterional craniotomy was performed for biopsy. Histopathological and immunohistochemical analysis confirmed a mixed germ cell tumor composed predominantly (90%) of immature teratoma.

Results: The histopathological diagnosis completely changed the therapeutic strategy. Instead of surgery for a presumed pituitary adenoma, the patient was referred for multidisciplinary oncological management involving neurosurgery, pediatric oncology, endocrinology, and radiation oncology. Hormone replacement therapy was initiated to manage endocrine deficits. The predominance of immature teratoma raised key therapeutic questions regarding the role of second-look surgery after adjuvant treatment and the optimal radiotherapy strategy, including the indication for craniospinal irradiation. This case highlights the limitations of imaging alone and underscores the essential role of tissue diagnosis in guiding management.

Conclusions: Sellar and suprasellar mixed germ cell tumors are extremely rare and should be included in the differential diagnosis of pediatric hypothalamic-pituitary lesions presenting with endocrine dysfunction. Histopathological confirmation is mandatory for definitive diagnosis and appropriate treatment planning. Given the lack of standardized guidelines, management should be individualized within a multidisciplinary team. Further reported cases are needed to better define optimal therapeutic strategies and improve understanding of these rare tumors

P228 - Sellar dermoid cyst presenting with progressive visual deterioration in a 13-year-old boy treated by endoscopic endonasal surgery: a case report

Chabat Átef, D. Dergham, N.Baz, M. Krimed, A. Mati, K. Bouaita

Department of neurosurgery, neurosurgery hospital Cherchall, Algeria

Background: Sellar dermoid cysts are rare congenital lesions that may present in childhood with progressive visual loss due to compression of the optic apparatus. Because of their uncommon sellar location and nonspecific symptoms, diagnosis is often delayed until neuroimaging is performed.

Methods: We report the case of a 13-year-old boy with progressive visual deterioration. MRI showed a sellar lesion suggestive of a dermoid cyst compressing the optic pathway. The patient underwent endoscopic endonasal surgery for lesion removal, and the diagnosis was confirmed histopathologically.

Results: Intraoperative findings were consistent with a dermoid cyst. The postoperative course was uneventful, and visual function stabilized after surgery.

Conclusions: Sellar dermoid cyst should be included in the differential diagnosis of pediatric sellar masses associated with visual impairment. Endoscopic endonasal surgery offers an effective minimally invasive approach for decompression and definitive diagnosis.

P229 - Single bypass fixation for the treatment of lumbar spondylolisthesis: anatomical insights and technical note

Moneer Faraj, Mohammed Bani Saad, Mustafa Ismail.

Department of Surgery, Iraqi Medical Association,

Department of Surgery, Baghdad Teaching Hospital, Al Risafa, Baghdad, Iraq.

Background: Lumbar spondylolisthesis usually requires surgical management for the stabilization of the spine and to relieve patients of their symptoms. This study aims to provide anatomical insights and to evaluate the efficacy of single-bypass fixation in the surgical treatment of lumbar spondylolisthesis. This technique aims to stabilize the spine with minimal manipulation of the slipped vertebra, thereby reducing potential complications and improving clinical outcomes.

Methods: This is a retrospective study conducted at a neurosurgical hospital in Baghdad, Iraq, including 35 cases of lumbar spondylolisthesis that underwent single-bypass fixation between December 2012 and December 2019. The procedure involves stabilizing the lumbar spine by fixing the vertebrae above and below the affected segment using pedicle screws and rods, guided by fluoroscopy to ensure accurate placement and avoid neurovascular injury. A laminectomy was performed as needed to decompress the spinal cord and nerve roots. Autograft or allograft bone was used to promote fusion around the stabilized segment. Pre- and postoperative clinical and radiological assessments were conducted. Pre- and postoperative clinical and radiological assessments were done.

Results: There have been substantial gains in pain relief, neurological status, and spinal stability, with high fusion rates and low complication rates.

Conclusion: Single-level bypass fixation is effective for lumbar stabilization in patients with spondylolisthesis, with the best clinical results and fewer complications.

P230 - Slit ventricle without dilatation: shunt dysfunction

Selma Farfar, Sofiane Imekraz, Amina Nouaouria, Aniss Layachi, Mourad Bouaziz

EPH EL hadjar, CHU ANNABA ALGERIA

Background: The slit ventricle syndrome (SVS) is a rare but challenging complication of cerebrospinal fluid (CSF) shunt systems, typically observed in long-term follow-up. It is characterized by narrow or collapsed ventricles on imaging, despite clinical signs of intracranial hypertension (ICH). This paradoxical presentation often delays diagnosis and management.

Objective: To illustrate the diagnostic difficulties and therapeutic considerations in cases of SVS with shunt dysfunction, despite the absence of ventricular dilatation on imaging.

Methods: We report a clinical case presenting with symptoms of ICH, including severe headache, nausea, and visual disturbances, in a patient with shunted hydrocephalus. Imaging revealed slit-like ventricles without radiological evidence of shunt failure. Diagnosis was established based on clinical findings, supported by functional shunt evaluation and direct intracranial pressure (ICP) monitoring.

Results: Despite the absence of ventriculomegaly, the patient showed clear clinical deterioration. Functional investigations revealed partial or intermittent shunt dysfunction. Surgical revision of the shunt system led to symptomatic improvement, confirming the diagnosis of SVS.

Conclusion: SVS without ventricular dilatation presents a significant diagnostic challenge. Clinical evaluation remains paramount, especially when radiological findings are inconclusive. Early recognition and appropriate management are essential to prevent irreversible neurological damage. Clinicians should maintain a high index of suspicion in symptomatic patients with a history of shunting, even in the presence of normal or slit-like ventricles on imaging.

P231 - SMA syndrome with reversible postoperative deficit after resection of a left parasagittal parietal meningioma: implication of the superior longitudinal fasciculus I

Ameur Affes, Farhat S, Hdhili H, Bouzouita K, Kammoun H, Yedeas MD, Achoura S, Chkili R, Radhouane K

Neurosurgery Department, Military Hospital of Tunis, Tunis, Tunisia

Background: Resection of parasagittal meningiomas adjacent to the supplementary motor area (SMA) may result in a transient SMA syndrome characterized by contralateral motor deficits with preserved muscle tone, typically followed by near-complete recovery. While this syndrome is well described after resection within the SMA itself, its occurrence after extra-axial parietal lesions adjacent to SMA-connected pathways, particularly the superior longitudinal fasciculus I (SLF I), is less emphasized in the literature.

Case description: We report the case of a 74-year-old female patient who underwent resection of a left parasagittal parietal meningioma. In the immediate postoperative period, the patient developed contralateral lower limb weakness with preserved muscle tone, without pyramidal signs, consistent with a partial SMA syndrome. No new ischemic or hemorrhagic lesions were identified on postoperative imaging. Given the parietal location of the tumor, in close relation to the superior parietal lobule, we hypothesize that disruption of the SLF I — which connects the superior parietal lobule to the SMA proper and pre-SMA along the medial hemispheric surface — contributed to the clinical picture. The deficit progressively improved over the following days, with near-complete motor recovery at follow-up.

Discussion: The SLF I plays a key role in the initiation and higher-order control of body-centered motor activity by linking the superior parietal lobe to the SMA complex and anterior cingulate cortex. Manipulation or disruption of this pathway during resection of parietal lesions adjacent to the SMA territory may produce a clinical picture similar to the classical SMA syndrome, even in the absence of direct cortical SMA injury. Recognizing this entity is important to avoid misdiagnosis as pyramidal weakness or surgical complication, and to provide accurate prognostic counseling, given the favorable course typically observed.

Conclusion: Parasagittal parietal meningioma resection can produce a reversible SMA-like syndrome, likely related to disruption of SLF I connectivity with the SMA complex. Awareness of this fiber tract's role supports preoperative planning and postoperative counseling, emphasizing the favorable functional prognosis.

P232 - Smartphone-based walking activity assessment in spine patients: a comparative preoperative and postoperative analysis of two cases.

Syrine Saadoun, M.Hadhri, G.Belkahla, I.Ferchichi, N.Yahyaoui, M.Darmoul

Neurosurgery Department, Fattouma Bourguiba University hospital, Monastir, Tunisia.

Background: Objective assessment of functional recovery after spine surgery remains challenging, as conventional outcome measures mainly rely on patient-reported questionnaires. Smartphone-based activity tracking provides a simple, accessible, and objective method for monitoring daily mobility through step count and walking distance.

Methods: An Android pedometer application ("Podomètre - Compteur de Pas") was installed on the smartphones of two patients undergoing surgery for degenerative lumbar spine disease. Walking activity, including mean daily step count and mean daily walking distance, was recorded for one month before surgery and three months after surgery to objectively evaluate postoperative functional recovery.

Results: The first patient, a 60-year-old with degenerative lumbar scoliosis presenting with neurogenic claudication and lumbar radiculopathy, demonstrated marked postoperative improvement. Mean daily step count increased from 2,000 to 5,500 steps, while mean daily walking distance increased from 1.2 km to 4.3 km. The second patient, a 66-year-old with degenerative spondylolisthesis and neurogenic claudication, also showed substantial functional gains. Mean daily step count increased from 1,800 to 6,800 steps, and mean daily walking distance improved from 1.0 km to 3.9 km. These objective findings were consistent with favorable clinical recovery following surgery.

Conclusion: Smartphone-based activity tracking is a feasible, low-cost, and objective tool for monitoring postoperative mobility in patients undergoing degenerative spine surgery. The marked improvement in walking activity observed in both cases highlights its potential to complement conventional clinical outcome measures. Larger prospective studies are warranted to validate its clinical utility and establish its role in routine postoperative follow-up.

P233 - Solitary osteochondroma of the atlas arch: an exceptional presentation in a 13-year-old patient

Mohamed Amine Hmida, H.Benselma, A.Mribah, O.Hattab, I.Ksira

Department of Neurosurgery, Sahloul Hospital, Sousse, Tunisia

Background: Osteochondromas typically affect long bones. Spinal involvement is rare, accounting for only 1% to 4% of all cases, and an isolated location on the atlas (C1) is exceptional. We report a rare case of a solitary osteochondroma arising from the posterior arch of the atlas in a pediatric patient.

Case description: A 13-year-old female presented with a painless, deep posterior left cervical mass that had been progressing over 5 months, without any associated neurological deficits. Computed tomography (CT) and magnetic resonance imaging (MRI) revealed a well-circumscribed bony outgrowth arising from the left posterior arch of C1. The lesion featured a central bone matrix with a 15-mm peripheral cartilaginous cap, extending into the intervertebral space (C1-C2) and narrowing the spinal canal with mass effect on the spinal cord. The patient underwent complete monobloc surgical excision of the tumor in a prone position. Histopathological examination confirmed the diagnosis of benign osteochondroma. Postoperative recovery was uneventful with an excellent functional outcome.

Discussion & conclusion: High cervical osteochondromas are extremely rare and typically present during puberty when bone growth is maximal. Although often asymptomatic, their proximity to vital neurovascular structures, such as the upper spinal cord and vertebral artery, poses a potential clinical risk and significant surgical challenges due to their hard bony consistency. Advanced imaging (CT and MRI) is essential to define the tumor components and anatomical relationships. Complete surgical removal of the tumor along with its cartilaginous cap remains the treatment of choice to achieve a favorable long-term prognosis and prevent recurrence.

P234 - Solitary vertebral plasmacytoma: report of two cases and literature review

Sara Dellaldja, K. Boustil, CH. Zair, N. Laib, M. Moussaoui, L. Atroune

EHS ALI AIT AIDIR, Algiers, Algeria

Background: Solitary bone plasmacytoma is a rare primary malignant bone tumor characterized by monoclonal proliferation of plasma cells confined to a single bone lesion. The vertebral column is the most frequently affected site. Diagnosis is based on histopathological confirmation and exclusion of systemic multiple myeloma. We report two cases of vertebral plasmacytoma and review the current literature.

Methods: Two patients with solitary vertebral plasmacytoma were treated in our department. The first patient, a 60-year-old woman, presented with paraplegia and urinary incontinence. Spinal MRI revealed collapse of the T6 vertebral body with epidural compression. She underwent surgical decompression, and histopathological examination confirmed plasmacytoma. The second patient, a 45-year-old woman, presented with predominant right-sided paraparesis. Spinal MRI demonstrated a tumor causing spinal cord compression at the T4 level. Surgical resection was performed, and histopathology also confirmed plasmacytoma.

Results: Both patients underwent surgical decompression because of significant neurological deficits. Histopathological analysis established the diagnosis of solitary vertebral plasmacytoma. Postoperative management included referral for adjuvant oncological treatment and long-term surveillance for progression to multiple myeloma.

Conclusions: Solitary vertebral plasmacytoma is a rare malignant tumor of the axial skeleton. Radiotherapy remains the standard treatment, whereas surgery is indicated in patients with neurological deficits or spinal instability. Long-term follow-up is essential because of the significant risk of progression to multiple myeloma.

P235 - Sparing the growing spine: magnetic controlled growth rods for early-onset progressive scoliosis

Mohamed Amine Rachdi, Affes A, Hdhili H, Bouzouita K, Achoura S, Chkili Ridha, Radhouen K.

Neurosurgery Department, Military Hospital of Tunis, Tunis, Tunisia

Background & objectives: Early-onset scoliosis (EOS) poses a unique therapeutic challenge: correcting spinal deformity while preserving the growth potential of the immature spine and thoracic cage. Traditional growing rod constructs require repeated surgical lengthening procedures every 6 months, exposing children to cumulative anesthetic risk, surgical site complications, and significant psychosocial burden. Magnetic controlled growing rods (MCGR), introduced to allow non-invasive, outpatient distraction via external magnetic remote control, represent a paradigm shift in EOS management. This review critically appraises current evidence on MCGR efficacy, complications, and long-term outcomes compared to traditional growing rod systems.

Methods: Narrative review of PubMed, Scopus, and Cochrane databases (2010–2024), including prospective cohort studies, comparative series, and systematic reviews evaluating MCGR outcomes, distraction mechanics, complication rates, and final fusion results in patients with early-onset progressive scoliosis.

Results & discussion: Efficacy: MCGR achieves comparable curve correction and spinal growth preservation relative to traditional growing rods, with mean Cobb angle reduction of 30–40% and consistent spinal length gain across reported series, while eliminating the need for repeated open lengthening surgeries. Surgical burden reduction: Patients undergoing MCGR require significantly fewer surgical procedures, translating into reduced cumulative anesthesia exposure, lower infection rates, and improved quality of life and psychosocial outcomes for both children and families. Complications: Rod-specific complications include the "law of diminishing returns" — progressive loss of distraction capacity after repeated lengthenings — implant failure, and metallosis at the actuator-rod interface. Autofusion of the construct may also limit ultimate correction potential. Final fusion outcomes: Definitive spinal fusion following MCGR treatment demonstrates curve correction and complication profiles comparable to conventional growing rod pathways, supporting MCGR as a viable bridge strategy to skeletal maturity.

Conclusion: Magnetic controlled growth rods successfully reduce surgical burden while preserving spinal growth in early-onset progressive scoliosis, though mechanical limitations over time warrant careful long-term follow-up and judicious patient selection.

P236 - Spinal AVM rupture presenting as isolated fourth ventricular hemorrhage: a case report and review of the literature

Ameur Affes, Farhat S, Kammoun T, Bouzouita K, Kammoun H, Yedeas MD, Achoura S, Chkili R, Radhouane K

Neurosurgery Department, Military Hospital of Tunis, Tunis, Tunisia

Background: Spinal arteriovenous malformations (AVMs) are rare and often present with progressive myelopathy or acute neurologic deficits due to hemorrhage. Intraventricular hemorrhage, particularly isolated to the fourth ventricle, is an unusual and misleading presentation that can delay accurate diagnosis.

Case description: An active-duty male servicemember in his 30s presented to the emergency department with sudden-onset occipital headache, vertigo, vomiting, and transient loss of consciousness during routine physical training. Neurological examination revealed mild truncal ataxia without focal deficits. Non-contrast head CT revealed isolated hemorrhage within the fourth ventricle. Initial CT angiography of the head and neck was unremarkable. Due to the unusual location of bleeding and absence of intracranial vascular pathology, spinal imaging was pursued.MRI of the spine revealed abnormal flow voids and signal changes at the mid-thoracic level, suggestive of a vascular malformation. Spinal digital subtraction angiography confirmed the presence of a ruptured thoracic spinal AVM with venous drainage into perimedullary veins. The patient underwent successful endovascular embolization and was managed in a neurocritical care setting with gradual clinical improvement.

Discussion: This case underscores the diagnostic challenge posed by spinal AVM rupture presenting with isolated fourth ventricular hemorrhage. In the absence of supratentorial or posterior fossa lesions, clinicians must maintain a high index of suspicion for spinal sources, particularly in younger, otherwise healthy patients. Early spinal imaging is critical when brain imaging fails to reveal a cause for infratentorial bleeding.

Conclusion: Spinal AVMs, though rare, should be part of the differential diagnosis in unexplained fourth ventricular hemorrhage. Prompt recognition and intervention are vital to prevent rebleeding and long-term neurological morbidity—particularly relevant in military populations, where functional recovery and return to duty are key goals.

P237 - Spinal cord compression as the initial manifestation of disseminated metastatic solitary fibrous tumor

Khalil Ayadi, A. Farikh, F Kolsi, B Kammoun, MZ Boudawara

Department of neurosurgery, Habib Bourguiba University Hospital, Sfax, Tunisia

Background: Solitary fibrous tumor/hemangiopericytoma (SFT/HPC) is a rare mesenchymal neoplasm characterized by aggressive biological behavior, with a high propensity for local recurrence and delayed extracranial metastases. Spinal metastatic dissemination is uncommon but may occur many years after treatment of the primary intracranial lesion, resulting in significant neurological morbidity.

Methods: We report the case of a 47-year-old man who underwent gross total resection of an intracranial hemangiopericytoma in 2012 followed by adjuvant cranial radiotherapy. Fourteen years later, he presented with progressive paraparesis associated with urinary and fecal incontinence. Spinal magnetic resonance imaging (MRI) demonstrated multiple vertebral and epidural metastatic lesions causing spinal cord compression. Whole-body computed tomography (CT) revealed widespread osseous metastases. To establish the diagnosis, a CT-guided biopsy of a rib lesion was performed.

Results: Histopathological examination of the rib biopsy confirmed metastatic solitary fibrous tumor, consistent with dissemination from the previously treated intracranial SFT/HPC. The extensive vertebral and epidural involvement accounted for the patient's progressive neurological deficits and sphincter dysfunction. Owing to the multifocal extent of the disease and diffuse spinal cord compression, the case was discussed at a multidisciplinary tumor board, which recommended palliative spinal radiotherapy. The patient was subsequently referred for radiation treatment.

Conclusions: This case illustrates the potential for exceptionally late metastatic recurrence of intracranial SFT/HPC, occurring 14 years after initial treatment. New neurological deficits in patients with a history of intracranial SFT/HPC should raise suspicion for metastatic spinal disease, even after prolonged disease-free intervals. Long-term surveillance is warranted because of the risk of delayed systemic metastases. Early diagnosis and multidisciplinary management are essential to optimize neurological outcomes and maintain quality of life.

P238 - Spinal cord compression secondary to benign intradural tumors: a comparative multivariate analysis of meningiomas versus schwannomas at the annaba university hospital

Mourad Bouaziz, M. Benamira, Y. Bouaziz

Depatment of Neurosurgery, CHU Annaba, Algeria.

Introduction: Tumoral spinal cord compression (SCC) represents a major functional neurosurgical emergency. Among the various etiologies, benign intradural extramedullary tumors hold a prominent position due to their high potential for complete curability. The purpose of this study is to report our department's experience and to perform a comparative (multivariate) analysis of the clinical and prognostic profiles of spinal meningiomas versus schwannomas.

Material and methods: We conducted a retrospective descriptive and comparative study of a global cohort of 54 patients admitted for non traumatic SCC at the CHU Annaba between 2021 and 2025. A subgroup of 14 patients with histologically confirmed meningioma (n=8) or schwannome (n=6) underwent deep analysis. Demographic variables, diagnostic delays (onset of symptoms to admission), topographical findings on MRI, and neurological outcomes (ASIA impairment scale) were analyzed and cross-referenced.

Results: Univariate analysis demonstrated that global tumor pathology dominated the series (71% of cases), with benign tumors accounting for 26% of the overall cohort. The comparative analysis highlighted two distinct clinical profiles: The "Meningiome" Profile (n=8): Characterized by a strong female predominance (75%), a mean age of 49.4 years, and a localization restricted to the cervical (25%) or thoracic (75%) segments. The mean diagnostic delay was particularly prolonged (273 days), reflecting a slow tumor growth kinetics and progressive spinal cord tolerance. The "Schwannome" Profile (n=6): Distinguishable by an equal sex distribution (50% F / 50% M), an older mean age (55.8 years), and a wider topographical distribution that included the lumbar spine (17%). The mean diagnostic delay was significantly shorter (120 days). At admission, 71% of the patients presented with an ASIA D score. All patients underwent surgical decompression via a posterior laminectomie approach. The functional recovery rate at 6 months was 100% (ASIA E) for all benign tumors, with no major post-operative complications.

Conclusion: Spinal meningiomas and schwannomas are frequent causes of SCC. Despite differing epidemiological profiles and evolutionary kinetics—with consultation delays doubling from one type to another—their post-surgical functional prognosis remains excellent provided that a macroscopically complete resection is achieved. Emphasis must be placed on training primary care physicians to reduce the persistent diagnostic delays observed in our region.

P239 - Spontaneous idiopathic grade III intraventricular hemorrhage in a full-term neonate

Bensalem Khadidja, N.Gasmi

Department of Neurosurgery, CHU Sidi Bel Abbès, Algeria

Introduction (background & objectives): Grade III intraventricular hemorrhage (IVH) based on the Papile classification is a well-documented pathological entity typically seen in preterm infants due to germinal matrix fragility. Its occurrence in a full-term neonate, without any evident mechanical trauma or bleeding disorder, represents an extremely rare clinical occurrence, accounting for less than 5% of all neonatal intracranial hemorrhages. This study analyzes the clinical and radiological markers of a massive, idiopathic term IVH to dissect its underlying causal mechanism.

Methods (case presentation): A 9-day-old full-term female neonate (39 weeks) was admitted following vaginal delivery from an uneventful pregnancy. The maternal medical history was unremarkable, with no maternal-fetal Rh incompatibility. Crucially, prophylactic Vitamin K was correctly administered at birth. There was absolutely no history of obstetric or accidental trauma. Clinical examination revealed acute intracranial hypertension signs: a tense, bulging anterior fontanelle, pan-sutural diastasis, and generalized hypotonia. Complete coagulation profiles were strictly normal, excluding systemic bleeding disorders.

Neuroradiological evaluation: https://imgur.com/a/C4oy79v Non-contrast CT imaging demonstrated a massive 68 mm intraventricular hematoma centered on the left choroid plexus, causing Papile Grade III breakthrough and bi-ventricular hydrocephalus (Evans Index: 0.36) with clear signs of transependymal CSF resorption. Volumetric skull reconstructions confirmed major pan-sutural splitting without any underlying fracture or signs of mechanical impact.

Discussion & conclusion: When trauma and systemic coagulopathies are rigorously excluded, a localized choroid plexus bleed in a full-term infant represents a true idiopathic enigma. The focal nature of the 68 mm clot strongly implicates a hidden, cryptic microvascular anomaly or a primary focal venous thrombosis. While an emergency ventricular tap temporarily mitigates the mechanical mass effect, identifying the true cause of this idiopathic presentation strictly requires delayed high-resolution Brain MR Angiography (MRA) once the acute hematoma resolves.

P240 - Spontaneous intracranial hypotension revealed by paroxysmal orthostatic headache

Asma Agrebaoui, R. Zouari, Y. Boubaker, S. Jelassi, D. Ben Mohamed, A. Rachdi, F. Nabli, Z. Saied, S. Nagi, S. Ben Sassi

[1]. Department of Neurology, National Institute of Neurology Mongi Ben Hamida, Tunis, Tunisia
[2]. Department of Radiology, National Institute of Neurology Mongi Ben Hamida, Tunis, Tunisia

Background: Spontaneous intracranial hypotension (SIH) is an uncommon neurological disorder caused by spontaneous cerebrospinal fluid (CSF) leakage at the spinal level. It typically presents with orthostatic headache and may be challenging to diagnose because of its variable clinical and radiological manifestations.

Methods: We report a case of SIH revealed by recurrent paroxysmal orthostatic headaches.

Results: A 21-year-old woman with no significant medical history was admitted for recurrent paroxysmal headaches evolving over two months, characterized by alternating periods of frequent attacks and symptom-free intervals. There was no history of spinal trauma, lumbar puncture, spinal anesthesia, or spinal surgery. The headaches were severe, described as a tightening sensation involving the periorbital region and vertex. They were aggravated by the upright position and relieved by recumbency, without associated nausea, vomiting, photophobia, or phonophobia. Neurological and ophthalmological examinations were normal. Brain magnetic resonance imaging (MRI) revealed diffuse smooth pachymeningeal enhancement, raising suspicion of SIH. Spinal MRI demonstrated dorsal extradural fluid collections suggestive of CSF leakage. CT myelography identified contrast extravasation within the right posterolateral epidural space extending from T10 to T12, associated with a right-sided meningeal diverticulum at the T12–L1 level. An epidural blood patch was performed, resulting in complete resolution of symptoms within three days. Follow-up brain and spinal MRI showed complete disappearance of the previously observed abnormalities.

Conclusions: SIH should be considered in patients with orthostatic headache, even when the presentation is paroxysmal. Brain and spinal MRI are essential for diagnosis, while CT myelography remains crucial for precise leak localization and therapeutic planning. In this case, identification of a thoracic posterolateral leak associated with a meningeal diverticulum allowed effective treatment with a single epidural blood patch, resulting in excellent clinical and radiological recovery.

P241 - Spontaneous resolution of acute hydrocephalus following aneurysmal subarachnoid hemorrhage: external ventricular drainage or observation

Roua Latrach, E. Elouni, F. Sliti, N. Nessib, A. Slimane, K. Ghedira, K. Abderrahmen, S. Bouali, I. Ben Said, J. Kallel

National Institute of Neurology, Tunis, Tunisia

Acute hydrocephalus is a frequent and potentially life-threatening complication of aneurysmal subarachnoid hemorrhage (SAH). Clinical presentation ranges from preserved consciousness to profound coma, depending on the severity of ventricular dilatation and the resulting increase in intracranial pressure. Given its potentially fatal course, prompt recognition and management are essential, and patients requiring external ventricular drainage (EVD) are generally considered for urgent surgical intervention. We report the case of a 50-year-old man who was admitted to the cardiology department for the treatment of infective endocarditis. During hospitalization, he suddenly developed severe headache and repeated vomiting, without seizures, associated with fluctuating somnolence. An urgent cranial computed tomography scan revealed a subarachnoid hemorrhage secondary to the rupture of a mycotic aneurysm, accompanied by acute hydrocephalus. The patient was immediately transferred to our neurosurgical department for emergency external ventricular drainage. Upon arrival, however, the patient had regained full consciousness and reported a noticeable improvement in his headache. A repeat CT scan was obtained prior to surgery and, unexpectedly, demonstrated complete resolution of the hydrocephalus. Consequently, surgical intervention was deferred, and the patient was returned to the cardiology department. No subsequent neurological deterioration was observed during follow-up. Spontaneous resolution of acute hydrocephalus has been described predominantly in pediatric patients, whereas reports in adults remain exceedingly rare. The exact mechanisms underlying this phenomenon are poorly understood but may involve the clearance of obstructive blood products or transient normalization of intracranial pressure dynamics. This case highlights that, although acute hydrocephalus often necessitates urgent cerebrospinal fluid diversion, the decision to perform external ventricular drainage should be based on a careful correlation of clinical and radiological findings. In selected stable patients demonstrating rapid neurological improvement, repeat imaging may be valuable before proceeding with invasive treatment. Nevertheless, close monitoring remains mandatory, as delayed neurological deterioration may occur and can be life-threatening.

P242 - Sports participation in patients with ventriculoperitoneal shunts: a review of current evidence and recommendations

Emna Elouni, Roua Latrach, Nessrine Nessib, Firas Sliti, Slimane Abdelhafidh, Imed Ben Said, Jalel Kallel

Neurosurgery Departement, National Institute of Neurology, Tunis, Tunisia

Background: Ventriculoperitoneal (VP) shunting remains the most widely used treatment for hydrocephalus. As survival and quality of life continue to improve, patients and families increasingly seek guidance regarding participation in sports and physical activities. However, concerns persist regarding shunt malfunction, catheter fracture, head trauma, and intracranial injury during athletic participation. The objective of this review is to summarize the available evidence regarding sports participation in individuals with VP shunts and to provide practical recommendations for clinical practice.

Materials and methods: A narrative review of the literature was conducted using published studies, surveys of pediatric neurosurgeons, and institutional recommendations addressing sports participation in patients with cerebrospinal fluid shunts. Data regarding sport-related complications, physician recommendations, and return-to-play considerations were analyzed.

Results: Available evidence suggests that sport-related complications in patients with VP shunts are uncommon. A large survey of pediatric neurosurgeons reported that over 75% had never encountered a sport-related shunt complication, with an estimated incidence of less than 1%. Most neurosurgeons allow participation in non-contact sports without restriction. Recommendations regarding contact and collision sports remain heterogeneous, ranging from unrestricted participation to complete avoidance. Recent survey data demonstrated that approximately 80% of pediatric neurosurgeons would permit adolescents with VP shunts to participate in contact rugby, often with the use of protective headgear. Activities such as swimming, running, cycling, and recreational fitness programs are generally considered safe after adequate postoperative recovery. Individual risk assessment remains essential, particularly in patients with multiple shunt revisions, associated neurological deficits, or previous shunt-related complications.

Conclusion: Current evidence indicates that participation in most sports is safe for patients with VP shunts, with a very low incidence of sport-related complications. Non-contact sports should generally be encouraged because of their physical and psychosocial benefits. Decisions regarding contact sports should be individualized, taking into account patient characteristics, shunt history, and neurosurgical advice. Further prospective studies are required to establish evidence-based guidelines for return-to-play recommendations in this population.

P243 - Squamous cell carcinoma revealing a glioblastoma

Mohammed Al Amine El Farissi, Mohamed Dahamou, Hamid Khay, Khoulali Mohamed

Department of Neurosurgery, Mohammed VI University Hospital, Faculty of Medicine and Pharmacy of Oujda, Mohammed First University, Oujda, Morocco.

Introduction: We report a rare case of synchronous poorly differentiated squamous cell carcinoma (SCC) of the pharynx and glioblastoma in a 45-year-old chronic smoker.

Clinical presentation: The patient presented with proptosis revealing local extension of pharyngeal SCC. Staging brain MRI showed a non-enhancing left parietal T1-isointense lesion. Biopsy confirmed glioblastoma. Management: The patient was referred to an oncology center for chemoradiotherapy.

Conclusion: This case highlights the possible synchronous occurrence of two distinct primary malignancies – a pharyngeal carcinoma and a glioblastoma – warranting thorough staging workup in patients with known head and neck cancers.

P244 - Steppage gait: etiological, clinical, and electroneuromyography diagnosis

Elleuch. Wafa[1], [4], Mallek.A[1], Gahbich.F[3], Kolsi.F[3], Elleuch Mh[2] [4]

[1] Physical medicine department, Military university hospital of sfax , Tunisia

[2] Department of Physical Medicine, Habib Bourguiba Hospital of Sfax, Tunisia

[3] Department of Neurosurgery, Habib Bourguiba Hospital of Sfax, Tunisia

[4] Research Unit for the Evaluation of Musculoskeletal Disorders (04/UR/08-07), University of Sfax, 3000, Tunisia

[5] General surgery Department , Military university hospital of sfax , Tunisia

Steppage gait is a neurologically induced paralysis of the muscles responsible for dorsiflexion of the foot and toes. It may be secondary to L5 radiculopathy or to involvement of the common peroneal nerve (external popliteal sciatic nerve). The objective of our study is to highlight the importance of clinico-electrophysiological reasoning in cases of steppage gait in order to identify the level of the lesion, based on two patients who presented with steppage. Observation 1: Patient 1, 28 years old , whose clinical examination revealed hypoesthesia over the anterior aspect of the dorsum of the left foot. Muscle testing on the left side showed: tibialis posterior (TP) 5/5; fibularis muscles (FM) 5/5; tibialis anterior (TA) 2/5, with varus of the left hindfoot during the swing phase of gait, thus suggesting a lesion of the common peroneal nerve (CPN). Electroneuromyography (ENMG) confirmed a motor conduction block of the common peroneal nerve, associated with sensory involvement, and a rich interference pattern in motor unit potentials in the tibialis posterior muscle. Observation 2: Patient 2, aged 55 years, with a history of surgically treated L4–L5 disc herniation. Clinical examination of the left lower limb revealed no sensory deficit. Muscle testing showed: TP 2/5; FM 5/5; TA 2/5, with absence of hindfoot varus during the swing phase of gait. ENMG showed motor involvement sparing the sensory nerves, along with a neurogenic pattern in the tibialis posterior muscle, which was in Favor of L5 radiculopathy.

Conclusion: Clinical examination is of paramount importance and, when combined with EMG, allows precise lesion mapping and provides the surgeon with appropriate therapeutic options.

P245 - Suprascapular nerve block in the treatment of adhesive capsulitis

Atika Mallek, Elleuch.W[1 4], Gahbich.F[3], Kolsi.F[3], Azaza. M[5], Elleuch Mh[2 4]

[1] Physical medicine department, Military university hospital of sfax , Tunisia

[2] Department of Physical Medicine, Habib Bourguiba Hospital of Sfax, Tunisia

[3] Department of Neurosurgery, Habib Bourguiba Hospital of Sfax, Tunisia

[4] Research Unit for the Evaluation of Musculoskeletal Disorders (04/UR/08-07), University of Sfax, 3000, Tunisia

[5] General surgery Department , Military university hospital of sfax , Tunisia

Introduction: The objective of this study is to evaluate the effectiveness of the suprascapular nerve block in patients with adhesive capsulitis.

Materials and methods: Thirteen patients with adhesive capsulitis were included. They underwent an ultrasound-guided suprascapular nerve block (injection of 5 cc of ropivacaine), followed by physiotherapy exercises in order to improve shoulder's range of motion. Evaluation was performed before and after the block using goniometric measurements of joint range of motion (notably forward elevation [FE], lateral elevation [LE], and external rotation [ER]) and the Constant score to assess functional impact.

Results: The study included thirteen patients (6 women and 7 men), with a mean age of 35.50 years (±5.77) and a mean symptom duration of 21 months (±12.60). Immediately after the nerve block, pain decreased significantly (VAS reduced from 8 ± 1.04 to 4.33 ± 1.9; p = 0.05). An improvement in all joint ranges of motion was observed after the block. Forward elevation (FE) increased on average from 138.11° ± 35.27° to 163.33° ± 25.82° (mean gain of 12.33 ± 30.76); lateral elevation (LE) from 91.67° ± 56.67° to 100.43° ± 34.57°; and external rotation (ER) from 34.67° ± 15.26° to 48.33° ± 14.72°. The Constant score improved from 37.57 ± 16.33 to 70.50 ± 6.02.

Conclusion: Our results show that the suprascapular nerve block appears to be an effective therapeutic option in the management of adhesive capsulitis, helping to reduce pain and improve function in patients who have not responded to conventional treatments.

P246 - Surgery of lesionnal epilepsy

Abdelaziz Bennadji, Ouarda Guerza, Ouarda Zeroual, Abdelhak Benzid, Zakia Guerfi, Samir Sebane.

University Batna, Batna university hospital center, Algeria

Background: Epilepsy, with a prevalence of 0.5 to 1 per cent, is one of the most common neurological conditions. More than half of people with epilepsy have partial epilepsy, of whom 20 to 40 % are poorly controlled by drug treatment. It is estimated that one third of these patients are potential candidates for surgery. Surgery should not be regarded as a 'last resort' treatment. Epilepsy surgery is now a well-established alternative that deserves to be considered much earlier in the course of the disease. Clinical case 1 A 46-year-old single woman, a known epilepsy patient who has been followed up for 20 years by her neurologist, was referred to us for consultation regarding drug-resistant epilepsy whilst on four antiepileptic drugs, with a brain MRI showing a temporal lobe lesion suggestive of a DNET. The onset appears to date back 20 years, when the patient was being treated for generalized seizures with 4 drugs without controle. Finally, the doctor concluded that this was a case of drug-resistant epilepsy and requested an MRI scan, which revealed a temporal lesion suggestive of a DNET and oriented to neurosurgery. The patient underwent surgery; the histology confirmed a ganglioglioma. Clinical case 2 A 17-year-old male presenting with a basifrontal lesion manifested by partial epileptic seizures that were becoming more frequent despite treatment. A resection was performed and the histology confirmed a DNET.

Results and discussion: A marked clinical improvement was observed in both cases: reduction to one seizure the three first months post-operatively with Levetiracetam and Lamotrigine for the first case, and no seizures for the second case. Both patients present with secondary epilepsy that is drug-resistant from a very early stage of follow-up. Relying solely on a CT scan for secondary drug-resistant epilepsy is inadequate; an MRI is clearly indicated. The MRI was suggestive of a DNET: a rounded lesion, predominantly T1-hyposignal and T2-hypersignal with sharp margins. However, histological examination reveals neuronal cells of a ganglionic type with a larger appearance. The location of the tumor is a major prognostic factor in terms of mortality and post-operative recurrence. The surgical prognosis is therefore excellent, with a 10-year survival rate of close to 95 %, particularly in cases of complete resection.

Conclusion: Although epilepsy surgery is still in its infancy in Algeria, it has a clear role to play in the treatment of drug-resistant epilepsy; consequently, a multidisciplinary approach involving neurologists, neurosurgeons, neurophysiologists and pharmacists is essential.

P247 - Surgical management of carpal tunnel syndrome: a single-center case series evaluating clinical outcomes

Farah Bahri, G.Gader, H.Hdhili, S.Ben Yakoub, M. Bounemra, A.Hermassi, S.Ben Zekri, A.Bedioui, M.Rkhami, M.Badri, K.Bahri, I.Zammel

Department of Neurosurgery, Ben Arous Trauma Center, Tunisia

Background: Carpal tunnel syndrome (CTS) is the most common entrapment neuropathy, resulting from compression of the median nerve within the carpal tunnel. Although conservative treatment may alleviate symptoms in mild cases, surgical decompression remains the treatment of choice for patients with persistent symptoms, severe nerve compression, or motor deficit. This study aimed to evaluate the clinical presentation, surgical outcomes, and postoperative evolution of patients undergoing carpal tunnel release at our institution.

Methods: We conducted a retrospective review of consecutive patients who underwent surgical decompression for CTS in our department. Demographic characteristics, clinical presentation, electrophysiological findings, surgical technique, perioperative complications, and postoperative outcomes were analyzed. Functional recovery was assessed based on symptom relief, sensory improvement, motor recovery, and patient-reported satisfaction during follow-up.

Results: The series included patients presenting predominantly with paresthesia, sensory disturbances, and variable thenar muscle weakness. Electrophysiological studies confirmed median nerve compression in all cases. Open carpal tunnel release was performed in all patients without major intraoperative complications. Most patients experienced progressive sensory recovery and functional improvement during follow-up. Persistent symptoms were uncommon and were mainly observed in patients with long-standing disease or severe preoperative nerve impairment. No cases of permanent median nerve injury or wound infection were observed.

Conclusions: Surgical decompression of the carpal tunnel is a safe and effective procedure that provides significant symptomatic relief and functional recovery in patients with CTS. Careful patient selection, timely surgical intervention, and meticulous operative technique are key determinants of favorable outcomes. Early treatment before irreversible median nerve damage may further optimize postoperative recovery.

P248 - Surgical management of chronic subdural hematoma in adults and risk factors for recurrence: a retrospective study of 126 patients

Balkis Essid, F. Kolsi, K.Ayedi, F.Gahbiche, H.Najjar, M.Tallah, S.Abdelmoulah, M.Borni, S. Chaari, B. Kammoun, MZ. Boudawara

Department of Neurosurgery, Hbib Bourguiba University Hospital, Sfax , Tunisia

Background: Chronic subdural hematoma (CSDH) is a common neurosurgical condition, particularly in the elderly. Despite surgical treatment, recurrence rates remain significant. Identifying risk factors for recurrence is crucial for optimizing management.

Methods: A retrospective analytic longitudinal study included 126 adult patients surgically treated for CSDH at Habib Bourguiba University Hospital, Sfax (January 2018 – December 2023). Data covered epidemiology, clinical presentation, radiology, surgical techniques, and outcomes. Univariate analysis identified recurrence risk factors.

Results: Median age was 69 years (range 35–92); 80.2% were >60 years. Male predominance was marked (sex ratio 3.34). Head trauma history was reported in 58.7% (92% minor). Motor deficit was the most common finding (72.2%). Burr hole evacuation was performed in 72.2%, craniotomy in 20.6%, and trephine in 7.1%. Favorable outcome occurred in 73.8%. Recurrence rate was 17.5% (22 patients), with median time to recurrence of 30 days. Factors significantly associated with lower recurrence risk were: craniotomy ($p=0.044$), postoperative corticosteroids ($p=0.03$), and postoperative atorvastatin ($p<0.001$). Preoperative antiplatelet use was significantly associated with higher recurrence risk ($p<0.001$). Mortality was 1.6%.

Conclusions: CSDH predominantly affects elderly males with minor head trauma. Burr hole evacuation remains the first-line surgical technique. Postoperative atorvastatin and corticosteroids appear to reduce recurrence risk, while antiplatelet use increases it. These findings may guide risk stratification and adjuvant therapy decisions

P249 - Surgical management of drug-resistant epilepsy in children: indications and outcomes

Emna Mzoughi, Nesrine Nessib, Alaa Belhadj, Sofiene Bouali, Khalil Ghedira, Ichraf Kraoua, Kansa Abderrahmen

Department of neurosurgery , National Institute of Neurology, Tunisia.

Introduction: Drug-resistant epilepsy in children is associated with major neurological, cognitive, and behavioral consequences. Surgery may offer significant seizure control and developmental improvement when an epileptogenic focus is identified or when palliative treatment is indicated. This study aimed to evaluate the indications, surgical strategies, and outcomes of pediatric epilepsy surgery.

Methods: We retrospectively reviewed seven children who underwent surgery for drug-resistant epilepsy. Clinical data, age at epilepsy onset, seizure type and frequency, psychomotor and behavioral status, EEG findings, brain MRI abnormalities, clinico-electro-radiological correlation, surgical procedure, and postoperative outcome were analyzed.

Results: Seven patients were included. The mean age at epilepsy onset was 6.4 months, ranging from 7 days to 20 months. All patients presented with multiple daily seizures, which were focal in five cases. Psychomotor regression was observed in four patients, and behavioral disorders in six. EEG showed focal epileptiform abnormalities in five cases and generalized abnormalities in two. Brain MRI revealed focal cortical dysplasia in four cases and an internal temporal cystic lesion in one case. Lennox-Gastaut syndrome was diagnosed in two patients. A clinico-electro-radiological correlation was found in five cases. The mean duration of epilepsy before surgery was 6.5 years. Surgical procedures included lesionectomy in two cases, vagus nerve stimulation in two, callosotomy in one, amygdalo-hippocampectomy in one, and hemispherotomy in one. Outcome was favorable in all patients, with seizure freedom in three cases, seizure reduction in three, and cognitive improvement in five.

Discussion: Our results support the effectiveness of surgery in pediatric drug-resistant epilepsy. A focal epileptogenic zone identified by EEG and imaging remains a major criterion for curative surgery. In patients without a clearly defined resectable lesion, particularly those with Lennox-Gastaut syndrome, vagus nerve stimulation represents an appropriate palliative option. The choice of procedure should be individualized according to electroclinical data, imaging findings, lesion accessibility, and functional risk.

Conclusion: Pediatric epilepsy surgery remains underused and often delayed despite its proven benefits. Early referral to specialized centers and standardized preoperative evaluation, including neuropsychological assessment, long-term EEG monitoring, and dedicated structural and functional imaging, are essential to optimize seizure control and cognitive outcome.

P250 - Surgical management of sellar and parasellar meningiomas: clinical outcomes and technical nuances

Hallaci Azzedine, S.Messai, R.Mahdaoui, , Z.Mechiche.

Neurosurgery Department, Setif, Algeria.

Background: Meningiomas of the sellar and parasellar regions represent a complex surgical challenge due to their close proximity to critical neurovascular structures, including the optic chiasm, internal carotid arteries, and cavernous sinuses. This study evaluates the clinical presentation, surgical approaches, and long-term visual and endocrinological outcomes in a series of patients operated on for sellar region meningiomas.

Methods: We retrospectively reviewed the medical records of patients who underwent surgical resection for sellar region meningiomas in our neurosurgery department. Data regarding clinical symptoms, neuroimaging characteristics, surgical , extent of resection (Simpson grading), and postoperative complications were analyzed.

Results: The most common initial symptom was visual impairment. Total or near-total tumor resection (Simpson Grade I–III) was achieved in the majority of cases. The choice of surgical corridor was tailored based on the tumor's extension and its relationship with the optic apparatus. Postoperatively, a significant portion of patients experienced stabilization or improvement in visual acuity and visual fields. New-onset endocrinological deficits or transient cranial nerve palsies were carefully managed. Long-term follow-up showed low recurrence rates, primarily managed with stereotactic radiosurgery for residual cavernous sinus disease.

Conclusion: Surgical management of sellar region meningiomas requires a multidisciplinary strategy and a tailored approach to maximize tumor resection while preserving neurological function. Microsurgical allow for safe optic nerve decompression, which remains the primary goal to improve long-term functional and quality-of-life outcomes.

P251 - Survey on the impact of staphylococcus aureus virulence factors in spondylodiscitis and neurosurgical infections

Oumaima Rmida, W.Mansour, R.Zemni

Faculty of Medecine Sousse, Tunisia

Background: Staphylococcus aureus is one of the leading pathogens responsible for severe spinal and neurosurgical infections, particularly spondylodiscitis and postoperative implant-associated infections. Its pathogenicity is mainly related to multiple virulence factors including adhesins, toxins, biofilm formation, and immune evasion mechanisms, which contribute to tissue destruction, chronic infection, and antibiotic resistance. These infections remain a major challenge in neurosurgical practice due to their morbidity and therapeutic complexity.

Méthodes: A descriptive survey composed of 18 questions was conducted among neurosurgery residents to assess the perceived impact, severity, diagnostic challenges, and prevention strategies related to Staphylococcus aureus infections. Data from the survey were analyzed and correlated with recent literature focusing on molecular virulence mechanisms involved in spinal infections.

Résultats: The survey revealed that Staphylococcus aureus infections are considered among the most feared postoperative complications in neurosurgery due to their severity, recurrence risk, and therapeutic difficulty, particularly in resistant strains. Implant-associated infections and postoperative meningitis were identified as major clinical concerns. Residents highlighted the important role of bacterial virulence factors such as biofilm formation, fibronectin-binding proteins, Protein A, hemolysins, and leukocidins in infection persistence and tissue damage. The study also emphasized the importance of early diagnosis, strict aseptic measures, and optimized antimicrobial strategies to reduce complications.

Conclusions: Staphylococcus aureus virulence factors play a major role in the pathogenesis and persistence of spondylodiscitis and neurosurgical infections. The survey findings confirm the significant clinical burden of these infections and underline the importance of molecular understanding, prevention strategies, and multidisciplinary management to improve patient outcomes.

P252 - Switching on desire: deep brain stimulation as an emerging tool for sexual dysfunction

Firas Akrout, Rachdi M.A., Kammoun T, Bouzouita K, Achoura S, Chkili Ridha, Radhouen K.

Neurosurgery Department, Military Hospital of Tunis, Tunis, Tunisia

Background & objectives: Deep brain stimulation (DBS), an established therapy for movement disorders and increasingly explored in psychiatric and behavioral conditions, has revealed unexpected and clinically significant effects on sexual function. Observations of both induced hypersexuality and restored libido following stimulation of specific neural targets suggest a previously underexplored therapeutic avenue for refractory sexual dysfunction. This review critically examines current evidence on DBS-related sexual effects and its emerging potential as a deliberate therapeutic tool.

Methods: Narrative review of PubMed, Scopus, and Cochrane databases (2000–2024), including case series, prospective cohort studies, and mechanistic reports describing sexual function changes associated with DBS across approved and investigational targets.

Results & discussion: Subthalamic nucleus stimulation: DBS for Parkinson's disease frequently reveals bidirectional sexual effects — hypersexuality has been reported in 2–4% of patients, attributed to mesolimbic dopaminergic pathway modulation, while others experience restored desire and arousal previously suppressed by disease progression or dopaminergic medication withdrawal, highlighting the circuit's therapeutic plasticity. Hypothalamic and septal targets: Stimulation of the posteromedial hypothalamus and septal region, primarily investigated for cluster headache and aggressive behavior, demonstrates incidental modulation of libido and arousal, suggesting these structures as potential deliberate targets for desire-related dysfunction. Nucleus accumbens and reward circuitry: As the central hub of motivational and reward processing, nucleus accumbens stimulation in treatment-resistant depression and obsessive-compulsive disorder trials has incidentally restored sexual interest, reinforcing the circuit's role in libido beyond purely psychiatric symptom relief. Clinical and ethical considerations: Current evidence remains exclusively derived from incidental observations within trials targeting other primary conditions; no dedicated prospective trial has evaluated DBS specifically for primary sexual dysfunction, and the ethical boundary between treating dysfunction and pursuing enhancement requires careful delineation.

Conclusion: DBS-induced modulation of sexual function represents a genuine but currently incidental therapeutic signal. Dedicated prospective investigation is warranted before DBS can be considered a deliberate, ethically grounded tool for refractory sexual dysfunction.

P253 - Synchronous glioblastoma and poorly differentiated pharyngeal squamous cell carcinoma: a rare diagnostic challenge

Hamid Khay, Amine Kada, Yassine El Hilali, Mohamed Dahamou, Mohammed Al Amine El Farissi, Mohammed Khoulali

University hospital Center Mohammed VI Oujda, Morocco

Background: Glioblastoma is the most common and most aggressive primary malignant brain tumor in adults. Its rapid infiltrative growth, marked therapeutic resistance, and poor prognosis make early diagnosis essential. The coexistence of glioblastoma with another primary malignancy is exceptionally rare and may pose significant diagnostic and therapeutic challenges.

Case presentation: We report the case of a 45-year-old man with a history of chronic tobacco use who was diagnosed with a poorly differentiated pharyngeal squamous cell carcinoma presenting with local extension and exophthalmos. During staging investigations, brain magnetic resonance imaging revealed an unexpected left parietal T1 isointense lesion without contrast enhancement. Because the imaging findings were atypical for metastatic disease, a stereotactic biopsy was performed. Histopathological examination demonstrated glioblastoma characterized by pleomorphic hyperchromatic tumor cells associated with microvascular proliferation, hemorrhage, and extensive necrosis. The diagnosis established the presence of two distinct primary malignancies rather than cerebral metastatic disease. Following multidisciplinary discussion, the patient was referred to the oncology department for combined radiochemotherapy.

Discussion: The simultaneous occurrence of glioblastoma and head and neck squamous cell carcinoma is extremely uncommon. This case emphasizes that newly detected intracranial lesions in patients with systemic malignancies should not automatically be considered metastases. Histopathological confirmation remains essential whenever imaging findings are atypical, as the diagnosis directly influences prognosis and therapeutic strategy. A multidisciplinary approach involving neurosurgeons, neuroradiologists, neuropathologists, and oncologists is crucial for optimal patient management.

Conclusion: This rare association highlights the importance of maintaining a broad differential diagnosis when evaluating intracranial lesions in patients with extracranial cancer. Tissue diagnosis remains the gold standard for distinguishing glioblastoma from metastatic disease and is fundamental for selecting appropriate treatment and improving clinical decision-making.

P254 - Synchronous third ventricular ependymoma and vermian astrocytoma in an adult: a case report of sequential stereotactic biopsies and multimodal treatment

Dergham Djamel Eddine, T. Selmane, A.Chabat, K.Bouaita

Department of neurosurgery, neurosurgery hospital Cherchall, Algeria

Background: Synchronous primary intracranial tumors are rare and may create major diagnostic and therapeutic challenges, especially when they arise in different neuroanatomical locations and show distinct histologies. We report an unusual adult case of a third ventricular lesion diagnosed as WHO grade 3 ependymoma and a separate vermian astrocytic tumor.

Methods: The patient underwent stereotactic biopsy of the third ventricular (V3) lesion, which confirmed ependymoma, WHO grade 3. In view of the tumor location and grade, adjuvant radiotherapy was planned. During follow-up, a new cerebellar vermian lesion appeared, raising suspicion for a second primary neoplasm rather than simple progression. Stereotactic biopsy of the vermian lesion was then performed, showing astrocytoma with high-grade features. Multidisciplinary review led to referral for combined radiotherapy and chemotherapy.

Results: Histopathological analysis confirmed two anatomically distinct primary brain tumors with different biological behavior. The V3 lesion was consistent with grade 3 ependymoma, while the vermian lesion was compatible with astrocytoma, likely grade 3 or 4. The coexistence of these lesions significantly influenced treatment planning, requiring sequential biopsy, reassessment of imaging evolution, and adaptation of the oncological strategy.

Conclusions: This case highlights the importance of tissue diagnosis when new intracranial lesions appear during follow-up, even in patients with an established brain tumor. Synchronous primary tumors should be considered in the differential diagnosis to avoid misclassification as recurrence or dissemination. A multidisciplinary approach is essential to guide individualized management in rare dual-histology intracranial tumors.

P255 - Syndromic versus non-syndromic craniosynostosis: when the skull is only the beginning

Kais Bouzouita, Rachdi M.A., Kammoun T, Yedeas MD, Achoura S, Chkili Ridha, Radhouen K.

Neurosurgery Department, Military Hospital of Tunis, Tunis, Tunisia

Background & objectives: Craniosynostosis encompasses a clinically and genetically heterogeneous spectrum ranging from isolated single-suture fusion with predominantly cosmetic implications to complex syndromic forms involving multiple sutures, midface hypoplasia, airway compromise, and multiorgan involvement. This fundamental distinction — syndromic versus non-syndromic — dictates profoundly different surgical strategies, timing, team compositions, and long-term management pathways. Yet the boundary between both categories is increasingly blurred by expanding genetic characterization of apparently isolated cases. This review critically examines the surgical implications of syndromic versus non-syndromic craniosynostosis classification.

Methods: Narrative review of PubMed, Scopus, and Cochrane databases (2005–2024), including surgical outcome series, genetic characterization studies, and multidisciplinary management guidelines addressing syndromic and non-syndromic craniosynostosis across major syndrome categories (Apert, Crouzon, Pfeiffer, Muenke, Saethre-Chotzen).

Results & discussion: Non-syndromic craniosynostosis: Isolated single-suture fusion — sagittal, metopic, unicoronal, or lambdoid — typically presents without associated anomalies, permits early definitive correction via endoscopic or open vault remodeling, and carries favorable neurodevelopmental prognosis following timely surgical intervention before 12 months. Syndromic craniosynostosis: Multisuture fusion in Apert, Crouzon, and Pfeiffer syndromes demands staged, multidisciplinary surgical planning integrating cranial vault expansion, midface advancement, and airway management across multiple procedures spanning childhood and adolescence. Intracranial hypertension prevalence reaches 40–60% in syndromic cases, necessitating systematic ophthalmological and ICP monitoring beyond morphological assessment. Genetic implications: FGFR2, FGFR3, TWIST1, and ERF mutations increasingly identify patients requiring genetic counseling, recurrence risk assessment, and surveillance for associated cardiac, limb, and visceral anomalies modifying surgical and anesthetic planning. Surgical complexity gradient: Operating time, blood loss, transfusion requirements, intensive care duration, and reoperation rates scale proportionally with syndromic complexity, mandating centralization of syndromic cases in high-volume craniofacial centers with dedicated multidisciplinary teams.

Conclusion: Syndromic craniosynostosis is not simply a more complex version of isolated suture fusion — it is a fundamentally different disease requiring lifelong multidisciplinary management. Accurate early genetic and phenotypic classification is the cornerstone of appropriate surgical planning and family counseling.

P256 - Tapping into prediction: CSF biomarkers as predictors of shunt response in normal pressure hydrocephalus

Ameur Affes, Akrout F, Rachdi M.A., Kammoun T, Bouzouita K, Achoura S, Chkili Ridha, Radhouen K.

Neurosurgery Department, Military Hospital of Tunis, Tunis, Tunisia

Background & objectives: Normal pressure hydrocephalus remains one of the few reversible causes of dementia, yet patient selection for ventriculoperitoneal shunting continues to rely predominantly on clinical and radiological criteria with imperfect predictive accuracy. CSF biomarkers — reflecting neurodegeneration, neuroinflammation, and white matter integrity — have emerged as promising adjunctive predictors of shunt responsiveness, potentially identifying patients most likely to benefit from surgical diversion and those whose cognitive impairment reflects underlying irreversible neurodegeneration. This review critically examines current evidence on CSF biomarkers as predictors of shunt response in normal pressure hydrocephalus.

Methods: Narrative review of PubMed, Scopus, and Cochrane databases (2010–2024), including prospective biomarker studies, shunt outcome analyses, and diagnostic accuracy reports evaluating CSF protein profiles in NPH patient cohorts.

Results & discussion: Amyloid and tau: Low CSF Aβ42 and elevated phosphorylated tau, classically associated with Alzheimer's disease co-pathology, are consistently associated with inferior shunt response, suggesting that amyloid burden identifies patients whose cognitive impairment will persist despite successful CSF diversion. However, overlap with pure NPH profiles limits individual predictive precision. Neurofilament light chain: Elevated CSF neurofilament light chain (NFL), a marker of axonal injury and neurodegeneration, correlates with poor shunt response and rapid post-shunt cognitive decline, potentially identifying patients with advanced irreversible white matter damage unlikely to benefit from diversion. Inflammatory markers: Elevated CSF interleukin-6 and MCP-1 levels have been associated with favorable shunt response in preliminary series, suggesting that neuroinflammatory rather than neurodegenerative predominance predicts reversibility — a mechanistically plausible but insufficiently validated observation. Tap test integration: Clinical improvement following large-volume lumbar puncture remains the strongest single predictor of shunt response; biomarker profiles add independent predictive value when tap test results are equivocal.

Conclusion: CSF biomarkers, particularly NFL and amyloid-tau profiles, provide meaningful adjunctive prediction of shunt response in NPH, identifying patients whose impairment reflects irreversible neurodegeneration rather than reversible CSF dynamics. Integration into standardized selection protocols alongside tap test and clinical criteria is warranted.

P257 - Tarlov cysts: when should surgery be considered? a retrospective single-center experience

Mohamed Amine Hmida, R.Benfredj, A.Mribah, C.Abdelileh, I.Ksira

Department of Neurosurgery, Sahloul Hospital, Sousse, Tunisia

Introduction: Tarlov cysts, also known as sacral perineural cysts, are cerebrospinal fluid-filled lesions typically discovered incidentally during spinal imaging. Although most remain asymptomatic, some patients may develop lumbosacral pain, radiculopathy, sensory disturbances, or sphincter dysfunction. The optimal management of symptomatic Tarlov cysts, particularly the indications for surgical intervention, remains controversial.

Objective: To identify the criteria supporting surgical intervention in patients with Tarlov cysts based on our institutional experience.

Materials and methods: A retrospective study was conducted between 2022 and 2025, including 38 patients diagnosed with Tarlov cysts. Clinical presentation, radiological characteristics, treatment strategy (conservative or surgical), and clinical outcomes were analyzed. Surgical indications were assessed according to symptom severity, clinico-radiological correlation, and response to conservative management.

Results: Among the 38 patients, 15 (39.5%) were symptomatic. Surgical treatment was performed in 9 patients. Overall clinical improvement was observed in 10 patients, including 3 who underwent surgery. Stable clinical status was noted in 10 patients, including 4 operated patients. Postoperative complications occurred in 2 surgically treated patients.

Discussion: Our findings confirm that only a minority of patients with Tarlov cysts become symptomatic. Although surgery may be considered in selected cases, clinical improvement is not systematic and must be weighed against the risk of postoperative complications. Careful patient selection remains essential and should rely on a strong clinico-radiological correlation, disabling symptoms, and failure of conservative treatment. The decision to operate should be individualized, taking into account both symptom burden and expected surgical benefit.

Conclusion: Management of Tarlov cysts should be tailored to each patient. Surgical treatment should be reserved for severe symptomatic cases with clear radiological correlation and persistent symptoms despite conservative management. Given the retrospective design and limited sample size of this study, larger multicenter studies are needed to better define evidence-based surgical indications, particularly in developing healthcare settings such as Tunisia.

P258 - Temporal gliosarcoma masquerading as herpes simplex encephalitis: a diagnostic pitfall

Aziz Ben Kheder, Kais Maamri, Mehdi Darmoul

Neurosurgery Department, Fattouma Bourguiba University hospital, Monastir, Tunisia.

Introduction: Gliosarcoma is a rare IDH-wildtype glioblastoma variant (WHO grade 4) defined by a biphasic glial and mesenchymal/sarcomatous architecture, with a predilection for the temporal lobe. Its presentation may exceptionally mimic infectious encephalitis, leading to a substantial diagnostic delay.

Case report: A 67-year-old man with no relevant medical history presented with a first generalized tonic-clonic seizure, followed within hours by acute speech difficulty and fever. Initial brain CT was normal. MRI revealed bilateral temporal, insular and temporo-occipital T2/FLAIR hyperintensities, predominantly left-sided, without contrast enhancement or diffusion restriction. CSF analysis showed mild hypoglycorrhachia and mildly elevated protein without pleocytosis. The clinico-radiological picture was attributed to herpes simplex encephalitis, and the patient completed 14 days of aciclovir with transient clinical improvement. The course was complicated by a focal seizure with Todd's paralysis, while an extensive workup—including a negative CSF HSV PCR and autoimmune/paraneoplastic antibody panels—remained unrevealing. Six months later, he was readmitted for recurrent seizures and a new left third-nerve palsy (ptosis and mydriasis). Repeat MRI demonstrated a nodular left temporo-medial and occipital lesion suggestive of a glial tumor. A left temporal craniotomy with anterior temporal lobectomy and biopsy was performed. Histology showed a GFAP-positive cellular glial proliferation with pseudopalisading necrosis, microvascular proliferation and numerous mitoses, together with a spindle-cell sarcomatous component accounting for approximately 40% of the tumor volume, consistent with gliosarcoma (WHO grade 4).

Conclusion: A temporal, non-enhancing, bilateral lesion associated with fever, seizures and mild CSF abnormalities is a recognized mimic of herpetic encephalitis but may conceal an infiltrative high-grade glioma. Failure of clinical and radiological resolution, a negative HSV PCR, progressive focal deficits and an evolving mass on follow-up imaging should prompt early diagnostic reconsideration and histological confirmation. Systematic MRI re-evaluation and a low threshold for stereotactic or open biopsy are essential to avoid a costly diagnostic delay.

P259 - Tethered cord syndrome in children: a 5-year single-center surgical experience

Soumia Benallag, A. Meliani, A. Mati, T.Selmane, K.Bouaita

Neurosurgery departement EHS Cherchell, Blida faculty of medecine, Algeria.

Background: Tethered cord syndrome (TCS) is a progressive neurological disorder resulting from abnormal fixation of the spinal cord. Surgical sectioning of the filum terminale is the standard treatment, although retethering remains a recognized long-term complication. This study evaluates surgical outcomes and measures aimed at preventing retethering.

Methods: We retrospectively reviewed 15 patients treated surgically for TCS between January 2018 and December 2022. All patients underwent preoperative spinal MRI and cystomanometry. Surgery consisted of microsurgical sectioning of the filum terminale through an L4 laminectomy. Preventive measures against retethering included meticulous microsurgical dissection, preservation of arachnoid planes, minimal neural manipulation, filum coagulation and sectioning, and watertight dural closure.

Results: Patients ranged from 3 to 16 years of age, with one adult patient aged 33 years. The male to female ratio was 2.75:1. Sphincter dysfunction and orthopedic deformities were the most common presenting symptoms. MRI confirmed a low-lying conus and pathological filum in all cases. Associated anomalies included one myelomeningocele and one case of diastematomyelia with dermal sinus. No postoperative neurological deterioration occurred. One patient developed a CSF fistula complicated by meningitis requiring surgical revision and antibiotic therapy. After a mean follow-up of 12 months, neurological and urological symptoms improved or stabilized in most patients, and no cases of symptomatic retethering were observed.

Conclusion: Filum terminale sectioning is a safe and effective treatment for TCS. Careful microsurgical technique and watertight dural closure may contribute to reducing the risk of retethering. Long-term follow-up remains essential for detecting delayed recurrence.

P260 - The bladder as a last resort: ventriculo-vesical shunting for refractory hydrocephalus — a case report and technical note

Firas Gahbiche, F. Sliti, A. Oueslati, A. Belhadj, N. Nessib, A. Slimane, K. Ghedira, K. Abdelrahmen, S. Bouali, I. Ben Said, J. Kallel

Department of Neurosurgery, National Institute of Neurology Mongi Ben Hmida, Tunis, Tunisia

Background: The ventriculo-peritoneal shunt (VPS) remains the first-line treatment for hydrocephalus, with the ventriculo-atrial (VA) shunt as the standard alternative. When both sites are unavailable, surgeons are confronted with a genuine therapeutic challenge. The ventriculo-vesical shunt (VVS) — in which cerebrospinal fluid (CSF) is drained into the urinary bladder — is an exceptionally rare technique, documented in only a handful of cases in the world literature. We present the case of a 14-year-old boy in whom a VVS was successfully implanted following exhaustion of all conventional shunting options, and discuss the surgical technique illustrated with intraoperative images.

Case report: A 14-year-old male was diagnosed in 2018 with a left parieto-occipital WHO Grade II ependymoma. In 2024, he re-presented with raised intracranial pressure due to intraventricular grade III tumor recurrence and underwent surgical resection which was complicated by hydrocephalus, managed with a VPS, followed by adjuvant radiotherapy. He subsequently experienced multiple episodes of peritoneal valve dysfunction requiring conversion to a VA shunt in 2025, which was complicated by bacterial meningitis necessitating external ventricular drainage. TAP CT revealed peritoneal carcinomatosis of suspected secondary origin, permanently contraindicating further peritoneal CSF diversion. Following multidisciplinary discussion with the urological surgery team, a VVS was implanted without intraoperative complications. Immediate postoperative clinical improvement was noted.

Discussion: The VVS exploits the urinary bladder as a CSF reservoir, with natural drainage occurring via micturition. Its main advantage is the complete bypass of both the peritoneal and cardiovascular systems, making it uniquely suited to oncological contexts with peritoneal involvement. Surgical success depends on adequate bladder capacity, normal renal function, and a watertight vesical anastomosis — points illustrated in our intraoperative images. The extreme rarity of this technique, combined with the absence of long-term follow-up data in the literature, means that its durability, complication profile, and impact on urinary function remain incompletely understood. Our case adds to the very limited body of evidence supporting its feasibility in carefully selected pediatric patients.

Conclusion: The ventriculo-vesical shunt is a viable last-resort option when peritoneal and atrial drainage are both contraindicated. This case — one of very few reported in the pediatric population — demonstrates its technical feasibility and immediate clinical benefit. The loss to follow-up underscores a recurrent challenge in complex oncological cases and highlights the need for robust multidisciplinary follow-up protocols. Greater awareness of the VVS technique may help neurosurgeons navigate the most refractory CSF diversion scenarios.

P261 - The bleeding brain and the clotting dilemma: when and how to resume anticoagulation after traumatic intracranial hemorrhage

Ameur Affes, Bouzouita K, Rachdi M.A., Kammoun T, Yedeas MD, Achoura S, Chkili Ridha, Radhouen K.

Neurosurgery Department, Military Hospital of Tunis, Tunis, Tunisia

Background & objectives: Resuming anticoagulation after traumatic intracranial hemorrhage (tICH) represents one of the most consequential and poorly standardized decisions in neurosurgical practice. Premature resumption risks hemorrhagic expansion or rebleeding; excessive delay exposes patients to thromboembolic events — stroke, pulmonary embolism, prosthetic valve thrombosis — with potentially equal or greater lethality. No universal consensus currently guides this decision. This review critically appraises existing evidence to define optimal anticoagulation resumption timing and strategy after tICH.

Methods: Narrative review of PubMed, Scopus, and Cochrane databases (2010–2024), including retrospective cohort studies, systematic reviews, and society guidelines addressing anticoagulation resumption timing, hemorrhage stability criteria, and thromboembolic risk stratification after traumatic intracranial hemorrhage.

Results & discussion: Hemorrhagic stability assessment: Serial CT imaging confirming hematoma stability over 24–48 hours constitutes the prerequisite before any resumption consideration. Hemorrhage volume, location, mechanism, and underlying coagulopathy correction are critical determinants of stability definition. Resumption timing: Current evidence, predominantly retrospective, suggests a resumption window of 4–8 weeks for most tICH etiologies, balancing rebleeding risk against thromboembolic exposure. High-thromboembolic-risk indications — mechanical cardiac valves, recent deep vein thrombosis, atrial fibrillation with CHA_2DS_2-VASc ≥ 4 — may justify earlier resumption at 2–4 weeks under neurosurgical and hematological co-supervision. Anticoagulant class considerations: Direct oral anticoagulants demonstrate more favorable intracranial safety profiles than vitamin K antagonists in resumption series, supporting their preference when clinically appropriate. Bridging anticoagulation with heparin carries unacceptable rebleeding risk and is not recommended. Multidisciplinary decision-making: Neurosurgical, neurological, cardiological, and hematological input is mandatory, integrating hemorrhage characteristics, thromboembolic indication urgency, and patient functional status into a shared individualized decision.

Conclusion: Anticoagulation resumption after tICH demands individualized, multidisciplinary timing decisions rather than uniform protocols. A structured risk-stratification framework integrating hemorrhagic stability, thromboembolic urgency, and anticoagulant class guides optimal management in this high-stakes clinical dilemma.

P262 - The clinical superiority of lateral position variations in the surgical management of giant petroclival meningiomas

Nasreddine Baz, Chabat.A, Boudjadja.B, Dergham.D, Benallag.S, Bouaita.K

Department of Neurosurgery, EHS Cherchell, Algeria

Background: Petroclival meningiomas represent a major surgical challenge because of their intimate anatomical relationship with the brainstem and critical neurovascular structures. Patient positioning significantly influences the surgical corridor, intraoperative hemodynamic stability, and postoperative complication rates.

Methods: A retrospective analysis was conducted on 9 patients operated on for giant petroclival meningiomas at the Specialized Neurosurgery Hospital of Cherchell between 2022 and 2026. All tumors underwent deliberate partial removal (subtotal resection) to decompress the brainstem and cranial nerves. We analyzed intraoperative and postoperative outcomes according to surgical positioning: lateral decubitus (n=5), semi-sitting position (n=3), and prone decubitus (extreme lateral variant) (n=1).

Results: The lateral decubitus position showed superior intraoperative and postoperative profiles. In contrast, the semi-sitting position was associated with severe cardiopulmonary complications, including a massive postoperative pulmonary embolism (n=1) leading to death two days after surgery. Because of the massive tumor volumes and the manipulation required for the lower cranial nerves, a high tracheostomy rate (n=5) was observed across the cohort to manage the expected postoperative bulbar dysfunction. A late death occurred two years after surgery, secondary to status epilepticus.

Conclusion: For the resection of giant petroclival meningiomas, modern neurosurgical practice strongly favors maximum safe resection rather than radical excision. When performing these function-preserving resections, the lateral decubitus position offers an optimal balance between gravity-assisted surgical exposure and superior hemodynamic safety compared with the semi-sitting position.

P263 - The diagnostic conundrum and therapeutic challenge of spinal hydatid disease: lessons from a referral of failed initial management.

Riadh Rebai, Bassam Addas

King Fahd hospital, Second health cluster, Jeddah; KSA

We present a challenging case of recurrent thoracic spinal hydatid cysts who has been treated initially elsewhere. We highlight to core dilemmas: 1st, the diagnostic challenge, where the condition masquerades as more common spinal pathologies, often leading to misinterpretations of imaging and false negative serology, delaying definitive diagnosis. Second, the management paradox encountered in the resource limited settings: Without the intent and capability for radical resection during the initial procedure, surgery becomes a source of iatrogenic dissemination. Our subsequent multidisciplinary intervention involved radical debridement, medical removal of daughter cyst, instrumentation of the spine with a special tip to avoid an aggressive prolonged surgery and sustained Albendazole therapy. Our case underscores that the surgical intervention is the most critical determinate of outcome. It argues for heightened suspicion in endemic regions, a paradigm shift towards aggressive, radical resection at 1st presentation, and the necessity of a specialized, multidisciplinary approach to prevent the devastating cycle of recurrence and permanent neurological deficit.

P264 - The dilemma of calcified lumbar disc herniation: indirect decompression or disc excision?

Houssem Hdhili, K.Bouzouita, B.Shil, F.Akrout, S.Achoura, A.Harbaoui, R.Chkili, M.D.Yedeas, K.Radhouane

Department of Neurosurgery, Military Hospital of Tunis, Tunisia

Background: Calcified lumbar disc herniations are uncommon and represent a surgical challenge because of their firm consistency and frequent adherence to neural structures. The optimal management remains controversial, ranging from indirect neural decompression without fragment removal to direct disc excision.

Methods: Two patients with symptomatic calcified lumbar disc herniation refractory to conservative treatment underwent surgery at the Military Hospital of Tunis. Clinical presentation, imaging findings, surgical management, and postoperative outcomes were retrospectively reviewed.

Results: The first patient presented with severe radiculopathy caused by a calcified foraminal disc herniation. Owing to the anticipated risk of neural injury, indirect decompression through laminectomy and foraminotomy without fragment removal was performed. The second patient had a centrally calcified disc causing marked canal stenosis and underwent direct discectomy with complete excision of the calcified fragment. Both patients experienced immediate pain relief, with no neurological worsening or perioperative complications. Functional outcomes were favorable at follow-up, and no recurrence was observed.

Discussion: The management of calcified lumbar disc herniations remains controversial because the hardness of the lesion and its adhesion to the dura increase the risk of cerebrospinal fluid leakage and nerve root injury during discectomy. While complete fragment removal is traditionally advocated, recent experience suggests that adequate neural decompression alone may provide satisfactory symptom control in selected patients. The surgical strategy should therefore be individualized according to disc location, degree of compression, and technical feasibility.

Conclusion: Calcified lumbar disc herniations require tailored surgical management. Indirect decompression may represent a safe and effective alternative to disc excision in selected cases, whereas direct removal remains indicated when persistent neural compression is present.

P265 - The far-lateral transcondylar approach for anterior foramen magnum meningiomas: surgical exposure, technical considerations, and clinical outcome : a technical case report

Houssem Hdhili, K.Bouzouita, S. Farhat, E. Chahed, S.Achoura, A.Harbaoui, R.Chkili, M.D.Yedeas, K.Radhouane

Department of Neurosurgery, Military Hospital of Tunis, Tunisia

Background: Anterior foramen magnum meningiomas (FMMs) remain among the most challenging skull base tumors because of their intimate relationship with the lower cranial nerves, vertebral artery, and cervicomedullary junction. Although several surgical corridors have been described, the far-lateral transcondylar approach offers direct access to ventrally located lesions while minimizing brainstem manipulation. We report the surgical management of a symptomatic anterior FMM, emphasizing operative strategy, technical pearls, and postoperative outcome.

Case description: A 72-year-old woman with a history of hypertension presented with progressive dysphagia that culminated in aspiration pneumonia requiring endotracheal intubation followed by tracheostomy. Neurological examination demonstrated lower cranial nerve dysfunction without long-tract deficits. Magnetic resonance imaging revealed a well-circumscribed, homogeneously enhancing anterior foramen magnum meningioma causing severe ventral compression of the medulla and displacement of the vertebral arteries. Following multidisciplinary evaluation, tumor resection was performed through a far-lateral transcondylar approach. The vertebral artery was identified and mobilized extradurally, allowing safe dural opening and early tumor devascularization. Limited drilling of the occipital condyle widened the surgical corridor, permitting microsurgical internal debulking followed by circumferential arachnoid dissection and preservation of the lower cranial nerves, posterior inferior cerebellar artery, and vertebral artery. Gross-total resection (Simpson grade II) was achieved without intraoperative neurovascular injury or postoperative craniocervical instability.

Results: The postoperative course was uneventful. Imaging confirmed complete decompression of the cervicomedullary junction with no residual tumor. Swallowing function progressively improved, enabling successful decannulation and oral feeding during rehabilitation. At six-month follow-up, the patient remained neurologically stable with no radiological evidence of recurrence.

Conclusion: The far-lateral transcondylar approach provides a safe and effective route for anterior foramen magnum meningiomas by offering direct ventrolateral exposure, minimizing brainstem retraction, and facilitating meticulous neurovascular dissection. Careful preoperative planning, vertebral artery control, judicious condylar drilling, and preservation of lower cranial nerves are critical determinants of favorable surgical outcomes.

P266 - The forgotten spine: management principles of gunshot-induced spinal cord injury

Maryem Khayat, Bouzouita K, Rachdi M.A., Kammoun T, Achoura S, Chkili Ridha, Radhouen K.

Neurosurgery Department, Military Hospital of Tunis, Tunis, Tunisia

Background & objectives: Gunshot-induced spinal cord injury, though less extensively studied than its craniocerebral counterpart, carries devastating neurological consequences and presents distinct management challenges. Unlike blunt spinal trauma, ballistic spinal injury raises specific questions regarding bullet and fragment removal, decompression timing, instability assessment, and infection prophylaxis — areas where consensus remains notably underdeveloped. This review synthesizes current evidence to clarify management principles for gunshot-induced spinal cord injury.

Methods: Narrative review of PubMed, Scopus, and Cochrane databases (2000–2024), including civilian and military case series, comparative cohort studies, and trauma society guidelines addressing neurological assessment, surgical indications, bullet extraction, and infectious management in ballistic spinal trauma.

Results & discussion: Neurological assessment: Standardized ASIA grading at admission remains the strongest predictor of neurological recovery, with complete injuries showing minimal potential for meaningful improvement regardless of surgical intervention, informing realistic prognostic counseling. Surgical decompression: Unlike blunt spinal trauma, mechanical instability is uncommon in ballistic injury, as bony architecture is frequently preserved despite canal violation. Surgical decompression is primarily indicated for incomplete injuries with radiologically confirmed canal compromise by retained fragments or bone, rather than as routine practice. Bullet and fragment removal: Retained intracanalicular bullets in incomplete injuries with progressive neurological deterioration warrant removal; however, in complete, stable, neurologically static injuries, fragment retrieval offers no proven neurological benefit and carries additional surgical risk, favoring conservative management. Spinal stability: Formal instrumentation and fusion are reserved for cases with confirmed mechanical instability or significant vertebral body destruction, distinguishing ballistic injury management from standard blunt trauma protocols. Infection prophylaxis: Broad-spectrum antibiotic coverage is recommended given transcolonic or transthoracic bullet trajectories, with extended prophylaxis duration in cases of bowel or visceral involvement.

Conclusion: Gunshot-induced spinal cord injury demands a distinct management paradigm from blunt trauma, prioritizing neurological status over bony instability, with selective rather than routine surgical and fragment removal indications guiding optimal outcomes.

P267 - The good, the bad and the ugly: cognitive impairment after multimodal treatment for high-grade glioma

Ahmed Amine Daoued, M.M. Hadhri[1], G. Elkkhla[1], M. Ghorbel[1], M.A. Hadjtaieb [1], A. Falfoul [2], M. Darmoul[1].

[1] Neurosurgery Departement, Fattouma Bourguiba University Hospital of Monastir, Tunisia
[2] Radiotherapy Departement, Omrane Hospital of Monastir, Tunisia

Background: High-grade gliomas require aggressive multimodal treatment combining surgery, chemotherapy, and radiotherapy. While this approach improves tumor control and survival, it may be associated with neurological and cognitive sequelae. Cognitive impairment after treatment remains challenging to interpret, as it may result from the tumor itself, surgical injury, chemotherapy-related neurotoxicity, radiation-induced damage, or disease progression.

Methods: We report the case of a patient treated for high-grade glioma with surgical resection followed by chemotherapy and radiotherapy, who subsequently developed cognitive impairment. Clinical evolution, treatment history, neurocognitive symptoms, and radiological findings were analyzed in order to identify the most likely contributing factor.

Results: The patient presented with progressive cognitive decline following completion of multimodal therapy. Although surgery and chemotherapy may contribute to cognitive dysfunction, the delayed and progressive nature of the impairment suggested radiotherapy as the most probable causative factor. Radiation-induced cognitive decline is thought to result from white matter injury, vascular changes, inflammation, and damage to neural progenitor cells, particularly when eloquent or memory-related brain regions are exposed. Nevertheless, tumor progression and treatment-related edema must always be excluded before attributing symptoms solely to radiotherapy.

Conclusions: Cognitive impairment after treatment for high-grade glioma is rarely explained by a single mechanism. In this case, radiotherapy appears to be the most probable contributor, while surgery, chemotherapy, tumor biology, and recurrence remain important differential factors. This case highlights the need for baseline and follow-up neurocognitive assessment in glioma patients, as well as careful interpretation of cognitive decline after multimodal treatment.

P268 - The molecular era of neuro-oncology: redefining CNS tumors

Houssem Hdhili, F.Akrout, K.Bouzouita, A.Affes, S.Achoura, A.Harbaoui, R.Chkili, M.D.Yedeas, K.Radhouane

Department of Neurosurgery, Military Hospital of Tunis, Tunisia

Background: Recent advances in molecular biology have revolutionized the classification of central nervous system (CNS) tumors. The fifth edition of the World Health Organization (WHO) classification introduced a paradigm shift from morphology-based diagnoses toward integrated histomolecular entities, with important implications for prognosis and therapeutic decision-making.

Methods: A narrative review of the recent literature and WHO 2021 classification was performed, focusing on the molecular markers that have transformed the diagnosis and grading of adult and pediatric CNS tumors.

Results: Molecular alterations have become essential components of tumor classification. In diffuse gliomas, IDH mutation and 1p/19q codeletion define oligodendrogliomas, while CDKN2A/B homozygous deletion influences grading. In pediatric diffuse gliomas, H3K27-altered and H3G34-mutant tumors constitute distinct entities with specific prognostic implications. Likewise, molecular profiling has reshaped the classification of ependymomas, medulloblastomas, meningiomas, and embryonal tumors. DNA methylation profiling and next-generation sequencing have further improved diagnostic accuracy, allowing the identification of previously unrecognized entities and refining risk stratification. These advances have facilitated the development of targeted therapies and personalized treatment strategies.

Conclusion: Molecular biology has transformed the classification of CNS tumors from a purely morphological framework to an integrated diagnostic model. This evolution represents a cornerstone of precision neuro-oncology and is reshaping the prognostic assessment and therapeutic management of patients with CNS neoplasms.

P269 - The MRI doesn't operate, the surgeon does: rethinking patient selection in spinal surgery

Ameur Affes, Rachdi M.A., Hdhili H, Bouzouita K, Achoura S, Chkili Ridha, Radhouen K.

Neurosurgery Department, Military Hospital of Tunis, Tunis, Tunisia

Background & objectives: Spinal surgery indications are frequently anchored to imaging findings, yet a substantial body of evidence demonstrates poor correlation between radiological abnormalities and clinical symptoms, with degenerative findings present in up to 90% of asymptomatic individuals over 50 years. Operating on the image rather than the patient remains a recognized driver of surgical failure and dissatisfaction. This review examines the clinical, psychosocial, and patient-centered determinants that should guide neurosurgical decision-making beyond radiological findings alone.

Methods: Narrative review of PubMed, Scopus, and Cochrane databases (2010–2024), including studies on clinico-radiological correlation, predictors of surgical outcome, psychosocial risk factors, and shared decision-making frameworks in elective spinal surgery.

Results & discussion: Clinico-radiological correlation: Symptom severity, functional disability, and neurological deficit must take precedence over imaging abnormality magnitude. Concordance between symptom distribution and anatomical findings, rather than imaging severity alone, remains the strongest predictor of surgical benefit. Psychosocial determinants: Depression, anxiety, pain catastrophizing, and unresolved litigation or compensation claims are consistently associated with poorer postoperative outcomes, independent of surgical technique quality, and warrant systematic preoperative screening. Patient expectations and shared decision-making: Misaligned expectations between anticipated and realistic postoperative outcomes correlate strongly with dissatisfaction even after technically successful surgery. Structured preoperative counseling and shared decision-making tools significantly improve outcome concordance and patient-reported satisfaction. Frailty and functional reserve: Beyond chronological age, functional status, sarcopenia, and frailty indices increasingly guide candidacy assessment, particularly in elderly populations where surgical risk-benefit calculus extends beyond radiological severity. Toward integrated selection models: Emerging frameworks combining clinical examination, validated psychosocial screening tools, and patient-reported outcome measures alongside imaging are proposed to standardize and improve selection accuracy.

Conclusion: Optimal patient selection in spinal surgery requires deliberately moving beyond imaging-driven indications toward an integrated clinical, psychosocial, and patient-centered framework. The image informs the diagnosis — but only comprehensive clinical judgment should inform the decision to operate.

P270 - The role of full-endoscopic transforaminal discectomy in calcified T11–T12 thoracic disc herniation

Talel Kamoun, MD. Yedeas, K. Bouzouita, H. Hdhili, A. Affes, R. Chkili, K. Radhouane.

Department of Neurosurgery, Military Hospital of Tunis, Tunisia

Background: Thoracic disc herniations (TDHs) are rare, accounting for less than 1% of all operated disc herniations. The T11–T12 segment (thoracolumbar junction) is the most frequently affected due to its transitional biomechanical configuration, which combines the rigidity of the thoracic spine with the high mobility of the lumbar spine.

Case presentation: We report the case of a 54-year-old male patient who presented with a progressive neurological timeline expanding over several months, combining bilateral lower limb heaviness, bilateral lumbar sciatica refractory to tier 1 and 2 analgesics, and intermittent genitosphincteric claudication, initially mimicking lower root involvement. Neurological examination revealed diffusely decreased deep tendon reflexes in the lower extremities and a right unilateral Babinski sign, indicating subtle spinal cord compression. Spinal MRI demonstrated a large, left paramedian T11–T12 disc herniation causing severe cord conflict, and CT confirmed partial calcification. The patient underwent full-endoscopic transforaminal discectomy via a left T11–T12 approach. This working channel allowed direct access to the herniation without spinal cord retraction. Under continuous high-definition visual control, the herniated portion and its calcified component were meticulously resected, achieving complete canal and foraminal decompression. The postoperative course was uneventful; the patient experienced immediate radicular pain relief, ambulated early, and was discharged on postoperative day 1 with excellent functional recovery.

Conclusion: Thoracic disc herniations at the thoracolumbar junction can deceptively mimic a cauda equina pathology. A rigorous clinical examination looking for a subtle pyramidal syndrome is crucial to guide imaging. For complex calcified forms, full-endoscopic transforaminal discectomy represents an excellent surgical alternative, combining maximum neurological safety with a drastic reduction in postoperative morbidity.

P271 - The silent threat detected: can artificial intelligence revolutionize vasospasm surveillance after subarachnoid hemorrhage?

Maryem Khayat, Rachdi MA, Akrout F, Kammoun T, Bouzouita K, Chkili R, Radhouen K

Neurosurgery Department, Military Hospital of Tunis, Tunis, Tunisia

Background & objectives: Cerebral vasospasm remains the leading cause of delayed neurological deterioration after aneurysmal subarachnoid hemorrhage (aSAH), affecting 30–70% of patients and contributing disproportionately to morbidity and mortality despite optimal aneurysm securing. Current surveillance relies on transcranial Doppler, CT angiography, and digital subtraction angiography — modalities constrained by operator dependency, intermittent acquisition, and delayed detection. Artificial intelligence (AI), through automated signal processing, deep learning, and multimodal data integration, offers a paradigm shift toward continuous, objective, early vasospasm detection. This review critically appraises current evidence on AI-based vasospasm assessment after aSAH and evaluates its potential for clinical translation.

Methods: Narrative review of PubMed, Scopus, and IEEE Xplore databases (2010–2024), encompassing machine learning models, convolutional neural networks, natural language processing tools, and AI-augmented multimodal monitoring studies applied to post-aSAH vasospasm detection and prediction.

Results & discussion: AI-augmented TCD: Automated TCD waveform analysis using recurrent neural networks and signal processing algorithms demonstrates reliable detection of velocity elevation patterns predictive of vasospasm, reducing operator dependency and enabling continuous bedside monitoring. CT angiography and perfusion: Deep learning models applied to CTA and CT perfusion datasets accurately identify vessel caliber reduction and perfusion deficits with AUC values exceeding 0.88, approaching neuroradiologist-level performance with significantly reduced processing time. Multimodal predictive models: Integrating clinical variables (Hunt-Hess grade, Fisher scale, aneurysm location), electrophysiological data, and continuous neuromonitoring parameters into machine learning pipelines yields earlier and more accurate vasospasm prediction than any single modality alone. Current limitations: Dataset heterogeneity, absence of prospective validation, and lack of real-time clinical integration remain significant barriers to bedside implementation.

Conclusion: AI does not merely assist vasospasm surveillance — it fundamentally redefines it. From reactive detection to proactive prediction, intelligent monitoring systems are poised to transform post-aSAH neurocritical care. Prospective multicenter validation is now the field's most urgent priority.

P272 - The weight of pressure: body mass index as a prognostic factor in idiopathic intracranial hypertension

Ahmed Amine Daoued, Y. Ben Brik, R. Ben Dhia, N. Daoussi, M. Mhiri

Department of Neurology, Fattouma Bourguiba University Hospital, Monastir, Tunisia

Background: Idiopathic intracranial hypertension (IIH) is a rare neurological disorder characterized by elevated intracranial pressure without an identifiable cause. It predominantly affects overweight women of childbearing age and is increasingly linked to obesity-related metabolic dysregulation. This study aimed to assess the relationship between body mass index (BMI), at diagnosis and after one year, and the clinical, paraclinical, and therapeutic profile of IIH.

Methods: We conducted a retrospective study over a 20-year period, from 2004 to 2024, in the Neurology Department of Monastir. Eighty patients fulfilling the modified Dandy diagnostic criteria for IIH were included. Clinical presentation, ophthalmological findings, neuroimaging features, opening pressure, treatment modalities, and one-year outcomes were analyzed according to BMI and weight variation.

Results: The study population was predominantly female, representing 90% of cases, with a mean age of 31 years. Mean BMI was 32.31 ± 6.05 kg/m², and excess weight was observed in 92.5% of patients, including 31.3% overweight and 61.2% obese patients. Higher BMI was significantly associated with more severe headaches and visual symptoms, increased opening pressure, more advanced papilledema, and greater visual acuity impairment. Neuroimaging signs of intracranial hypertension, including empty sella, optic nerve sheath dilatation, and posterior globe flattening, were also more frequent in patients with higher BMI. Obesity was associated with more intensive treatment, including higher acetazolamide doses, repeated lumbar punctures, and more frequent surgical management. At one year, weight loss was observed in 58.75% of patients and was associated with significant clinical and paraclinical improvement, whereas weight gain was associated with symptom worsening and disease progression.

Conclusions: BMI appears to be a major prognostic factor in IIH, influencing disease severity, therapeutic requirements, and long-term outcome. Weight control should be considered a central component of multidisciplinary IIH management.

P273 - Therapeutic management of craniopharyngiomas: a single-center experience

Belgacem Ibrahim, Chahad Mbarek, Djouadi Yasmine, Aboudjabel Mohamed, Maamerie Lila, Katia Ait Slimani; Ait Bachir Mustapha

Department of Neurosurgery, CHU Nedir Mohamed, Tizi Ouzou, Algeria

Introduction: Craniopharyngioma is a rare benign embryonic tumor arising from remnants of Rathke's pouch in the sellar and suprasellar region. Despite its benign histology, its proximity to critical neurovascular, visual, and endocrine structures makes management particularly challenging. Compression of the optic pathways may result in visual impairment or blindness, while hypothalamic-pituitary involvement frequently leads to endocrine dysfunction. The aim of this study is to evaluate the therapeutic management and outcomes of patients treated for craniopharyngioma in our department.

Materials and methods: We retrospectively reviewed 20 patients treated for craniopharyngioma between 2018 and 2024. Patients ranged in age from 8 to 30 years, with an equal sex distribution (10 females and 10 males). Clinical presentation included endocrine disorders, particularly hypopituitarism, visual disturbances, and signs of intracranial hypertension. Presenting symptoms varied according to age and included amblyopia and raised intracranial pressure in children, growth retardation or delayed puberty in adolescents, and visual or neurocognitive disturbances in adults.

Results: Subtotal tumor resection was achieved in 7 patients, while partial resection was performed in 8 cases. Five patients underwent stereotactic placement of an intracystic catheter allowing repeated cyst drainage and intracystic therapy with Bleomycin or Yttrium-90. Adjuvant radiotherapy was administered in 2 patients. Three patients who underwent extensive surgical resection experienced significant clinical improvement. Eight patients remained neurologically stable during follow-up, whereas four developed persistent neurological sequelae. Tumor control was achieved in most patients through a multimodal therapeutic strategy combining surgery, intracystic treatment, and radiotherapy when indicated.

Conclusion: The management of craniopharyngiomas remains complex and requires an individualized therapeutic approach. Current strategies include either maximal safe resection with radiotherapy reserved for recurrence or limited surgical decompression followed by early radiotherapy. Treatment decisions should balance tumor control with preservation of neurological, visual, and endocrine functions.

P274 - Therapeutic management of symptomatic postoperative epidural fibrosis after lumbar disc surgery: outcomes analysis and proposal of a graduated six-step algorithm

Khaled Radhouane, K.Bouzouita, S.Farhat, E.Chahed, S.Achoura, A.Harbaoui, R.Chkili, M.D.Yedeas.

Neurosurgery Department, Military Hospital of Tunis, Tunis, Tunisia

Background: Symptomatic postoperative epidural fibrosis (PEF) is a challenging complication of lumbar disc surgery and a major contributor to failed back surgery syndrome (FBSS). Despite multiple available treatment modalities, outcomes remain globally modest and no standardised evidence-based therapeutic algorithm has achieved consensus.

Methods: Retrospective analysis of 48 patients with gadolinium-enhanced MRI-confirmed symptomatic PEF (out of 422 interlaminar discectomies; Military Hospital of Tunis, 2020–2022), graded by ROSS classification. Three sequential modalities were evaluated: medical therapy (analgesics, gabapentin/pregabalin, amitriptyline, physiotherapy), epidural corticosteroid injections, and surgical revision (radicular neurolysis). Treatment success was defined as absent or minimal pain, no analgesic use, preserved professional activity, and patient satisfaction. Correlation between ROSS grade and outcome was assessed by Pearson chi-square test ($p < 0.05$).

Results: All 48 patients received first-line medical therapy; 14/48 (29.2%) achieved meaningful improvement. Eight patients underwent epidural corticosteroid injection without fluoroscopic guidance; only 1/8 (12.5%) improved. Six patients underwent surgical revision; durable benefit was achieved in only 1/6 (16.7%). Five refractory patients were referred to a multidisciplinary pain centre. ROSS Grade 3–4 fibrosis significantly predicted unfavourable outcome (78.1% vs. 37.5%; $p = 0.006$).

Conclusions: PEF treatment yields modest results across all modalities. Medical neuropathic therapy remains first-line. Epidural injections require mandatory image guidance to overcome fibrotic tissue barriers. Surgical revision should be a last resort. Based on these outcomes and current evidence, a graduated six-step algorithm is proposed: pharmacotherapy → image-guided injection → spinal cord stimulation → intrathecal drug delivery → endoscopic adhesiolysis → surgical revision. Prospective studies are needed to validate this framework.

P275 - Thoracic epidural langerhans cell histiocytosis mimicking extramedullary hematopoiesis in β-thalassemia major: a rare cause of spinal cord compression.

Emna Elouni, Sofiene Bouali, Roua Latrach, Amina Oueslati, Salim Bachraoui, Aziz Abdelmoula, Jalel Kallel

Neurosurgery Departement, National Institute of Neurology, Tunis, Tunisia

Background: Extramedullary hematopoiesis (EMH) is a rare complication of β-thalassemia major and an uncommon cause of spinal cord compression. We report an unusual case of spinal epidural Langerhans cell histiocytosis (histiocytosis X) initially suspected to represent EMH.

Methods: A 17-year-old male with transfusion-dependent β-thalassemia major presented with progressive thoracic myelopathy. Magnetic resonance imaging revealed a posterior epidural mass extending from T2 to T10, causing significant spinal cord compression. Based on the patient's hematological history and radiological findings, the lesion was considered highly suggestive of extramedullary hematopoiesis. Owing to neurological deterioration, surgical decompression and excision of the lesion were undertaken.

Results: The patient underwent posterior decompression with gross total resection of the epidural mass. Postoperatively, neurological symptoms improved markedly, with a favorable clinical course. Histopathological examination unexpectedly revealed Langerhans cell histiocytosis (histiocytosis X), thereby excluding the presumed diagnosis of extramedullary hematopoiesis. Follow-up imaging showed complete decompression of the spinal cord without evidence of residual lesion.

Conclusions: Spinal epidural Langerhans cell histiocytosis is an exceedingly rare entity and may mimic extramedullary hematopoiesis in patients with β-thalassemia major. Although clinical and radiological findings may strongly suggest a specific diagnosis, histopathological confirmation remains indispensable. Surgical management provides both effective neurological decompression and definitive diagnosis. This case highlights the importance of considering alternative etiologies of epidural masses in patients with hematological disorders.

P276 - Time is spine: impact of prehospital delay on neurological recovery after subaxial cervical trauma

Mohamed Amine Hmida, K.Maamri, N.Yahyaoui, G.Belkahla, M.Darmoul

Neurosurgery Department, Fattouma Bourguiba University hospital, Monastir, Tunisia.

Introduction: In developing countries, the management of spinal cord injuries is frequently hindered by logistical and structural limitations. Unlike in high-income settings, where the concept of the “Golden Hour” is well established, delays between injury occurrence and admission to specialized centers remain substantial. This critical latency period may adversely affect neurological recovery by prolonging secondary spinal cord ischemia and injury.

Objective: To evaluate the influence of prehospital delay on clinical and neurological outcomes in patients sustaining subaxial cervical spine trauma (C3–C7).

Materials and methods: We conducted an observational study involving 34 patients admitted for subaxial cervical spine trauma. Prehospital delay was defined as the interval between injury occurrence and arrival at a specialized emergency department. Neurological status was assessed using the American Spinal Injury Association (ASIA) Impairment Scale at admission and at the latest follow-up (minimum follow-up of six months). Correlations were analyzed between admission delay, time to surgical decompression, and neurological recovery.

Results: The mean prehospital delay was 8.4 hours, ranging from 2 to 48 hours. A cascade effect was observed, whereby delayed admission was directly associated with prolonged time to surgical intervention. Patients admitted within six hours of injury demonstrated a trend toward superior motor recovery compared with those admitted later. Conversely, prolonged delays were associated with poorer neurological outcomes and lower ASIA grades at follow-up. Although a negative association between delayed admission and neurological recovery was identified, statistical significance was limited by the relatively small sample size (n = 34).

Conclusion: Prehospital delay represents an important yet often overlooked prognostic factor in the management of subaxial cervical spine trauma. Our findings emphasize the need to optimize emergency transport systems, improve awareness of rapid immobilization and transfer protocols among first responders, and develop specialized spinal trauma pathways to reduce treatment delays and maximize neurological recovery

P277 - Too early, too late, or just right? defining the optimal surgical timing in craniosynostosis

Kais Bouzouita, Rachdi M.A., Kammoun T, Yedeas MD, Achoura S, Chkili Ridha, Radhouen K.

Neurosurgery Department, Military Hospital of Tunis, Tunis, Tunisia

Background & objectives: Surgical timing in craniosynostosis management remains one of the most debated questions in pediatric neurosurgery. Operating too early exposes neonates to disproportionate anesthetic and hemorrhagic risk; waiting too long risks irreversible neurodevelopmental consequences from intracranial hypertension and restricted brain growth. The optimal intervention window must balance calvarial plasticity, anesthetic safety, morphological correction potential, and neurodevelopmental protection — competing priorities that vary by suture involved, syndromic status, and surgical technique. This review critically examines current evidence defining optimal surgical timing across craniosynostosis subtypes.

Methods: Narrative review of PubMed, Scopus, and Cochrane databases (2005–2024), including prospective neurodevelopmental outcome studies, morphological correction series, anesthetic risk analyses, and society guidelines addressing surgical timing in both syndromic and non-syndromic craniosynostosis.

Results & discussion: Endoscopic approaches: Strip craniectomy with postoperative helmet orthosis requires intervention before 3–6 months, when calvarial bone retains sufficient plasticity for helmet-directed reshaping. Beyond this window, bone rigidity eliminates the biomechanical prerequisite for orthotic correction, rendering endoscopic technique ineffective and mandating open remodeling. Open vault remodeling: Optimal timing between 6–12 months balances reduced neonatal anesthetic risk, sufficient bone thickness for stable fixation, and preservation of the neurodevelopmental protection window. Intervention before 6 months in open procedures carries significantly elevated transfusion requirements relative to total blood volume in neonates. Neurodevelopmental protection window: Brain volumetric growth is most rapid during the first 12 months, with peak synaptic density and cortical organizational events occurring between 3–9 months. Intracranial hypertension during this critical window produces disproportionate and potentially irreversible neurodevelopmental impact, establishing correction before 12 months as the evidence-based neurodevelopmental threshold. Syndromic cases: Earlier intervention — sometimes before 6 months — is justified by elevated intracranial hypertension prevalence and airway compromise urgency in Apert and Pfeiffer syndromes, accepting higher perioperative risk given greater untreated morbidity. Late presentation: Correction beyond 18–24 months yields inferior morphological outcomes and does not fully reverse established neurodevelopmental deficits, underscoring the critical importance of early diagnosis through systematic neonatal craniofacial screening.

Conclusion: Optimal craniosynostosis surgery timing is technique-dependent, suture-specific, and syndromic-status-driven. The overarching principle remains consistent: correction within the first year of life protects neurodevelopmental trajectories and maximizes morphological outcomes, while neonatal intervention carries perioperative risks requiring experienced multidisciplinary team management.

P278 - Transvaginal extrusion of a ventriculoperitoneal shunt in an infant: a rare complication of cerebrospinal fluid diversion

Ahmed Mribah, M. Ben Messaoud, R. Ben Fredj, S. Gallaoui, M.A. Hmida, C. Abdelilah, I. Ksira

Department of Neurosurgery, Sahloul Hospital, Sousse, Tunisia

Background: Ventriculoperitoneal shunt (VPS) placement remains the standard treatment for pediatric hydrocephalus. Although generally safe, VPS-related abdominal complications may occur. Transvaginal extrusion of the distal catheter is an exceptionally rare event in infants and may predispose to severe infectious complications. We report a case of vaginal extrusion of a VPS in a premature infant and discuss its management.

Case presentation: A 5-month-old female infant with a history of extreme prematurity at 28 weeks' gestation was admitted for transvaginal extrusion of the distal catheter of a ventriculoperitoneal shunt. Her neonatal course had been complicated by respiratory distress requiring intensive care admission, seizures treated with levetiracetam, and quadriventricular hydrocephalus managed by VPS insertion at the age of two months. She subsequently underwent surgery for intussusception. On admission, the infant was awake and reactive. Physical examination revealed a normotensive anterior fontanelle, head circumference within normal limits (+0.7 SD), axial hypotonia related to prematurity, and absence of fever. The distal peritoneal catheter was protruding through the vagina with active cerebrospinal fluid leakage. Results and outcomes The patient underwent urgent shunt removal and reinternalization with placement of a new ventriculoperitoneal shunt. The postoperative course was complicated by shunt-related meningitis, necessitating removal of the internal shunt system and placement of an external ventricular drain for 21 days. Following resolution of the infection and sterile cerebrospinal fluid cultures, a new ventriculoperitoneal shunt was successfully implanted.

Conclusion: Transvaginal extrusion of a ventriculoperitoneal shunt is an extremely rare but serious complication requiring prompt surgical management because of the high risk of central nervous system infection. Early recognition, complete shunt externalization, treatment of associated infections, and delayed shunt reinternalization remain the cornerstones of management. Prematurity, previous abdominal surgery, and bowel-related complications may represent contributing factors and warrant further investigation.

P279 - Traumatic wounds of the superior sagittal sinus: surgical challenges and management strategies

Mohamed Znazen, A. Hachicha, H. Belmabrouk

Department of Neurosurgery, University Hospital of Gabès, Tunisia.

Background: Traumatic injuries of the dural venous sinuses occur in 1.5–5% of head trauma cases, with the superior sagittal sinus (SSS) involved in approximately 70–80% of cases. These lesions represent a major neurosurgical emergency because of the risk of massive hemorrhage, venous thrombosis, intracranial hypertension, and neurological deterioration. Their management remains challenging and requires prompt diagnosis and individualized surgical treatment.

Methods: We retrospectively reviewed four patients presenting with traumatic superior sagittal sinus injuries associated with depressed skull fractures. Clinical presentation, radiological findings, surgical management, and outcomes were analyzed.

Results: The series included four male patients aged 30 to 67 years. Computed tomography demonstrated depressed skull fractures crossing or compressing the superior sagittal sinus in all cases. One patient presented with tetraplegia following assault-related head trauma and underwent emergency craniectomy with difficult hemostasis of the anterior third of the SSS. A second patient presented with a large frontal scalp laceration and a comminuted depressed frontal fracture involving the sinus and underwent urgent surgical repair. The third patient presented with right hemiparesis related to a parietal depressed fracture compressing the middle third of the SSS; surgical management consisted of bone flap elevation and sinus hemostasis. The fourth patient presented with right crural monoparesis secondary to a left parieto-occipital depressed fracture and underwent surgical decompression. In all cases, surgery aimed to elevate the depressed fragments, control venous bleeding, preserve sinus patency whenever possible, and prevent secondary neurological complications. Favorable neurological outcomes were achieved without major postoperative venous complications.

Conclusions: Traumatic superior sagittal sinus injuries are rare but potentially life-threatening lesions. Early diagnosis and timely surgical intervention are essential to achieve hemorrhage control while preserving venous drainage. Management should be tailored according to the location of sinus involvement, fracture pattern, and neurological status. Careful surgical planning can lead to favorable neurological outcomes despite the technical challenges associated with these injuries.

P280 - Tumefactive brain lesions: diagnostic challenges and clinicoradiological clues from a 14-year single-center cohort

Ahmed Amine Daoued, Y. Boubaker, R. Ben Dhia, N. Daoussi, M. Mhiri

Department of Neurology, Fattouma Bourguiba University Hospital, Monastir, Tunisia

Background: Tumefactive brain lesions (TBLs) are uncommon lesions that often mimic primary brain tumors because of their large size, mass effect, and overlapping clinical and radiological features. They encompass a heterogeneous spectrum of inflammatory, neoplastic, and infectious disorders, making early etiological diagnosis particularly challenging. This study aimed to describe the clinical presentation, neuroimaging characteristics, etiological spectrum, management, and outcomes of patients presenting with tumefactive brain lesions, while highlighting features that may help distinguish inflammatory from neoplastic etiologies.

Methods: We conducted a retrospective single-center study including consecutive patients presenting with tumefactive brain lesions and managed in the Neurology Department of Fattouma Bourguiba University Hospital (Monastir, Tunisia) between 2010 and 2024. Demographic, clinical, radiological, biological, therapeutic, and follow-up data were reviewed. Patients were classified according to their final diagnosis into inflammatory, neoplastic, or infectious etiologies.

Results: Thirty-four patients were included, with a mean age of 41.9 years and a slight male predominance. Inflammatory disorders were the most frequent etiologies, mainly represented by multiple sclerosis and Behçet disease, followed by primary brain tumors and one infectious lesion (tuberculoma). Headache was the most common presenting symptom, followed by motor deficits and sensory disturbances. Supratentorial involvement predominated, and mass effect was observed in a substantial proportion of patients. Intracranial hypertension syndrome occurred predominantly in patients with neoplastic lesions, whereas multifocal lesions and favorable corticosteroid response were more frequently associated with inflammatory diseases. Nevertheless, transient clinical and radiological improvement following corticosteroid therapy was occasionally observed in tumoral lesions, limiting its diagnostic specificity.

Conclusions: Tumefactive brain lesions remain a major diagnostic challenge because of the considerable overlap between inflammatory and neoplastic disorders. Although certain clinical and radiological features may orient the diagnosis, no single finding reliably excludes an underlying tumor. Early multidisciplinary evaluation and, when necessary, histopathological confirmation remain essential to guide appropriate management.

P281 - Ultrasound contribution in the diagnosis of carpal tunnel syndrome.

Atika Mallek, Elleuch.W[1 4], Gahbich.F[3], Kolsi.F[3], Azaza. M[5], Elleuch Mh[2 4]

[1] Physical medicine department, Military university hospital of sfax , Tunisia

[2] Department of Physical Medicine, Habib Bourguiba Hospital of Sfax, Tunisia

[3] Department of Neurosurgery, Habib Bourguiba Hospital of Sfax, Tunisia

[4] Research Unit for the Evaluation of Musculoskeletal Disorders (04/UR/08-07), University of Sfax, 3000, Tunisia

[5] General surgery Department , Military university hospital of sfax , Tunisia

Introduction: Carpal tunnel syndrome (CTS) is the most common of the ductal syndromes, and its diagnosis is generally based on clinical criteria and electromyogram (EMG). High-resolution ultrasound (US) has become one of the most effective imaging techniques for peripheral nerves damages. Our Objectif is to assess the US contribution in the diagnosis of CTS.

Methodology: This was a cross-sectional study including patients consulting in the Physical Medicine Department in Sfax, Tunisia for acroparaesthesia. Patients with diabetes, hypothyroidism, or neurological pathologies were excluded. Clinical exam, US measurements of the cross-sectional area (CSA) of the median nerve and Nerve conduction studies were conducted for all hands. We used the SPSS program, version 2023 for the statistics analysis .

Results: 22 hands were included in this study of whom 80% are women with an average age of 59.5 (+/-10) years. We studied the performance of US in predicting the diagnostic of CTS by calculating the validity criteria. The study of US's efficacy in diagnosing CTS has shown that it has a 100% sensitivity and a 40% specificity. Furthermore, the diagnostic accuracy was 86.3%, with a positive predictive value of 85% and a negative predictive value of 100%.

Conclusion: Although US cannot completely replace electrodiagnosis as the most reasonable and specific test for CTS diagnosis, it may provide a viable alternative to EMG. However, clinical context should be taken in consideration before diagnosis confirmation.

P282 - Unexpected pneumocephalus after endotracheal intubation and mechanical ventilation: a case report

Emna Elouni, Roua Latrach, Khalil Ghedira, Emna Mzoughi, Sofiene Bouali, Khansa Abderrahmene, Asma Bouhoula, Jalel Kallel

Neurosurgery Departement, National Institute of Neurology, Tunis, Tunisia

Background: Pneumocephalus is typically associated with cranial trauma, neurosurgical procedures, or skull base defects. Its occurrence following mechanical ventilation in patients without previous intracranial pathology is exceedingly rare.

Methods: A 45-year-old man was admitted to the intensive care unit for acute respiratory failure secondary to a severe asthma exacerbation. Due to worsening respiratory distress, endotracheal intubation and invasive mechanical ventilation were required. During intubation, the patient developed a cardiac arrest and underwent successful cardiopulmonary resuscitation, with return of spontaneous circulation after 15 minutes.

Results: Following discontinuation of sedation, the patient failed to regain consciousness. An urgent brain computed tomography scan revealed extensive intracranial pneumocephalus. No history of cranial trauma, neurosurgical intervention, or known skull base pathology was identified. Further investigations did not reveal an obvious route of air entry. The most likely mechanism was barotrauma induced by positive-pressure ventilation, resulting in intracranial migration of air through an occult osteodural defect. The patient was managed conservatively with close neurological monitoring and supportive care.

Conclusions: Pneumocephalus is a rare but important complication of positive-pressure ventilation. Although uncommon, it should be considered in mechanically ventilated patients presenting with delayed awakening or unexplained neurological deterioration. Early neuroimaging is essential for diagnosis and may facilitate prompt management.

P283 - Uniportal endoscopic decompression for degenerative lumbar spinal stenosis: technical challenges, current limitations, and surgical perspectives

Houssem Hdhili, M.D.Yedeas, A. Affes, A. Rachdi, S. Achoura, A. Harbaoui, R. Chkili, K. Radhouane

Department of Neurosurgery, Military Hospital of Tunis, Tunisia

Background: Uniportal endoscopic decompression has emerged as an important minimally invasive option for the management of degenerative lumbar spinal stenosis. By minimizing muscle and ligament disruption, it offers faster recovery and reduced postoperative morbidity. However, its application remains technically demanding because adequate neural decompression must be achieved through a narrow working corridor.

Methods: A narrative review of the recent literature was conducted, focusing on uniportal endoscopic decompression for degenerative lumbar spinal stenosis. Systematic reviews, meta-analyses, and clinical series were analyzed to identify technical challenges, indications, limitations, and reported clinical outcomes.

Results: Current evidence demonstrates that uniportal endoscopic decompression provides clinical outcomes comparable to conventional microscopic techniques in carefully selected patients. The best candidates are patients with single-level stenosis, lateral recess stenosis, or well-localized compressive pathology. In contrast, multilevel stenosis, spinal instability, deformity, and severe central stenosis remain technically challenging. The main intraoperative difficulties include the restricted working corridor, demanding anatomical orientation, epidural bleeding control, and the risk of incomplete decompression. A steep learning curve remains one of the principal barriers to wider adoption, directly influencing operative time, complication rates, and the quality of decompression. Although overall complication rates are low, reported adverse events include dural tears, dysesthesia, epidural hematoma, infection, and, most importantly, persistent symptoms due to insufficient decompression. Recent studies suggest that biportal endoscopy may facilitate extensive bony and ligamentous decompression through greater instrument mobility, whereas the uniportal approach preserves the advantages of a less invasive access.

Conclusion: Uniportal endoscopic decompression is an effective but technically demanding procedure for degenerative lumbar spinal stenosis. Successful outcomes depend on meticulous patient selection and advanced surgical expertise. It represents an excellent minimally invasive option for selected cases but should not replace conventional approaches in complex stenotic disease.

P284 - Unusual intracranial foreign bodies: a case series and surgical management strategy in penetrating cranial trauma

Farah Bahri, F.Ben Atig[2], H.Hdhili, F.Ferjani, M.Bounemra, A.Hermassi, S.Ben Zekri, A.Bedioui, M.Rkhami, M.Badri, K.Bahri, I.Zammel

Department of Neurosurgery, Ben Arous Trauma Center, Tunisia,
[2]Regional Hospital Sadok Mokaddem of Djerba, Tunisia.

Background: Penetrating cranial injuries due to unusual foreign bodies are rare and represent with significant diagnostic and therapeutic challenges. Objects such as knives, axes, bullets, and metallic keys have been infrequently reported in the literature. Management requires rapid radiological assessment, meticulous surgical planning, and multidisciplinary coordination to prevent secondary brain injury and infectious complications. We report a series of unusual intracranial foreign bodies and discuss principles of management.

Methods: We retrospectively reviewed patients presenting with penetrating intracranial injuries caused by atypical foreign bodies managed at our institution. Clinical presentation, mechanism of injury, neuroimaging findings (CT/CTA), surgical strategy, perioperative management, complications, and clinical outcomes were analyzed. Emphasis was placed on vascular assessment, trajectory of penetration, and timing of surgical extraction.

Results: The series included patients with penetrating brain injuries caused by diverse foreign bodies including an axe, a projectile, and a metallic key. Clinical presentation ranged from preserved neurological status to focal neurological deficits depending on the trajectory and affected cerebral regions. Computed tomography was essential for defining the extent of penetration and associated hemorrhagic lesions, while CT angiography was critical to rule out vascular injury. All patients underwent individualized surgical management with controlled extraction of the foreign body under direct visualization, followed by debridement and hemostasis. No uncontrolled intraoperative hemorrhage occurred. Postoperative outcomes varied according to initial injury severity, with most patients demonstrating neurological stabilization or improvement. Infectious prophylaxis and antiepileptic therapy were systematically administered.

Conclusions: Intracranial penetrating injuries caused by unusual foreign bodies remain rare but potentially life-threatening emergencies. Optimal outcomes depend on early imaging assessment, vascular evaluation, and carefully planned surgical extraction rather than blind removal. A multidisciplinary approach is essential to minimize complications and improve neurological prognosis.

P285 - Unusual radiopathological presentation of high grade glioma mimicking an extra-axial lesion: a case report

Bushra Kurdi, Abeer Mutair Alshamani [2], Majd Abdulhamid Samman [2], Bassem Yousef Sheikh [2].

[1]- College of Medicine, Taibah University, Medina, Saudi Arabia.

[2]- Department of Neurosurgery, King Salman bin Abdulaziz Medical City, Medina, Saudi Arabia

Background: High-grade gliomas are aggressive primary intra-axial brain tumors characterized by rapid progression, poor prognosis, and typical radiological features including heterogeneous enhancement, necrosis, and surrounding vasogenic edema. However, in certain cases, extensive necrosis and inflammatory changes may significantly alter the radiological appearance of the tumor. These atypical features can obscure the classical intra-axial pattern and may mimic extra-axial lesions, leading to diagnostic uncertainty. Such radiological ambiguity presents a clinical challenge, as differentiation between intra -axial and extra-axial pathology is essential for surgical planning and managemen.

Objective: To present a case of high-grade glioma with atypical radiological features mimicking an extra-axial lesion, and to highlight the importance of integrating clinical, radiological, intraoperative, and histopathological findings for accurate diagnosis.

Case presentation: A 63-year-old male with Parkinson's disease presented with progressive cognitive decline, language impairment, and mild gait imbalance over one month. Neuroimaging demonstrated a large left temporal enhancing mass with significant vasogenic edema and midline shift. The radiological appearance raised concern for high-grade glioma, although the extensive necrotic and inflammatory components complicated interpretation. The patient underwent left temporal craniotomy and tumor resection. Histopathology revealed an atypical glial neoplasm with extensive necrosis and a high proliferative index (Ki-67: 30%), favoring high-grade glioma. Immunohistochemistry showed strong S100 and CD56 positivity, p53 expression in scattered atypical cells, and negative EMA and pancytokeratin staining. Postoperatively, the patient demonstrated neurological improvement.

Conclusion: This case highlights the importance of comprehensive radiopathological correlation in intracranial tumors. Extensive necrosis and inflammatory changes may obscure typical imaging features, reinforcing the necessity of histopathological and molecular evaluation for definitive diagnosis and management.

P286 - Ventriculoperitoneal shunt infection following appendicular peritonitis with secondary multiloculated hydrocephalus: a case report.

Si Tayeb Fatima Zohra, Y. Djouadi, N. Osmani, N. Slamani, A. Benhaddadi, L. Maameri, M. Chahed, K. Ait Slimani, S. Bouraoui, H. Bourbia, M. Ait Bachir.

Department of Neurosurgery, Tizi Ouzou University Hospital, Tizi Ouzou, Algeria.

Introduction: Appendicular peritonitis is an uncommon but serious cause of ventriculoperitoneal shunt infection in children with shunt-dependent hydrocephalus. Management is particularly challenging in the presence of polymicrobial ventriculitis, multiloculated hydrocephalus, and persistent CSF abnormalities causing recurrent shunt dysfunction. We report a pediatric case successfully treated with two external ventricular drainages, intrathecal colistin, and adjunctive corticosteroid therapy.

Case presentation: A 3-year-old girl with shunt-dependent hydrocephalus was admitted for appendicular peritonitis and underwent emergency appendectomy. Several days later, she developed altered consciousness. During shunt revision, the distal peritoneal catheter was found to be non-functional and filled with thick purulent material. The ventriculoperitoneal shunt was removed and replaced with an external ventricular drain (EVD). Despite appropriate antimicrobial therapy, neurological improvement remained limited. Brain MRI demonstrated multiloculated hydrocephalus, prompting placement of a second contralateral EVD. Intrathecal colistin played a key role in achieving CSF sterilization. However, persistent ventriculitis was associated with severe hyperproteinorrachia (6 g/L), leading to repeated ventriculoperitoneal shunt obstruction due to increased CSF viscosity after shunt reinsertion. A 15-day course of corticosteroids resulted in a marked reduction in CSF protein concentration, allowing definitive shunt replacement with good clinical and radiological outcomes.

Discussion: This case highlights the complexity of polymicrobial ventriculoperitoneal shunt infections in children. Intrathecal colistin achieved CSF sterilization without complications. Multiloculated hydrocephalus required bilateral external ventricular drainage. Persistent hyperproteinorrachia led to recurrent shunt obstruction, likely secondary to increased CSF viscosity, but adjunctive corticosteroid therapy was associated with a marked reduction in CSF protein levels, enabling successful definitive shunt reinsertion.

Conclusion: Post-appendicular peritonitis may cause severe polymicrobial ventriculoperitoneal shunt infection. Multiloculated hydrocephalus may require bilateral external ventricular drainage. When pathogens are susceptible, intrathecal colistin can achieve CSF sterilization. Persistent hyperproteinorrachia should be recognized as a cause of recurrent shunt obstruction, and corticosteroids may facilitate definitive shunt reinsertion by reducing CSF protein levels.

P287 - Ventriculovesical shunting: an uncommon salvage option for pediatric hydrocephalus

Amina Oueslati, Sliti F, Slimane A, Abdelmoula A, Nessib N, Ben Said I, Kallel J

Department of neurosurgery , National Institute of Neurology, Tunisia.

Introduction: Hydrocephalus is a frequent complication of posterior fossa tumors in children and often requires long-term cerebrospinal fluid (CSF) diversion. Ventriculoperitoneal shunting remains the standard treatment; however, repeated shunt failure may necessitate alternative distal drainage sites. Ventriculovesical shunting is rarely performed and is generally reserved for complex cases in which conventional options have been exhausted.

Objective: To report a rare case of refractory shunt-dependent hydrocephalus successfully managed with ventriculovesical shunting following multiple ventriculoperitoneal shunt failures.

Case presentation: A 12-year-old child underwent surgical resection of a posterior fossa ependymoma initially classified as WHO grade 2. During follow-up, tumor recurrence was diagnosed and histopathological examination following reoperation revealed an anaplastic ependymoma (WHO grade 3). The patient subsequently developed chronic hydrocephalus requiring ventriculoperitoneal shunt placement. Over time, multiple shunt revisions were performed because of recurrent dysfunction and distal catheter failure. After repeated unsuccessful attempts to maintain adequate CSF diversion using conventional techniques, a multidisciplinary decision involving neurosurgeons and urologists led to the placement of a ventriculovesical shunt. The postoperative course was favorable, with resolution of intracranial hypertension symptoms and satisfactory shunt function during follow-up.

Discussion: Management of refractory hydrocephalus in pediatric neuro-oncology patients can be challenging, particularly after repeated distal shunt failures. Alternative distal sites, including the pleural cavity, atrium, and urinary bladder, may be considered when the peritoneal cavity is no longer suitable. Ventriculovesical shunting remains an uncommon option but may provide effective long-term CSF diversion in selected patients. Its successful implementation requires close multidisciplinary collaboration and careful monitoring for urological and metabolic complications.

Conclusion: Ventriculovesical shunting represents a valuable salvage option for refractory hydrocephalus when conventional CSF diversion strategies fail. This case illustrates the importance of individualized management and multidisciplinary decision-making in complex pediatric neurosurgical patients.

P288 - Vertebrobasilar thrombectomy and hemorrhagic transformation : a single-center experience

Olfa Sakli, Rania Zouari, Amine Ben Lakhal, Adonis Halouani, Dina Ben Mohamed, Samia Ben Sassi, Nadia Hammami

Mongi Ben Hamida National Institute of Neurology Adult Department Tunis Tunisia; Mongi Ben Hamida National Institute of Neurology Radiology Department Tunis Tunisia

Background: Hemorrhagic transformation (HT) is a recognized complication of mechanical thrombectomy (MT), yet its incidence and predictors in the posterior circulation remain poorly characterized. We aimed to describe the rate and characteristics of HT following MT for vertebrobasilar artery occlusion (VBAO) and to identify associated clinical and procedural factors.

Methods: We retrospectively reviewed 13 consecutive patients who underwent MT for angiographically confirmed vertebral or basilar artery occlusion between 2015 and 2026 at the Neurology Department of Mongi Ben Hamida National Institute of Neurology, Tunis, Tunisia. HT was identified on post-procedural CT or MRI and classified according to ECASS criteria. Clinical (baseline NIHSS, GCS, etiology), imaging (occlusion site, PC-ASPECTS), and procedural variables (number of passes, mTICI grade) were analyzed as potential associated factors.

Results: Thirteen patients (median age 57 years; 8 males) were included. Median baseline NIHSS was 12 [IQR 6–17]. Impaired consciousness at admission was present in 10/13 patients. The predominant etiologies were atherosclerosis (n=4) and cardioembolic stroke (n=3). Successful reperfusion (mTICI ≥ 2b) was achieved in 10/13 patients (76.9%), with complete reperfusion (mTICI 3) in 9/10. Favorable outcome (mRS ≤ 2 at 3 months) was achieved in 4/7 patients with available follow-up. In-hospital mortality was 38.5% (5/13). Symptomatic HT occurred in 1/13 patients (7.7%), presenting as a large intraparenchymal hematoma with subarachnoid hemorrhage, in a patient with cardioembolic etiology, hypertension, antiplatelet pretreatment, high baseline NIHSS (17), and distal basilar-PCA territory occlusion with complete reperfusion (mTICI 3). Despite HT, this patient achieved mRS 2 at 3 months.

Conclusion: MT for acute VBAO achieved high reperfusion rates with acceptable safety. Baseline clinical, etiological, and radiological parameters could help identify patients at higher risk of hemorrhagic transformation and better guide therapeutic decision in posterior circulation thrombectomy.

P289 - Vitamin d deficiency in spine surgery: a silent but modifiable determinant of poor postoperative outcomes

Majdouline Barkache, R. Benfredj, S. Galaoui, A. Guerrioui, I. Ksira.

Department of Neurosurgery, Sahloul University Hospital, Sousse, Tunisia

Background: Vitamin D deficiency is highly prevalent worldwide and particularly common in patients requiring spine surgery. Beyond its classical role in bone metabolism, it influences osteointegration, immune regulation, and tissue healing. Increasing evidence suggests that this “silent deficiency” may negatively affect surgical outcomes, yet it remains largely overlooked in routine preoperative assessment.

Methods: This narrative review synthesizes current literature examining the relationship between vitamin D status and outcomes after spine surgery. Studies reporting associations with fusion rates, pseudarthrosis, implant complications, infection risk, and functional recovery were analyzed to identify consistent clinical trends and biological mechanisms.

Results: The literature consistently suggests that vitamin D deficiency is associated with impaired spinal fusion, higher rates of pseudarthrosis, and increased implant-related complications. Some studies also report a higher incidence of surgical site infection and delayed functional recovery in deficient patients. Mechanistically, vitamin D influences osteoblast activity, calcium-phosphate homeostasis, and immune modulation, which may explain these adverse outcomes. However, variability in study designs, vitamin D thresholds, and surgical populations limits definitive conclusions.

Conclusion: Vitamin D deficiency represents a frequent, underdiagnosed, and potentially modifiable risk factor in spine surgery. Although high-level evidence is still limited, existing data strongly suggest a clinically relevant association with poorer postoperative outcomes. Systematic preoperative screening and correction could represent a simple, low-cost strategy to improve surgical prognosis. Prospective randomized studies are needed to establish standardized guidelines.

P290 - Volkmann syndrome following a jellyfish sting: a case report

Elleuch. Wafa[1], [4], Mallek.A[1], Gahbich.F[3], Herchi. W[5], Kolsi.F[3], Elleuch Mh[2] [4]

[1] Physical medicine department, Military university hospital of sfax , Tunisia

[2] Department of Physical Medicine, Habib Bourguiba Hospital of Sfax, Tunisia

[3] Department of Neurosurgery, Habib Bourguiba Hospital of Sfax, Tunisia

[4] Research Unit for the Evaluation of Musculoskeletal Disorders (04/UR/08-07), University of Sfax, 3000, Tunisia

[5] General surgery Department , Military university hospital of sfax , Tunisia

Introduction: Volkmann syndrome is a rare ischemic complication resulting from increased intracompartmental pressure, leading to major functional sequelae of the upper limb. Its aetiology is most often traumatic or compressive. Toxic causes, particularly following a jellyfish sting, remain exceptional and are rarely reported in the literature.

Objective: To report a case of Volkmann syndrome following a jellyfish sting.

Methods: We report the case of an 8-year-old girl with no prior medical history, presenting with progressive weakness and muscle atrophy of the right hand over the past six months, following a jellyfish sting to the medial aspect of the right elbow. Clinical examination revealed an ulnar claw deformity, flexion contracture of the fourth and fifth digits, atrophy of the hypothenar eminence, and motor deficit of the abductor digiti minimi muscle graded at 1/5. Deep tendon reflexes were preserved, with no pyramidal signs. Electromyography showed reduced amplitudes of the ulnar nerve action potentials with normal conduction velocities, associated with an intermediate neurogenic pattern in the abductor digiti minimi muscle. Spinal MRI revealed no abnormalities. The diagnosis of Volkmann syndrome of the right hand was established.

Results: The clinical and electrophysiological findings were consistent with chronic ischemic involvement of the anteromedial compartment of the forearm, resulting in motor and trophic deficits predominantly affecting the ulnar nerve territory. Surgical management with forearm decompressive aponeurotomy was indicated in order to limit the progression of functional sequelae. Discussion–

Conclusion: Jellyfish venoms can induce an intense inflammatory reaction, local vasoconstriction, and massive edema, promoting an increase in intracompartmental pressure and tissue ischemia, which may exceptionally progress to Volkmann syndrome [1,2]. Peripheral neurological complications following marine envenomation have been reported, including focal neuropathies and plexopathies, highlighting the potential neurotoxicity of these venoms [3,4]. In this context, early diagnosis and prompt management are essential to prevent the development of permanent functional sequelae. Electromyography helps to clarify the underlying lesion mechanism and the degree of neuromuscular involvement, while decompressive surgery remains the treatment of choice in advanced cases [5].

P291 - Walking back to life: postoperative outcomes after shunt surgery in adult chronic hydrocephalus

Ahmed Amine Daoued, M.I. Krifa, M.M Hadhri, M. Ghorbel, M. Darmoul

Neurosurgery Department, Fattouma Bourguiba University hospital, Monastir, Tunisia.

Background: Adult chronic hydrocephalus is a progressive neurological disorder caused by cerebrospinal fluid accumulation within the ventricular system. It is classically associated with gait disturbance, cognitive decline, and sphincter dysfunction, significantly affecting patient autonomy and quality of life. Ventriculoperitoneal shunting remains the main therapeutic option, aiming to improve neurological function and daily living.

Methods: We conducted a retrospective study including 50 patients diagnosed with adult chronic hydrocephalus who underwent ventriculoperitoneal shunt placement in the Neurosurgery Department of Fatouma Bourguiba Hospital, Monastir, between January 2020 and December 2023. Postoperative outcomes were assessed according to motor function, sphincter control, cognitive performance, and patient-reported quality of life.

Results: After surgery, 70% of patients showed significant motor improvement, mainly reflected by better gait stability and coordination. Sphincter control improved in 64% of cases, with a reduction in urinary incontinence. Cognitive improvement was observed in 58% of patients, particularly in memory recall and attention, based on Mini-Mental State Examination assessment. Overall quality of life improved in 76% of cases. However, 20% of patients showed minimal or no cognitive recovery despite shunt placement, suggesting that cognitive outcome may depend on additional factors such as disease duration, baseline cognitive status, comorbidities, or irreversible parenchymal damage.

Conclusions: Ventriculoperitoneal shunting provides meaningful postoperative improvement in adult chronic hydrocephalus, particularly in gait, sphincter control, and overall quality of life. Cognitive recovery appears more variable and less predictable. Further studies are needed to identify prognostic factors associated with favorable cognitive outcomes after shunt surgery.

P292 - When MRI misleads: b-cell lymphoma, the great imitator of metastasis

Angham Grioui, Ben Fredj Rihab, Gallaoui Slim, Hamida Mohamed Amine, Barkache Majdouline, Ksira Iyadh

Department of Neurosurgery, Sahloul University Hospital, Sousse, Tunisia

Background & objectives: Spinal tumors are a rare but potentially serious cause of spinal cord compression. Among them, spinal B-cell lymphomas are uncommon and often present with atypical clinical and radiological features that mimic infectious or metastatic diseases, making diagnosis particularly challenging. Definitive diagnosis relies on histopathological examination.

Methods: We report the case of a 54-year-old man with type 2 diabetes treated with oral antidiabetic drugs, who presented with bilateral L2–L3 lumbocruralgia evolving over one month, associated with gait disturbance for eight days. There was no history of trauma or bladder and bowel dysfunction. Neurological examination revealed paraplegia without a sensory level or pyramidal signs. Lumbar MRI demonstrated L2 spondylitis associated with anterior and posterior epiduritis causing significant spinal canal compression, initially suggestive of metastasis and, secondarily, an infectious process. Thoraco-abdomino-pelvic CT scanning showed no evidence of a primary tumor or secondary lesions. Given the clinical presentation of spinal cord compression, the patient underwent L1–L3 laminectomy and a biopsy was performed.

Results & discussion: histopathological examination with immunohistochemical analysis revealed a small B-cell lymphoma of germinal center origin (CD20+, CD45+, CD10+, Bcl6+, CD3−), thereby excluding a metastatic etiology. Postoperatively, the patient remained neurologically stable with persistent motor deficit but experienced significant relief of lumbocruralgia. He was subsequently referred to the hematology department for specialized management.

Conclusion: Primary spinal B-cell lymphoma is a rare entity that frequently presents as spinal cord compression. Its pseudo-infectious or pseudo-metastatic appearance on imaging can be misleading and delay diagnosis. Decompressive laminectomy plays a crucial role by relieving neural compression and providing tissue for histopathological confirmation. Systemic chemotherapy remains the cornerstone of treatment, and prognosis largely depends on early diagnosis and prompt therapeutic intervention.

P293 - When neurosurgery meets aesthetics: ethical boundaries of cosmetic considerations in brain surgery

Ameur Affes, Rachdi M.A., Hdhili H, Bouzouita K, Achoura S, Chkili Ridha, Radhouen K.
Neurosurgery Department, Military Hospital of Tunis, Tunis, Tunisia

Background & objectives: Neurosurgery has historically prioritized survival and neurological function as the cardinal outcomes of surgical success, relegating aesthetic considerations to secondary status. Yet mounting evidence demonstrates that postoperative cosmetic outcomes — cranial contour, scalp scarring, alopecia, and facial symmetry — significantly impact patient-reported quality of life, body image, and psychological recovery following neurosurgical procedures. As patient expectations evolve and reconstructive technologies advance, defining the ethical boundaries of aesthetic integration in neurosurgical practice becomes both clinically relevant and philosophically necessary. This review examines the ethical framework governing cosmetic considerations in brain surgery.

Methods: Narrative review of PubMed, Scopus, and bioethics databases (2000–2024), including patient-reported outcome studies, surgical ethics literature, and qualitative research addressing aesthetic outcomes, patient satisfaction, and ethical dimensions of cosmetic decision-making in neurosurgery.

Results & discussion: Patient-reported aesthetic burden: Post-craniotomy alopecia, visible skull defects, and facial asymmetry following skull base or cranial nerve surgery are consistently associated with reduced self-esteem, social withdrawal, and impaired psychological recovery, independent of neurological outcome — validating aesthetic outcomes as legitimate clinical endpoints. Informed consent and aesthetic disclosure: Current neurosurgical consent frameworks inadequately address cosmetic sequelae, creating an ethical gap between patient expectations and disclosed outcomes. Integrating structured aesthetic risk communication into preoperative counseling respects patient autonomy and reduces postoperative dissatisfaction. Therapeutic versus cosmetic intent: A critical ethical boundary exists between aesthetic improvements intrinsic to optimal surgical technique — trichophytic incisions, custom cranioplasty, facial nerve preservation — and purely cosmetic modifications without functional justification, which raise resource allocation and primum non nocere concerns. Equity considerations: Access to aesthetically optimized reconstruction, including custom 3D implants and nerve rehabilitation, remains inequitably distributed, raising justice-based ethical questions regarding standardization of aesthetic care across healthcare settings.

Conclusion: Aesthetic outcomes in neurosurgery are neither trivial nor ethically optional. Integrating cosmetic considerations within a principled ethical framework — grounded in autonomy, beneficence, and justice — represents an evolving standard of comprehensive neurosurgical care.

P294 - When pregnancy guides neurosurgical decision: a case report of a hemangioblastoma discovered in a pregnant patient in her last trimester.

Ahmed Mribah, R. Ben Fredj, S. Gallaoui, B. Hajji, M.A Hmida, O. Hattab, M. Ben Messaoud, I. Ksira

Department of Neurosurgery, Sahloul Hospital, Sousse, Tunisia

Introduction: Intracranial tumors diagnosed during pregnancy are rare and represent a major therapeutic challenge. Management requires balancing maternal neurological preservation with fetal safety and maturity. Hemangioblastomas are uncommon benign highly vascular tumors, most frequently arising in the cerebellum. Pregnancy-related physiological changes may accelerate symptom progression through increased blood volume and tumor-associated edema.

Case presentation: A 41-year-old pregnant woman (G2P1A0) at 31 weeks' gestation presented with persistent headaches, vomiting, and progressive gait disturbance evolving over one month despite symptomatic medical treatment. Neurological examination revealed an alert patient (Glasgow Coma Scale 15/15) with no cranial nerve, motor, or sensory deficits, but with a static and kinetic cerebellar syndrome. Obstetrical assessment showed an uncomplicated pregnancy with reassuring fetal status. Brain magnetic resonance imaging demonstrated a left cerebellar cystic-solid lesion with a mural nodule compressing the fourth ventricle and causing active triventricular hydrocephalus, suggesting in the first place a Hemangioblastoma.

Results: Management and outcome Following multidisciplinary discussion involving neurosurgeons, obstetricians, anesthesiologists, and neonatologists, a staged therapeutic strategy was adopted. Given the patient's stable neurological status and the need to optimize fetal maturity, an external ventricular drain was inserted under local anesthesia to control intracranial hypertension while maintaining the pregnancy without exposing the fetus to sedation and anesthesia's potential outcomes. At 34 weeks' gestation, cesarean delivery was performed, resulting in the birth of a healthy newborn. Two days later, a ventriculoperitoneal shunt was inserted for definitive cerebrospinal fluid diversion. Definitive surgical resection of the posterior fossa lesion was performed ten days after delivery. Histopathological examination confirmed cerebellar hemangioblastoma. The postoperative course was favorable, with improvement of intracranial hypertension symptoms and cerebellar dysfunction. Both maternal and neonatal outcomes were satisfactory.

Conclusion: In selected pregnant patients with stable neurological status, temporary cerebrospinal fluid diversion may safely defer definitive neurosurgical treatment until after delivery. Multidisciplinary management is essential for optimizing maternal and fetal outcomes.

P295 - When the brain speaks first: cerebral metastasis unmasking a giant non-functional adrenocortical carcinoma

Rihab Ben Fredj, Barkache Majdouline, Grioui Angham, Gallaoui Slim, Hamida Mohamed Amine, Ksira Iyadh

Department of Neurosurgery, Sahloul Hospital, Sousse, Tunisia

Background: Adrenocortical carcinoma (ACC) is a rare and highly aggressive tumor often discovered incidentally. Brain metastasis from ACC are exceptionally rare and typically occur in advanced stages of the disease. We report an unusual case in which a symptomatic cerebral metastasis led to the diagnosis of a giant non-functional ACC.

Methods: A 50-year-old man with no medical history presented with headache and dizziness. Brain computed tomography revealed a large left temporal intracerebral mass associated with significant vasogenic edema and mass effect. Further imaging identified a 15-cm necrotic adrenal mass. Hormonal workup excluded a functional adrenal tumor. Histopathological and immunohistochemical analyses of a CT-guided biopsy specimen confirmed the diagnosis of ACC.

Results: The intracranial lesion was diagnosed as a cerebral metastasis originating from a giant non-functional ACC. Histopathological examination revealed features consistent with ACC, including a Weiss score of 7 and diffuse positivity for inhibin. Despite the planned multidisciplinary management, including adrenalectomy and mitotane-based therapy, the patient's condition deteriorated rapidly, resulting in fatal brain herniation.

Conclusion: Cerebral metastasis may rarely represent the initial manifestation of ACC and should be considered in the differential diagnosis of large intracranial lesions of unknown origin. This case highlights the aggressive nature of ACC, the diagnostic challenges posed by atypical metastatic presentations, and the importance of prompt multidisciplinary assessment and management.

P296 - When the cure becomes the disease

Farah Bahri, F.Ben Atig[2], H.Hdhili, M.A.Kharrat, M.Bounemra, A.Hermassi, S.Ben Zekri, A.Bedioui, M.Rkhami, M.Badri, K.Bahri, I.Zammel

Department of Neurosurgery, Ben Arous Trauma Center, Tunisia

[2]Regional Hospital Sadok Mokaddem of Djerba, Tunisia

Background: Advances in cranial radiotherapy have significantly improved survival in patients with primary intracranial tumors and childhood malignancies. However, increasing survival has been accompanied by the emergence of radiation-induced secondary neoplasms, which represent a rare but serious late complication. Their diagnosis is challenging because they may mimic recurrence of the original disease, while surgical treatment is complicated by radiation- related tissue changes. We report two cases illustrating the diagnostic and therapeutic challenges of radiation-induced intracranial tumors.

Methods: We retrospectively reviewed two patients who developed secondary intracranial tumors several years after receiving cranial radiotherapy for unrelated primary diseases. Clinical presentation, imaging characteristics, latency period, operative findings, histopathology, and postoperative outcomes were analyzed according to the accepted diagnostic criteria for radiation-induced tumors.

Results: Both patients presented more than a decade after cranial irradiation with newly developed intracranial masses located within the previous radiation field. Neuroimaging suggested de novo neoplastic lesions rather than recurrence of the initial pathology. Surgical resection was performed in both cases. Intraoperatively, extensive fibrosis, loss of normal tissue planes, and radiation-induced vascular changes increased the technical complexity of tumor removal. Histopathological examination confirmed radiation-induced neoplasms that were histologically distinct from the original tumors. Gross total resection was achieved in one patient and subtotal resection in the other because of adherence to critical neurovascular structures. Both patients recovered without major neurological deterioration and were referred for multidisciplinary postoperative management.

Conclusion: Radiation-induced tumors are becoming increasingly relevant as survival after cranial irradiation continues to improve. Neurosurgeons should maintain a high index of suspicion when evaluating new intracranial lesions arising years after radiotherapy. These cases highlight that successful management depends not only on recognizing this rare diagnosis but also on adapting surgical strategies to the unique challenges of the irradiated brain. Lifelong surveillance of irradiated patients is essential for early detection and timely intervention.

P297 - WHO grade II atypical meningiomas: clinicoradiological features and therapeutic management : a three-case report

Mohamed Znazen, A. Hachicha, H. Belmabrouk

Department of Neurosurgery, University Hospital of Gabès, Tunisia

Background: Atypical meningiomas (WHO Grade II) represent an intermediate category between benign and anaplastic meningiomas. Compared with Grade I tumors, they exhibit a higher risk of recurrence and a more aggressive biological behavior. Despite recent advances in histopathological classification, their optimal management remains controversial, particularly regarding the role of adjuvant radiotherapy following gross total resection. We report our experience with three patients diagnosed with atypical meningiomas and discuss the therapeutic strategy adopted in our institution.

Methods: We present three cases of atypical meningiomas treated in the Department of Neurosurgery at the University Hospital of Gabès. Clinical presentation, neuroimaging findings, surgical management, histopathological results, and postoperative outcomes were analyzed.

Results: The first patient was a 53-year-old man who presented with persistent headaches and a sensation of heaviness affecting the left side of the body. Brain magnetic resonance imaging (MRI) revealed a right frontotemporal convexity meningioma measuring 50 × 30 mm, associated with adjacent bone invasion. The patient underwent gross total tumor resection, including the involved dura and infiltrated bone, followed by delayed cranioplasty. The second case involved a 69-year-old woman admitted for a focal seizure without signs of intracranial hypertension or focal neurological deficit. Brain MRI demonstrated a right frontal convexity meningioma measuring 40 × 20 mm, surrounded by significant peritumoral edema. Complete surgical excision, including the dural attachment, was achieved. The third patient was a 51-year-old man who presented with a focal seizure with associated psychomotor agitation. Neurological examination was unremarkable. MRI revealed a right frontal convexity meningioma measuring 40 × 30 mm with marked peritumoral edema. Gross total resection of the tumor and its dural attachment was successfully performed, and the postoperative course was favorable. Postoperative recovery was favorable, with no complications in all cases.Histopathological examination confirmed WHO Grade II atypical meningioma and adjuvant radiotherapy was administered in each case.

Conclusion: Atypical meningiomas remain a therapeutic challenge because of their increased propensity for recurrence, even after complete surgical resection. Our experience highlights the importance of achieving maximal safe resection combined with meticulous histopathological assessment. Adjuvant radiotherapy may play a valuable role in improving local tumor control and reducing the risk of recurrence.

P298 - Young adult glioblastoma revealing familial neurofibromatosis type 1: a rare case report

Aziz Abdelmoula, K. Abderrahmen, A. Ouesleti, E. Mzoughi, F. Sliti, E. Ouni

Department of neurosurgery , National Institute of Neurology, Tunisia.

Background: Neurofibromatosis type 1 (NF1) is a common autosomal dominant tumor predisposition syndrome. Although low-grade gliomas are frequently encountered in NF1 patients, glioblastoma remains an uncommon manifestation, particularly in young adults.

Case presentation: A 23-year-old man presented with a one-month history of progressive headaches and left-sided weakness. Physical examination revealed multiple café-au-lait macules. Family history was notable for similar skin lesions in his father and brother. Neurological examination demonstrated left hemiplegia. Brain MRI revealed a large right frontal cystic lesion measuring 60 × 47 × 56 mm with irregular peripheral nodular enhancement and internal enhancing septations. Advanced MRI sequences demonstrated elevated choline levels, reversal of the choline/NAA ratio, and increased relative cerebral blood volume. Additional findings included a small enhancing lesion in the left centrum semiovale, enlargement of the right optic chiasm suggestive of optic pathway glioma, and multiple cervical, thoracic, and sacral foraminal lesions consistent with neurofibromas. Gross total resection was performed. Histopathological examination revealed a glioblastoma, WHO grade 4, IDH-wildtype, characterized by extensive necrosis, glomeruloid microvascular proliferation, ATRX loss, and a Ki-67 index of 25%.

Conclusion: This case illustrates a rare occurrence of glioblastoma in a young adult with previously undiagnosed familial NF1. The coexistence of multiple NF1-associated lesions, including probable optic pathway glioma and spinal neurofibromas, highlights the broad spectrum of central nervous system involvement in NF1 and emphasizes the importance of recognizing syndromic features in young patients presenting with high-grade gliomas.

P299 - Malignant Transformation of Neurocutaneous Melanosis in a Child: A Rare Case Report

O. JAMAL, A. JEHRI, A. LAIDI, K. GUETTABI, M. MAKHCHOUNE, K. IBAHIOUINE, S. HILMANI, A. LAKHDAR.

Department of Neurosurgery at the Ibn Rochd University Hospital Center in Casablanca

Laboratory for Diseases of the Nervous System, Sensory Nerves, and Disabilities

Introduction: Neurocutaneous melanosis (NCM) is a rare congenital neurocutaneous disorder characterized by the association of large or multiple congenital melanocytic nevi with melanocytic proliferation within the central nervous system. Malignant transformation into a primary CNS melanocytic neoplasm is an exceptional but life-threatening complication associated with rapid neurological deterioration and poor prognosis. We report a rare pediatric case of malignant transformation of NCM and discuss its diagnostic and therapeutic challenges.

Case Description: A six-year-old boy presented with severe headaches, recurrent vomiting, and progressive left hemiparesis. Physical examination revealed multiple congenital melanocytic nevi involving the trunk, back, buttocks, and thighs. Ophthalmological evaluation demonstrated rapidly progressive visual impairment associated with bilateral papilledema. Brain magnetic resonance imaging showed multiple intracerebral lesions displaying spontaneous T1 hyperintensity and T2 hypointensity, highly suggestive of melanocytic deposits. Obstructive hydrocephalus required ventriculoperitoneal shunt placement but was complicated by early shunt dysfunction and seizures. Follow-up MRI demonstrated rapid enlargement of the intracranial lesions, prompting surgical resection.

Results: Histopathological examination confirmed neurocutaneous melanosis with malignant transformation into a primary CNS melanocytic neoplasm. Despite neurosurgical management, the disease exhibited aggressive progression, consistent with the poor prognosis reported in the literature.

Conclusion: Malignant transformation of neurocutaneous melanosis is an exceptionally rare but devastating pediatric condition. Progressive neurological symptoms in children with congenital melanocytic nevi should raise suspicion for CNS involvement and possible malignant transformation. Early neuroimaging, prompt histopathological confirmation, and multidisciplinary management are essential to optimize diagnosis and therapeutic decision-making, although overall prognosis remains unfavorable.

Keywords: Neurocutaneous melanosis; Congenital melanocytic nevus; Primary CNS melanoma; Pediatric neurosurgery; Malignant transformation; Brain tumor; Magnetic resonance imaging.

P300 - Recurrent Intradural Cauda Equina Epidermoid Cyst Associated with a Congenital Dermal Sinus in a Child: A Rare Case Report

O. JAMAL, A. JEHRI, A. LAIDI, K. GUETTABI, M. MAKHCHOUNE, K. IBAHIOUINE, S. HILMANI, A. LAKHDAR.

Department of Neurosurgery at the Ibn Rochd University Hospital Center in Casablanca

Laboratory for Diseases of the Nervous System, Sensory Nerves, and Disabilities

Introduction: Spinal epidermoid cysts are rare benign tumors, accounting for less than 1% of all intraspinal neoplasms. They may be congenital, resulting from ectodermal inclusion during neural tube closure, or acquired after spinal procedures or trauma. Congenital dermal sinus is an uncommon form of occult spinal dysraphism that predisposes to epidermoid cyst formation and recurrence. Intradural localization within the cauda equina is exceptionally rare and presents significant diagnostic and surgical challenges.

Case Description: We report the case of a child with a history of lumbar surgery for an intradural epidermoid cyst who presented with recurrent low back pain, progressive lower-limb weakness, and a persistent cutaneous fistulous opening at the previous surgical site. Magnetic resonance imaging revealed a recurrent intradural cystic lesion involving the cauda equina, associated with a dermal sinus tract. The patient underwent repeat lumbar laminectomy with microsurgical excision of the epidermoid cyst and complete resection of the dermal sinus tract under microscopic magnification while preserving the neural elements. Histopathological examination confirmed the diagnosis of an epidermoid cyst.

Results: The postoperative course was uneventful, with marked improvement in neurological symptoms and successful healing of the cutaneous fistula. Postoperative magnetic resonance imaging demonstrated complete cyst removal without residual lesion. At follow-up, no clinical or radiological evidence of recurrence was observed.

Conclusion: Recurrent intradural epidermoid cysts of the cauda equina associated with congenital dermal sinus are exceptionally rare in children. Complete microsurgical excision of both the epidermoid cyst and the associated epithelial tract is essential to reduce the risk of recurrence while preserving neurological function. Early recognition of this entity and meticulous surgical planning are critical for achieving favorable long-term outcomes. Keywords: récidive, cauda equina, dermal sinus congénital, enfant, et rareté

P301 - Intramedullary Spinal Myelolipoma Mimicking a Glial Tumor: A Rare Diagnostic Challenge

A.JEHRI 1,2, O.JAMAL1,2 K.ELGHEUTTABI1 ,2, A.LAIDI 1,2,M.MAKHCHOUN1,2, K.IBAHIOIN1,2, S.HILMANI1,2, A.NAJA1,2, A.LAKHDAR1,2

1 Department of Neurosurgery at the Ibn Rochd University Hospital Center in Casablanca

2 Laboratory for Diseases of the Nervous System, Sensory Nerves, and Disabilities

Background: Spinal myelolipomas are rare benign lesions composed of mature adipose tissue admixed with hematopoietic elements. They are typically extradural and are most often described in paravertebral or posterior mediastinal locations. True intramedullary localization is exceptional. When the classical fat signal is absent on magnetic resonance imaging (MRI), these lesions may closely mimic primary intramedullary glial tumors and create a major diagnostic and therapeutic challenge.

Case Description: A 36-year-old man presented with a three-year history of progressive thoracic myelopathy, including spastic paraparesis, a sensory level, and autonomic dysfunction. Spinal MRI demonstrated a long-segment expansile intramedullary lesion extending from T2 to T6. The lesion was hypointense on T1-weighted imaging, hyperintense on T2/STIR sequences, and moderately enhanced after gadolinium injection, with a peripheral hemosiderin rim and no overt T1 hyperintensity suggestive of macroscopic fat. The radiological impression was a probable long-segment intramedullary astrocytoma. Because of the extensive longitudinal involvement and the absence of a clear resection plane, a biopsy-oriented surgical strategy was chosen. Histopathological examination demonstrated mature adipose tissue admixed with hematopoietic elements without atypia, confirming the diagnosis of myelolipoma. At nine -month follow-up, the patient remained neurologically stable without new deficits.

Conclusion: Intramedullary thoracic myelolipoma may convincingly mimic astrocytoma when characteristic fat-related imaging features are absent. This case emphasizes that imaging pattern recognition alone may be misleading in atypical intramedullary lesions. In selected cases with diagnostic uncertainty, a tissue-first strategy may prevent unnecessary aggressive resection and reduce avoidable neurological morbidity.

P302 - Primary Cerebellar Diffuse Large B-Cell Lymphoma Presenting with Obstructive Hydrocephalus: A Rare Posterior Fossa Tumor and Diagnostic Challenge

A.JEHRI 1,2, O.JAMAL1,2 K.ELGHEUTTABI1 ,2, A.LAIDI 1,2,M.MAKHCHOUN1,2, K.IBAHIOIN1,2, S.HILMANI1,2, A.NAJA1,2, A.LAKHDAR1,2

1 Department of Neurosurgery at the Ibn Rochd University Hospital Center in Casablanca

2 Laboratory for Diseases of the Nervous System, Sensory Nerves, and Disabilities

Background: Primary central nervous system lymphoma (PCNSL) is a rare extranodal non-Hodgkin lymphoma accounting for approximately 2–3% of all primary brain tumors. More than 90% of PCNSLs are diffuse large B-cell lymphomas (DLBCL). Although PCNSL predominantly arises in the cerebral hemispheres, isolated cerebellar involvement is uncommon, accounting for less than 10% of cases. Because of its rarity and nonspecific radiological features, cerebellar PCNSL may mimic high-grade glioma, metastasis, or other posterior fossa tumors, making preoperative diagnosis challenging.

Case Description: A 57-year-old man with a history of hypertension and type 2 diabetes mellitus presented with a one-month history of progressive headaches, recurrent vomiting, and deterioration of his general condition. Neurological examination revealed mild paraparesis and cerebellar syndrome. Brain magnetic resonance imaging demonstrated a right cerebellar vermian mass associated with mild-to-moderate obstructive triventricular hydrocephalus. The patient underwent staged surgical management consisting of external ventricular drainage followed by subtotal tumor resection. Intraoperatively, the lesion was grayish, infiltrative, and highly hemorrhagic. Histopathological examination revealed a diffuse proliferation of large atypical lymphoid cells with characteristic perivascular cuffing. Immunohistochemical analysis demonstrated positivity for CD20, MUM1, and BCL6, with negative CD10 expression, confirming the diagnosis of diffuse large B-cell lymphoma of the non-germinal center B-cell subtype, consistent with primary central nervous system lymphoma. Following surgery, the patient underwent four cycles of systemic chemotherapy. The treatment was well tolerated and resulted in a favorable clinical outcome, with marked neurological improvement and sustained clinical recovery during follow-up.

Conclusion: Primary cerebellar diffuse large B-cell lymphoma is a rare and diagnostically challenging presentation of primary central nervous system lymphoma because of its nonspecific clinical and radiological features. This case underscores the importance of timely cerebrospinal fluid diversion in patients with obstructive hydrocephalus, definitive histopathological diagnosis, and multidisciplinary management, including chemotherapy, to achieve favorable neurological outcomes.

Keywords: Primary central nervous system lymphoma; Diffuse large B-cell lymphoma; Cerebellar lymphoma; Posterior fossa tumor; Obstructive hydrocephalus; Case report.